



CASE REPORT

Rapid-Onset Obesity with Hypothalamic Dysfunction, Hypoventilation, and Autonomic Dysregulation (ROHHAD) Syndrome in an 8-Year-Old Girl with Ganglioneuroma and SARS-COV-2 infection: A Case Report and Literature Review

Ghamartaj Khanbabaei¹, Seyed Ahmad Tabatabaei¹, Nazanin Farahbakhsh¹, Seyedeh Zalfa Modarresi^{2*}, Matin Poorghasem², Ebrahim Tabiei², Abdolhamid Taghizadeh², Morteza Managheb³, Hosein Behzad Moghadam⁴, Kourosh Vahidshahi⁵, Seyed Morteza Tabatabaei Yazdi⁶, Hossein Taheri⁷

¹Pediatric Pulmonologist, Department of Pediatric Pulmonology, Mofid Children's Hospital, Shahid Beheshti University of Medical Sciences, Tehran, Iran
²Pediatric Pulmonology Fellowship, Department of Pediatric Pulmonology, Mofid Children's Hospital, Shahid Beheshti University of Medical Sciences, Tehran, Iran
³Anesthesiologist, Fellowship of cardiac Anesthesia, Erfan Niayesh Hospital, Tehran, Iran
⁴Pediatrician and Neonatologist, Neonatal and NICU ward, Erfan Niayesh hospital, Tehran, Iran
⁵Associate Professor of Pediatric Cardiology, School of Medicine, Modarres Teaching Hospital, Shahid Beheshti University of Medical Sciences, Tehran, Iran
⁶Pediatric Congenital Hematologic Disorders Research Center, Shahid Beheshti University of Medical Sciences, Tehran, Iran
⁷Student Research Committee, Shahid Beheshti University of Medical Sciences, Tehran, Iran

ARTICLE INFO

Article History:

Received: 01.10.2021
 Accepted: 22.11.2021

Keywords:

ROHHAD syndrome
 Rapid-onset obesity
 Hypoventilation
 Ganglioneuroma
 Covid 19

*Corresponding author:

Seyedeh Zalfa Modarresi,
 Mofid Children's Hospital, Shariati
 street, Tehran, Iran
 Tel: +98 9133517476
 Email: dr.modarres@gmail.com

Please cite this article as: Khanbabaei G, Tabatabaei SA, Farahbakhsh N, Modarresi SZ, Poorghasem M, Tabiei E, Taghizadeh AH, Managheb M, Behzad Moghadam H, Vahidshahi K, Tabatabaei Yazdi SM, Taheri H. Rapid-Onset Obesity with Hypothalamic Dysfunction, Hypoventilation, and Autonomic Dysregulation (ROHHAD) Syndrome in an 8-Year-Old Girl with Ganglioneuroma and SARS-COV-2 infection: A Case Report and Literature Review. IJBC 2021; 13(4): 144-147.

ABSTRACT

Background: ROHHAD syndrome (rapid-onset obesity, hypoventilation, hypothalamic dysfunction, and autonomic dysregulation) is an extremely rare disease in children. This article describes the clinical features, laboratory findings, imaging results, and treatment of a case of ROHHAD syndrome with ganglioneuroma.

Case Report: An 8-year-old girl in Covid-19 pandemic was admitted to our emergency department due to dyspnea, cyanosis, and respiratory distress. She had a history of close contact with his father (a case of covid 19) prior to hospital admission. Spiral chest CT scan of the patient revealed bilateral ground-glass opacities and also a right paravertebral mass. She had a history of rapid onset morbid obesity that had started 2 years ago. Furthermore, she had sleep disturbances and hypoventilation, electrolyte imbalance, polyuria and enuresis, irritability, and impulsivity. She was diagnosed as a case of ROHHAD syndrome based on her clinical manifestations. She was also diagnosed as a case of SARS-COV-2 infection. The paravertebral mass was resected which pathology was consistent with ganglioneuroma.

Conclusion: Because of the high prevalence of morbidity and mortality in ROHHAD syndrome and accompanying neural crest tumors, early diagnosis of this syndrome should be kept in mind. It is essential to pay attention to the cases with rapid onset obesity associated with hypoventilation to prevent severe complications.

Introduction

ROHHAD syndrome (rapid-onset obesity, hypothalamic dysregulation, hypoventilation, and autonomic dysregulation) is a rare and complex disease that presents

early in childhood, usually in previously normal children. The syndrome features progress over months to years.¹ The first case compatible with the ROHHAD syndrome was described in 1965 in a 3½-year-old boy.² According

to the literature, about 100 children worldwide affected by ROHHAD syndrome have been reported by 2021.³

The diagnosis of ROHHAD syndrome is based on clinical criteria so that the other disorders with overlapping features, including congenital central hypoventilation syndrome (CCHS) and Prader-Willi syndrome should be ruled out.¹ The diagnostic criteria for the ROHHAD syndrome are: 1) rapid onset and extreme weight gain after 18 months of age (usually after 2-7 years) in a previously healthy child; 2) hypoventilation; 3) evidence of hypothalamus dysfunction (at least one of the following: hyperprolactinemia, central hypothyroidism, water imbalance, failed growth hormone stimulation test, corticotrophin deficiency, or altered onset of puberty); and 4) features of autonomic dysregulation.⁴ Moreover, 40-56% of the cases may be accompanied with neural crest tumors such as ganglioneuroma and ganglioneuroblastoma;^{3,5} in that case the syndrome is titled as ROHHAD with neuroectodermal tumors (ROHHAD-NET) syndrome.⁶ The etiology of ROHHAD syndrome has not been determined yet.⁷ Management of the children with ROHHAD-NET syndrome is conservative and best is conducted by a multidisciplinary team.⁶

Herein, we describe a case of ROHHAD syndrome with ganglioneuroma from Iran, diagnosed two years after the onset of the obesity following a respiratory decompensation due to SARS-COV-2 infection.

Case Report

An 8-year-old girl in Covid 19 pandemic was referred to our hospital with fever, cough, dyspnea, and respiratory distress. Vital signs on arrival were as follows: heart rate of 85 beats/min, respiratory rate of 30 /min, blood pressure of 100/65 mmHg, and axillary temperature of 38.5°C. O₂ saturation was 55-60% in room air that reached 94% by rebreather mask. She had respiratory distress with tachypnea and intercostal retractions. On auscultation of the lungs, wheezing and rhonchi were heard. Her weight was 65 kg (>95th percentile) with a height of 123 cm (10th percentile), and her BMI was 42.96 Kg/m² (>95th percentile). A moon face, buffalo hump, and acanthosis nigricans in the posterior neck was remarkable in physical examination. She was in the pubertal stage of P1B3.

She was the first child of an unrelated, healthy young couple without a history of hospital admission. The patient had normal growth and development until the age of 6, when she developed rapid onset morbid obesity; she had gained 38 kg during the last two years. She was advised to have strict caloric intake and exercise with no response. Furthermore, she had experienced episodes of hyperactivity, impulsivity, sleep disturbance, nocturnal enuresis, and polyuria.

Laboratory results showed a mild normochromic normocytic anemia along with lymphopenia (Blood pH: 7.47, Pco₂: 88 mmHg, Po₂: 75 mmHg, Hco₃: 45 mEq/L (while receiving supplementary O₂) with elevated CRP of 4 mg/dL). Biochemistry tests were within normal range.

Spiral chest CT scan of the patient revealed bilateral ground-glass opacities (Figure 1). Furthermore, a round

mass measuring 50×40×30 mm in the right paravertebral area was observed. (Figure 2). Additionally, there were evidence of a moderate pulmonary hypertension and a mild systolic LV dysfunction in echocardiography. Meanwhile, pulmonary angiography was performed which showed a pulmonary arterial pressure of 36 mmHg, that appropriate treatment was started for the patient.

Considering the patient's symptoms, lymphopenia, hypoxia, and close contact with her father who had positive PCR test for SARS-COVID-19, she was admitted to pediatric ICU with the diagnosis of Covid-19 disease. She was treated according to our national guidelines.⁸ As she was still hypoxic and hypercapnic, noninvasive ventilation was started. Blood gas was within the normal range in 48 hours.

Seven days later, she underwent thoracotomy for the paravertebral mass that the pathology was in favor of a mature ganglioneuroma.

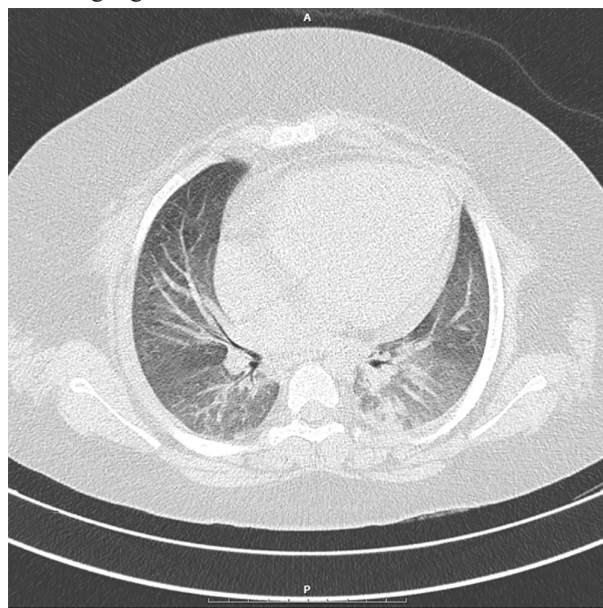

Figure 1: Bilateral subpleural ground-glass opacities and consolidation in left lower lobe in an 8-year-old girl with ROHHAD syndrome, suspected to be complicated by SARS-COVID-2 infection.

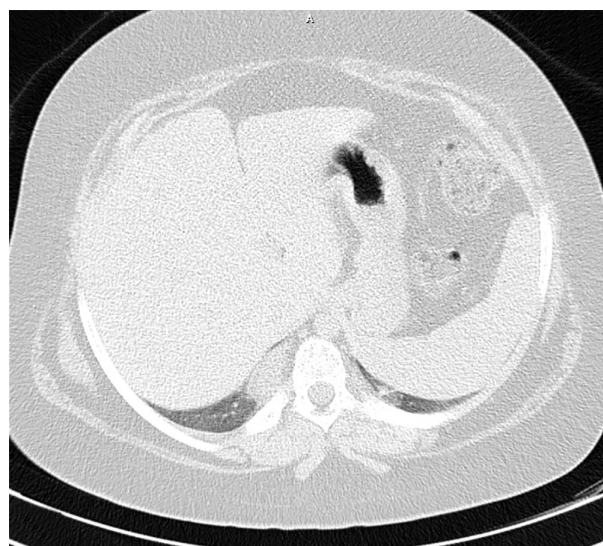


Figure 2: A right paravertebral mass measuring 40x30x15 mm at level of T9-T11 in an 8-year-old girl with rapid onset obesity

Due to the history of hypoventilation and the history of significant weight gain, a preliminary diagnosis of ROHHAD syndrome was made which was precipitated with a respiratory infection (Figure 3). Genetic testing for evaluation of mutations in PHOX2B (the disease-defining gene for congenital central hypoventilation syndrome) came up negative.

Laboratory tests including serum adrenocorticotrophic hormone, cortisol, thyroid hormones, thyroid-stimulating hormone, and insulin were all analyzed in the patient.

The child was discharged two weeks later with noninvasive ventilation. On follow-up, the patient's condition remained stable for six months. She needed BiPAP machine for about 20 hours a day. The level of SpO₂ and Paco₂ during the day and night remained within the normal range.

Discussion

The present case was an 8-year-old girl that according to the history of rapid onset morbid obesity, hypoxia and hypoventilation and electrolyte imbalance was diagnosed with ROHHAD syndrome. The neuroectodermal tumor (ganglioneuroma) of the posterior mediastinum was in favor of ROHHADNET syndrome in the patient.

ROHHAD syndrome is an extremely rare disorder worldwide; 100 cases of which have been reported so far.³

Table 1 summarizes the characteristics of the Iranian cases reported with ROHHAD syndrome.

Hypoxemia has been estimated to be the most common presentation at the time of diagnosis of the syndrome.¹¹ However, respiratory distress in our patient was triggered by a viral infection (COVID-19). The alveolar hypoventilation observed in about half of the patients with ROHHAD syndrome should be managed with ventilator support.¹¹ Indeed, appropriate management with noninvasive ventilation may improve the quality of life and prevent complications.¹ Interestingly, all the cases reported from Iran needed ventilator support. It needs to be emphasized that early diagnosis and management of the disease would be associated with a better outcome.

ROHHAD syndrome is more than twice as prevalent in females.¹¹ Moreover, there was a female predominance in the cases with ROHHAD-NET syndrome reported from Iran.

The most common type of neuroendocrine tumors seen in ROHHADNET syndrome are ganglioneuroma/ganglioneuroblastoma.¹¹ Our patient had a posterior mediastinal ganglioneuroma confirmed by histopathology. Two of the 4 cases reported from Iran also displayed the neuroendocrine tumor on imaging studies. This is

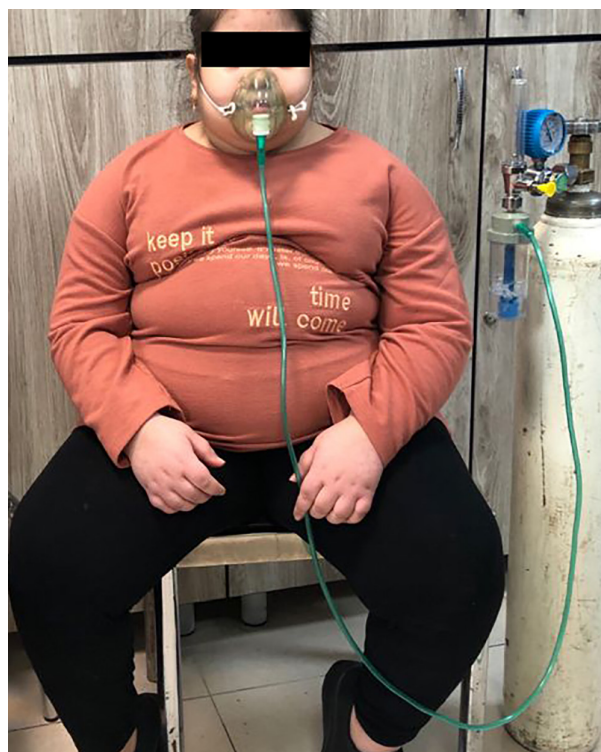

Figure 3: 8-years-old girl, diagnosed with ROHHAD syndrome

in accordance with the other studies showing about 50% association of ROHHAD syndrome with neuroendocrine tumors.¹ In those two cases with NETs, the syndrome was diagnosed 1-2 years after the onset of the disease.^{9,10}

Interestingly, in the majority of the cases of ROHHADNET syndrome, the tumor was discovered after about 2 years of the onset of the obesity.¹ It is explained that may be in follow-up visits the NET tumors are discovered. Hence, an annual imaging study of patients with ROHHAD syndrome is highly suggested.

Pulmonary hypertension; an extremely rare complication of ROHHAD syndrome,¹¹ was detected in our patient. There are few reports of pulmonary hypertension in ROHHAD syndrome in children.^{10,12,13}

Hypercarbia and hypoxemia which lead to progressive inadequate ventilation in these cases, may be responsible for the poor prognosis of ROHHAD syndrome.⁶ It seems that long-term outcome and prognosis of the patients with ROHHAD syndrome is undetermined, specifically that there is not any report of ROHHAD syndrome reaching adulthood.⁷

Conclusion

ROHHAD syndrome is a rare disorder with autonomic

Table 1: characteristics of the Iranian cases reported with ROHHAD syndrome

Gender	Index case	Case 1 ⁹	Case 2 ¹⁰	Case 3 ¹⁰
	Female	Female	Female	Male
Age at onset of the obesity (years)	6	4	3	2
Age at diagnosis (years)	8	5	10	8
Neuroectodermal tumors	+	+	-	-
Pulmonary hypertension	+	-	-	+
Treatment	BiPAP	Mechanical ventilation	Mechanical ventilation BiPAP	Mechanical ventilation BiPAP

dysfunction associated with significant morbidity and mortality. NETs may accompany 40-56% of the ROHHAD syndrome cases. It is essential for pediatricians to pay more attention to children with rapid onset obesity and hypoventilation episodes in order to early diagnosis of this rare entity. Systematic follow-up and multidisciplinary management with the aim of improving prognosis and life expectancy is seriously advised in cases with ROHHAD-NET syndrome, since early management would ameliorate the complications.

Conflict of Interest: None declared.

References

1. Harvengt J, Gernay C, Mastouri M, Farhat N, Lebrethon MC, Seghaye MC, et al. ROHHAD(NET) Syndrome: Systematic Review of the Clinical Timeline and Recommendations for Diagnosis and Prognosis. *J Clin Endocrinol Metab.* 2020;105(7).doi: 10.1210/clinem/dgaa247. PubMed PMID: 32407531.
2. Fishman LS, Samson JH, Sperling DR. Primary Alveolar Hypoventilation Syndrome (Ondine's Curse). *Am J Dis Child.* 1965;110:155-61.doi: 10.1001/archpedi.1965.02090030165011. PubMed PMID: 14320765.
3. Lazea C, Sur L, Florea M. ROHHAD (Rapid-onset Obesity with Hypoventilation, Hypothalamic Dysfunction, Autonomic Dysregulation) Syndrome-What Every Pediatrician Should Know About the Etiopathogenesis, Diagnosis and Treatment: A Review. *Int J Gen Med.* 2021;14:319-26.doi: 10.2147/IJGM.S293377. PubMed PMID: 33542648. PubMed Central PMCID: PMC7853626.
4. Ize-Ludlow D, Gray JA, Sperling MA, Berry-Kravis EM, Milunsky JM, Farooqi IS, et al. Rapid-onset obesity with hypothalamic dysfunction, hypoventilation, and autonomic dysregulation presenting in childhood. *Pediatrics.* 2007;120(1):e179-88.doi: 10.1542/peds.2006-3324. PubMed PMID: 17606542.
5. Bougneres P, Pantalone L, Linglart A, Rothenbuhler A, Le Stunff C. Endocrine manifestations of the rapid-onset obesity with hypoventilation, hypothalamic, autonomic dysregulation, and neural tumor syndrome in childhood. *J Clin Endocrinol Metab.* 2008;93(10):3971-80.doi: 10.1210/jc.2008-0238. PubMed PMID: 18628522.
6. Ibanez-Mico S, Marcos Oltra AM, de Murcia Lemauviel S, Ruiz Pruneda R, Martinez Ferrandez C, Domingo Jimenez R. Rapid-onset obesity with hypothalamic dysregulation, hypoventilation, and autonomic dysregulation (ROHHAD syndrome): A case report and literature review. *Neurologia.* 2017;32(9):616-22.doi: 10.1016/j.nrl.2016.04.008. PubMed PMID: 27340018.
7. Patwari PP, Wolfe LF. Rapid-onset obesity with hypothalamic dysfunction, hypoventilation, and autonomic dysregulation: review and update. *Curr Opin Pediatr.* 2014;26(4):487-92.doi: 10.1097/MOP.0000000000000118. PubMed PMID: 24914877.
8. Karimi A, Rafiei Tabatabaei S, Rajabnejad M, Pourmoghaddas Z, Rahimi H, Armin S, et al. An algorithmic approach to diagnosis and treatment of coronavirus disease 2019 (COVID-19) in children: Iranian expert's consensus statement. *Archives of Pediatric Infectious Diseases.* 2020;8(2).
9. Bagheri B, Pourbakhtyaran E, Talebi Kiasari F, Taherkhanchi B, Salarian S, Sadeghi A. Rapid-onset obesity with hypothalamic dysfunction, hypoventilation, and autonomic dysregulation (ROHHAD) syndrome: A case report. *Archives of Pediatric Infectious Diseases.* 2017;5(1).
10. Adimi Naghan P, Gheraati M, Ghaffaripour HA, Vasheghani M, Mirenayat MS. Three Cases of Hypoventilation in the First Decade with an Unusual Presentation and Rare Etiology: A Case Report. *Journal of Comprehensive Pediatrics.* 2019;10(3).
11. Lee JM, Shin J, Kim S, Gee HY, Lee JS, Cha DH, et al. Rapid-Onset Obesity with Hypoventilation, Hypothalamic, Autonomic Dysregulation, and Neuroendocrine Tumors (ROHHADNET) Syndrome: A Systematic Review. *Biomed Res Int.* 2018;2018:1250721. doi: 10.1155/2018/1250721. PubMed PMID: 30584530. PubMed Central PMCID: PMC6280256.
12. Stowe RC, Afolabi-Brown O. Pulmonary hypertension and chronic hypoventilation in ROHHAD syndrome treated with average-volume assured pressure support. *Pediatr Investig.* 2019;3(4):253-6.doi: 10.1002/ped4.12168. PubMed PMID: 32851331. PubMed Central PMCID: PMC7331430.
13. Siraz UG, Okdemir D, Direk G, Akin L, Hatipoglu N, Kendirci M, et al. ROHHAD Syndrome, a Rare Cause of Hypothalamic Obesity: Report of Two Cases. *J Clin Res Pediatr Endocrinol.* 2018;10(4):382-6.doi: 10.4274/jcrpe.0027. PubMed PMID: 29553042. PubMed Central PMCID: PMC6280328.