

# Intra articular Injection of Rifampin in Iranian Children with Haemophilic Arthropathy

Peyman Eshghi,<sup>1</sup> Kourosh Goudarzipour,<sup>1</sup> F. Hoorieh Davoudabadi,<sup>2</sup> Roxana Aghakhani.<sup>3</sup>

1. Department of Pediatric Hematology/Oncology, Shahid Beheshti University of Medical Sciences.

2. Central Hospital of National Iranian Oil Company.

3. Department of Pathology, Shahid Beheshti University of Medical Sciences.

**Corresponding Author:** Peyman Eshghi, Department of Pediatric Hematology/Oncology, Shahid Beheshti University of Medical Sciences,

(Tel/Fax: +982122904536, Email: peyman64@yahoo.com)

---

## Abstract

**background:**Chronic synovitis is one of the most important complications in haemophilic patients. Rifampin is an antibiotic which its intra-articular injection leads to destruction of the synovial membrane of haemophilic patients medically.

**Materials and Methods:** Between September 2003 and November 2005, we administered intra-articular rifampin in 16 haemophilic joints of 8 haemophilic patients.

**Results:**Median age of our patients was 14.5 year-old. There were 11 knee joints and 5 elbow joints. After treatment we observed significant improvement in treated joints.

**Conclusion:**This study reveals that intra-articular injection of rifampin may improve arthropathy in haemophilic patients.

**Keywords:**Hemophilia, Synovitis, Rifampin.

---

## Introduction

Intra-articular bleeding is the most common manifestation of haemophilia A and B.<sup>1</sup> The most common involved joints are typically the knee, ankle, elbow, hip, and shoulder. Infusion of factor VIII or factor IX concentrate as prophylaxis or on-demand programs are standard methods to treat haemophilia but sometimes these conservative treatments fail to control recurrent hemarthroses.<sup>2</sup>

Target joint is a joint that has bled more than 3 times in last 6 months. In a proportion of patients, recurrent hemarthroses produce hypertrophic synovitis and, in long term, progressive cartilage degradation leading to irreversible arthropathy.<sup>3</sup> During the phase of chronic synovitis (stage I/II or even stage III of haemophilic arthropathy according to the classification by Fernandez-Palazzi<sup>4</sup>), medical synovectomy (synoviorthesis) could decrease bleeding frequency because of reversibility of the

process at that stage.<sup>5</sup> Medical synovectomy, is defined as a kind of treatment in which intra-articular injection of a chemical agent leads to destruction of the serous membranes such as synovium. Basically there are two types of synoviorthesis; chemical utilizing different substances such as antibiotics, gold, osmic acid, etc, and radioactive utilizing isotopes.<sup>6-8</sup> Several authors have used rifampicin for medical synovectomy in haemophilic arthropathy.<sup>9-10</sup> These antibiotics have demonstrated proteolytic and anti-fibrinolytic actions producing fibrosis and sclerosis of the synovium when injected into the joints. Here, we describe our experience on synoviorthesis using rifampin in a group of patients treated at Ali Asghar hemophilia treatment center in Zahedan, south east of Iran.

## Material and Methods

Between September 2003 and November 2005,

we selected 16 joints of 8 patients with haemophilia A or B for intra-articular injection of rifampin. The indications for synoviorthesis were transient or chronic synovitis with or without axial deformity or muscle atrophy- stage I/II or III of haemophilic arthropathy according to the classification by Fernandez-Palazzi<sup>4</sup>- characterized by recurrent spontaneous hemarthroses more than 3 times in 6 months and no response to secondary prophylaxis with coagulation factors, along with persistent pain, and limited range of motion (ROM).<sup>4-6</sup> In secondary prophylaxis for target joints, they received 20-30 units/kg of factor VIII every other day and factor IX two times per week for three months. To prepare patients for synoverthesis, we infused factor VIII or factor IX to gain 30-40 percent plasma level concentration activity and continued infusion for 24 hours after injection of rifampin. In one pa-

tient with high titer of inhibitor, bypassing agent was injected before and continued for 24 hours after injection, and then it was administered only on-demand in the case of joint bleeding. Rifampin was diluted in lidocaine 2% to achieve a 60 mg/ml concentration, and intra-articular injection with maximum dose of 600 mg in the knee and 300 mg in elbow was performed by an orthopedic surgeon. The procedure was performed once weekly for 4-5 times for knees, 3-4 times for elbows, and 2-3 times for ankles. We did not use general anesthesia for patients. Patients were discharged after 6 hours.

The joints of haemophilic patients were evaluated considering 8 features: swelling, muscle atrophy, joint deformity, ROM, crepitus, flexion contracture, instability, and pain before and after treatment. Each joint was assessed according to a scoring system shown in table 1.

Type of change	swelling			Muscle atrophy		Axial deformity knee			Axial deformity ankle			Crepitus on motion		Lack of Range of motion			Flexion contracture		Instability			Pain respond to drug			
	N	P11	S	N or <1cm	P1	NI	MI	Mt	N	Mla	Mta	N	P1	10%	10-33%	>33%	<15°	>15°	N	NM	WM	ND	NO	OO	DO
SCORE	0	1	2	0	1	0	1	2	0	1	2	0	1	0	1	2	0	1	0	1	2	0	1	2	3

Table 1. Guidelines for physical examination scores by Gilbert.

**N:** None, **P1:** Present, **P11:** Present, **NI:** Normal :0-7 valgus, **MI:** Mild: 8-15 valgus or 0-5 varus, **Mt:** Moderate: >5varus, **Mla:** <10 valgus or <5 varus in ankle, **Mta:** > 10 valgus or >5 varus in ankle, **NM:** No morbidity, **WM:** With morbidity, **S:** Added score if chronic synovitis is present, **ND:** Without drug, **NO:** Non-opioid, **OO:** Often opioid, **DO:** Daily opioid

## Results

All of the patients were male and median age was 14.5 years old; 7 cases were haemophilia A and one case was haemophilia B. One patient with haemophilia A had inhibitor (BU: 10.7). Eleven knee and 5 elbow joints were studied. There were crepitus, swelling, and pain subsided with non-opioid analgesic in all joints. Eight knee joints and one elbow joint had muscle atrophy more than 1 cm. Limitation of ROM was seen in 3 knee joints. One elbow joint had flexion contracture more than 15°. No joint deformity and instability were seen in the patients. Table 2 shows joints features before treatment.

We observed the following results in joints after intra-articular administration of rifampin. Decrease of swelling was seen in all joints. Muscle atrophy was improved in all atrophic muscles. Improvement of ROM was seen in 6 joints, and no change in 3 joints. These 3 joints included 2 knees and one elbow in a patient with haemophilia A without inhibitor. Crepitus and pain were relieved in all joints. Improvement of flexion contracture was seen in three joints, and no change in one elbow joint. Table 3 shows joints features after treatment. Figure 1 shows joints characteristics before and after treatment in comparison.

Joint	No.	Swelling	Knee deformity	Limitation of ROM	Crepitus	Flexion contracture	Muscle atrophy	Instability	Pain
Knee	11	11	-	8	11	3	8	-	11
Elbow	5	5	-	1	5	1	1	-	5
Total	16	16	-	9	16	4	9	-	16

Table 2. Joints Features before treatment.

Joint	No.	Decrease of swelling	Knee deformity	Improvement of ROM	Improvement of crepitus	Improvement of flexion contracture	Improvement of muscle atrophy	Instability	Relief of pain
Knee	11	11	-	6	11	3	8	-	11
Elbow	5	5	-	1	5	-	1	-	5
total	16	16	-	7	16	3	9	-	16

Table 3. Joints features after treatment.

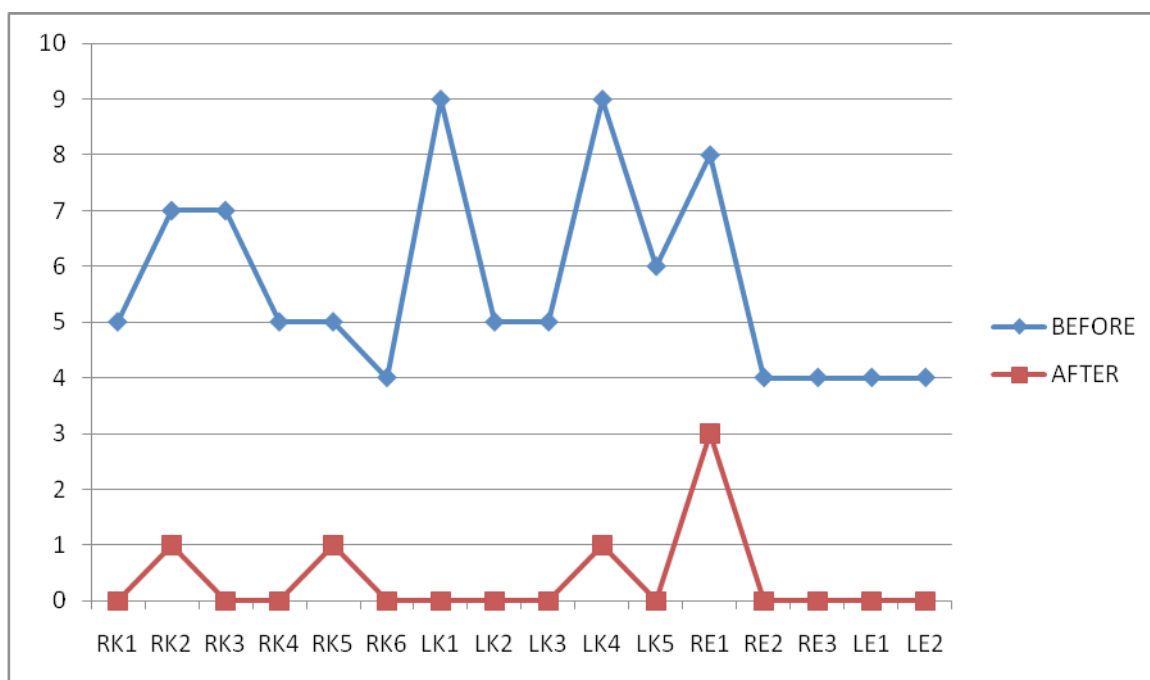


Figure 1. Joint scores before and after the synovectomy. (RK:Right Knee, LK: Left Knee, RE: Right Elbow, LE: Left Elbow)

### Discussion

Synoviorthesis is the intra-articular injection of substances producing fibrosis of the synovium.<sup>5</sup> Basically there are two types of synoviorthesis: chemical utilizing different substances such as antibiotics, gold, osmotic acid, etc,<sup>6</sup> and radioactive utilizing isotopes.<sup>7,8</sup> Synoviorthesis using intra-articular <sup>90</sup>Yttrium or <sup>32</sup>Phosphorus (radiosynovectomy) has been reported to be effective; however, it is an expensive procedure with unestablished long-term

safety.<sup>6,14</sup>

Haemophilic arthritis is caused by recurrent haemarthroses. Intra-articular bleeding produces synovial hypertrophy, hemosiderin deposition, hypervascularity, and an inflammatory response (i.e. synovitis) which allows for further bleeding. The end result can be replacement of the synovium by fibrous tissue and destruction of cartilage by the inflamed synovium. Synovial hypertrophy, pannus formation, and elevated intra-articular levels of

acid phosphatase and cathepsin D simulate what is observed in rheumatoid arthritis. In order to prevent from progression to chronic joint disease in haemophilia, synovitis must be controlled or eliminated. Early treatment of an acute haemarthrosis has been found to be effective in reducing the prevalence of synovitis, nevertheless about 20% of the patients have chronic synovitis in spite of early replacement therapy.<sup>3,11,17</sup> Corticosteroids could reduce synovitis in the majority of patients, but the effect is temporary and complete remission is rare with corticosteroids.<sup>12-13</sup> Synovectomy lessens bleeding in the affected joint, but it is an invasive procedure and most patients will have variable degrees of joint function limitation as a result of the surgery.<sup>15,16</sup>

It is commonly accepted today that synoviorthesis is the procedure of choice, and that surgical synovectomy should be performed only if a number of consecutive synoviorthesis procedures fail to stop or diminish the frequency of recurrent haemarthrosis. Thus, the main indication for a synoviorthesis in a haemophilic joint is hypertrophic synovitis and recurrent bleeding.<sup>4,5</sup> There are two basic types of synoviorthesis: chemical and radioactive. The materials most commonly used for chemical synovectomy are osmotic acid and rifampin. The radioisotopes currently used for radiation synovectomy are <sup>90</sup>Yttrium and <sup>32</sup>Phosphorus. Radiation Synovectomy seems to be the method of choice because it appears to be more effective than chemical synovectomy, it needs only one injection and causes less pain in patients. However, taking into account the concern that radioactive materials evoke, and the high cost and limited supply of these materials, it would be better to schedule groups of six to eight patients to perform radiation synovectomy. This will require some patients to wait for 3-6 months until the whole group is scheduled for the procedure. If possible, patients should be maintained on continuous prophylaxis while waiting for the procedure.<sup>5</sup> On the other hand, long-term safety –especially in children- has not been established.<sup>4,14</sup>

In 1980, Caruso used intra-articular rifampin in rheumatoid arthritis.<sup>18</sup> This antibiotic has demonstrated proteolytic and antifibrinolytic actions, producing fibrosis and sclerosis of the synovium when injected into the joints.<sup>19,20</sup> In 1992, Lofqvist and Petersson published the results of synoviorthesis in young patients with haemophilia and inhibitory

antibodies. There were 5 patients under 15 and 13 joints were treated. Bleeding free interval of more than 6 months was seen in nine patients, of whom six remained free from bleeding for more than 1 year.<sup>21</sup> Radossi used intra-articular rifampin in 28 patients (25 with haemophilia A, and three with haemophilia B). Thirty seven joints were treated with a total 169 injections including 6 joints in patients with inhibitor. Injections were considered effective in 24 patients (80%) and insufficient in six (20%). Pain reduced in 96% of cases, and ROM was improved in 70%.<sup>1</sup> In 1998, Fernandez-Palazzi treated 39 joints of haemophilic patients with intra-articular rifampin. There were 20 excellent responses, 17 good responses, 1 fair, and 1 poor response.<sup>4</sup> In the XXIV international congress of world federation of haemophilia, the clinical experience in patients with grade II or III was presented. The patient population consisted of 108 patients with 126 affected joints (77 knee, 29 elbow, and 20 ankle joints). All of them were male patients, whose average age was 14 years (range: 6-42). The average follow up duration was 5 years. Recurrence happened in 1 ankle joint, 4 elbow, and 15 knee joints. Rifampin was advised for use in smaller joints (elbow and ankle), and all joints in small children to avoid the potential damage of the adjacent growth plates.<sup>21</sup> It is also advised for patients in developing countries because of less cost and more availability, along with the same efficacy compared to radioactive methods.<sup>22</sup>

Our clinical study showed that chemical synoviorthesis with rifampin could lead to significant improvement in the clinical score of target joints in 100% of the cases. It did not cause any complications; none of the patients interrupted the treatment course. The therapeutic material was available. The best results were obtained in children with haemophilia –even with inhibitors- with grade I-III of chronic synovitis.

## Conclusion

Chemical synoviorthesis with rifampin is an effective, safe, inexpensive, and simple procedure in treatment of synovitis, recurrent hemarthrosis, and chronic synovitis before development of severe arthropathy (grade IV) in haemophilia, and should be considered in all regions especially for children without any important cautions.

## References

1. Radossi P, Baggio R, Petris U, De Biasi E, Risato R, Davoli PG, et al. Intra-articular Rifamycin in haemophilic arthropathy. *Haemophilia* 2003; 9: 60-63.
2. Rodriguez-Merchan E. Methods to treat chronic haemophilic synovitis. *Haemophilia*. 2001; 7: 1-5.
3. Rodriguez-Merchan EC, Goddard NJ. Chronic haemophilic Synovitis. In: Rodriguez-Merchan EC, Goddard NJ, Lee CA, editors. *Musculoskeletal aspects of haemophilia*. Oxford: Blackwell Science Ltd; 2000. p. 43-9.
4. Fernandez-Palazzi F. Treatment of acute and chronic synovitis by non-surgical means. *Haemophilia*. 1998; 4: 518-23.
5. Rodriguez-Merchan EC, Wiedel JD. General principles and indications of synoviorthesis (medical synovectomy) in haemophilia. *Haemophilia*. 2001; 7(suppl.2): 6-10.
6. Rivard GE. Chemical synovectomy in haemophilia: status and challenges. *Haemophilia*. 2001; 7(suppl.2): 16-9.
7. Petersson CJ. Synoviorthesis with radioactive gold in haemophilia. *Haemophilia*. 2001; 7(suppl.2): 31-3.
8. Silva M, Luck JV Jr, Siegel ME. <sup>32</sup>P chronic phosphate radiosynovectomy for chronic haemophilic Synovitis. *Haemophilia*. 2001; 7(suppl.2): 40-9.
9. Barrionuevo A, Galatro G, Lorenz M, Perez Bianco R, Caviglia H. Rifamycin action in synovitis caused by experimental hemarthrosis. *Haemophilia*. 1996; 2: 39.
10. Caviglia H, Fernandez-Palazzi F, Maffei E, Galatro G, Barrionuevo A. Chemical synoviorthesis for haemophilic synovitis. *Clin Orthop*. 1997; 343: 30-6.
11. Hilgartner MW, Pochedly C. *Hemophilia in the Child and Adult*. 3rd ed. New York: Raven Press; 1989.
12. Thomas P, Hepburn B, Kim HC, Saidi P. Non-steroidal anti-inflammatory drugs in the treatment of hemophilic arthropathy. *Am J Hemat*. 1982; 12: 131-7.
13. Steven MM, Small M, Pinkerton L, Madhok R, Sturrock RD, Forbes CD. Non-steroidal anti-inflammatory drugs in haemophilic arthritis. *Haemostasis*. 1985; 15: 204-9.
14. Rivard GE, Girard M, Belanger R, Jutras M, Guay JP, Marton D. Synoviorthesis with colloidal <sup>32</sup>P chromic phosphate for treatment of hemophilic arthropathy. *J Bone Joint Surg*. 1994; 76: 482-8.
15. Nicol RD, Menelaus MB. Synovectomy of the knee in hemophilia. *J Pediatr Orthoped*. 1986; 6: 330-3.
16. Luck JV, Kasper CK. Surgical management of advanced hemophilic arthropathy. *Clin Orthoped*. 1989; 242: 60-82.
17. Eikhoff HH, Raderschadt G, Koch W, Brackmann HH. Control of synovium in haemophilia. *Haemophilia*. 1998; 4: 511-3.
18. Caruso I, Montrone F, Fumagalli, Patrono C, Santandrea S, Gandini MC. Rheumatoid knee synovitis successfully treated with intra-articular rifamycin SV. *Ann Rheum Dis*. 1982; 6: 232-6.
19. Barrionuevo A, Galatro G, Lorenz M. Rifamycin action in synovitis caused by experimental hemarthrosis. *Haemophilia*. 1996; 2: 39.
20. Caviglia H, Fernandez-Palazzi F, Maffei E, Galatro G, Barrionuevo A. Chemical synoviorthesis for haemophilic Synovitis. *Clin Orthop*. 1997; 343: 30-6.
21. Caviglia H, Galatro G, Morreti N. Intra-articular rifampicin therapy of chronic hemophilic Synovitis. 3<sup>rd</sup> Musculoskeletal Congress of the World Federation of Haemophilia. Herzliya; 1995.
22. Caviglia H, Fernandez-Palazzi F, Galatro G, Perez-Bianco R. Chemical synoviorthesis with rifampicin in haemophilia. *Haemophilia*. 2001; 7(suppl.2): 26-30.