IJBC 2012;2: 99-100

# Very late recurrence of gastric cancer with bone marrow involvement and microangiopathic hemolytic anemia as a stem cell disease: a lesson for future

Noorani khojasteh H
Associate professor, Shiraz University of Medical Sciences, Dept of Internal Medicine, Nemazi Hospital, Shiraz –Iran

*Submit: 30-03-2011, Accept: 20-09-2011*

## Introduction:

Gastric adenocarcinoma, is a known aggressive malignancy with local behavior showing systemic relapse in the abdomen and other organs , with bone marrow metastasis being present in only 1 to 11% of cases. The average time of relapse is 3.5 years. [1]

Here, we describe, an interesting case with thrombotic microangiopathic hemolytic anemia, which is a known gastric cancer complication.[4] The mechanisms of this anemia are tumor related effect on endothelial cells.

In this case repot, a very late relapse, is discussed to observe this cancer as a systemic disease even in the early stage of presentation, like breast cancer, and also consider this disease as a new model for the presentation of stem cell theory of cancer progression.

## Report of the case:

The patient, a 60 year old male, operated ten years ago as a case of early stage gastric cancer, presented with pallor, jaundice, fatigue and tarry stool from few days prior to admission. The laboratory data were in favor of acute thrombotic microangiopathic hemolytic anemia, and the bone marrow and imaging studies were in favor of activity of gastric cancer (Figures 1-3).

**Lab data**

| | |
|---|---|
| White blood cells | 31000/ micro litter |
| Hemoglobin | 6gm/dl |
| Platelet | 42000/micro litter |
| Reticulocyte | 12% |
| Blood Urea | 56mg/dl |
| Creatinine | 1mg/dl |
| Direct Bilirubin | 1.8mg/dl |
| Total Blirubin | 5.1mg/dl |
| Direct Coombs | Negative |
| Total Serum Protein | 6.2gm/dl |
| Albumin | 3.6gm/dl |
| AST | 148U/L |
| ALT | 41U/L |
| Alkaline Phosphatase | 1449u/l |
| Prothrombin Time | 15 second |
| Partial Thromboplastin Time | 56 second |
| LDH | 5000u/l |
| Fasting blood sugar | 182mg/dl |

Computerized tomography of abdomen: pleuroperitoneal effusion

**Fig 1.** : fragmented and nucleated red cells, evidence of thrombotic microangiopathy.

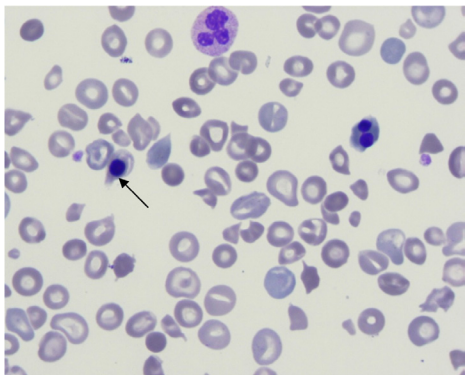

**Fig 2.** Clusters of tumor cells in the bone marrow of the patient, ten years after primary disease.

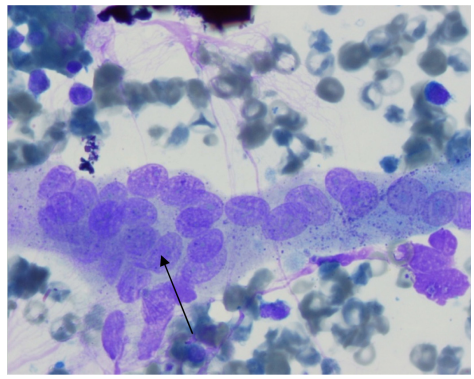

[ Downloaded from ijbc.ir on 2024-10-12 ]

**Fig 3.** : clusters of malignant cells in the bone marrow biopsy

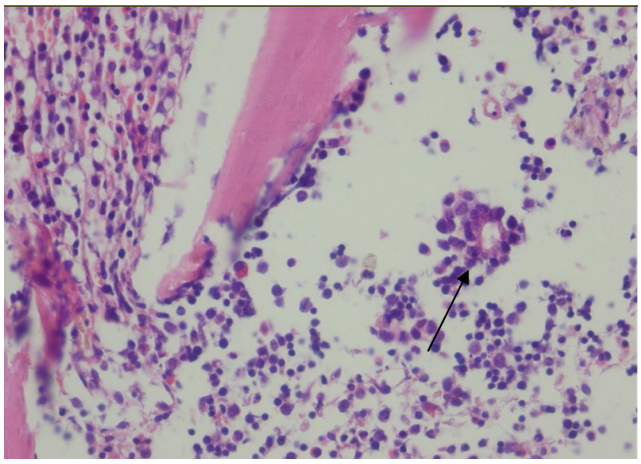

## Discussion

From three decades ago it has been determined that 1% of leukemia cells might grow into colonies in vitro with ability to make new tumor cells and the hypothesis of cancer stem cells theory arises from this observation.

Houghton et al. have recently reported that similar stem cells may give rise to gastric cells originating from hematopoietic tissue.

Attached to the stem cell theory and gastric cancer is the infection with helicobacter pylori with near eighty percent of gastric cancer patients having a history of infection with this organism.

The association between the helicobacter pylori and gastric cancer is well- known.[5] The stem cell theory denotes that H. pylori induced inflammation in the gastric mucosa causes migration of the hematopoietic stem cells to the injured area to help the repair, and in this new environment sometimes these cells undergo genetic damage and acquire malignant behavior.[6] After the surgical and medical treatment of the primary tumor some dormant cancer cells remain viable and later proliferate and form a clinical relapse. [7]

Tumor late recurrence is not usual in solid tumors, except in breast cancer, and usually happens after 5 years of remission, but such a recurrence after 10 years reminds us, the theory of viability of tumor dormancy with a mechanism of cancer stem cell. This aspect is important in future for the therapeutic strategy utilized for this cancer.

## References:


1. H.T Arkenaue,O mussig,T Buhr,Internet Journal of Gastroenterology ,V 3,Number 2,2005,
2. Houghton JC,Nomura S Regers AB et al Gastric cancer originating from bone marrow derived cells,Science 2004,306,1568-7
3. Cancer,principle and practice of oncology,Vincent Devita 7th edition,2005
4. Tsuqoshi E,Hideo B,Akinoal,diffuse bone metastasis with hematologic disease from gastric cancer,clinicopathologic feature and prognosis,1999,6:601-5
5. Schiller D,Malignancy associated microangiopathic hemolytic anemia, journal of clinical oncology,2474-2475,1997
6. Marx J,Bone marrow cells, the source of gastric cancer science 2004,306,1455
7. Peer RM,Blaser MJ 2002,Helicobacter pylori and gastrointestinal adenocarcinoma,Nar Rev Cancer 2002,2,28-37




[ Downloaded from ijbc.ir on 2024-10-12 ]