

# Malignant Hypertension Associated with Rhabdomyosarcoma

Keikhaei B<sup>1</sup>, Pedram M<sup>2</sup>, Eshagh Hossaini K<sup>3</sup>

1. Assistant professor of pediatric hematology & oncology, Ahwaz Thalassemia and Hemoglobinopathies Research Center, Ahwaz Jundishapur University of Medical Sciences

2. Professor of pediatric hematology & oncology, Ahwaz Thalassemia and Hemoglobinopathies Research Center, Ahwaz Jundishapur University of Medical Sciences

3. Fellowship of pediatric hematology & oncology, Ahwaz Thalassemia and Hemoglobinopathies Research Center, Ahwaz Jundishapur University of Medical Sciences

Corresponding Author: Keikhaei B; E-mail: Keikhaeib@yahoo.com. Tel: +989166173271 Fax: +986113743289

## Abstract

The Hypertension is divided into two types: primary and secondary. the secondary type, is particularly due to renal and arterial origin and is mostly seen. In children the Secondary hypertension caused by malignancies is rare. This is a case of abdominal rhabdomyosarcoma with malignant hypertension.

**Keywords:** Rhabdomyosarcoma, malignant hypertension, encasement

## Introduction

The Malignant hypertension (MHTN) is a medical emergency which is mostly secondary in children (1), that is rarely associated with malignant abdominal tumors (1,2,3) and it can be presented with the signs and symptoms of hypertensive encephalopathy including vomiting, headache, blurred vision, papilledema and occasionally seizure (1,4).

Some solid intra-abdominal tumors such as Lymphoma, Neuroblastoma (NB), or Rhabdomyosarcoma (RMS) are occasionally associated with the MHTN due to high plasma renin and catecholamine levels or obstruction of large arteries (1,2,3).

The RMS is a malignant solid tumor arising from soft tissue which presents rarely as huge mass and consequent pressure effect on large vessels (4,5).

## Case Report

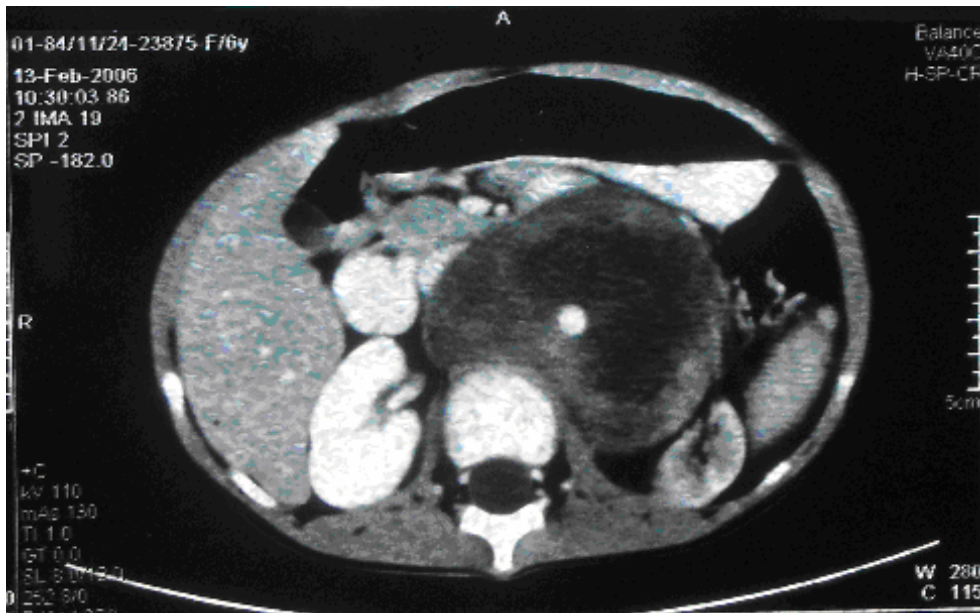
A six-year-old girl referred to this center with a history of intermittent abdominal colicky pain and repeated vomiting (often postprandial) since one

week prior to admission. The symptoms progressed gradually. Then she developed headache and tonic clonic seizure candidating her for admission in hospital. On arrival, the blood pressure (BP) was 240/120 mm.Hg in upper extremities with strong pulses and 120/80 mm.Hg in lower extremities with weak & filliform pulses.

In physical examination a firm mass about 7\*9 cm was palpable in periumbilical area that was shown in sonography and CT scan as a heterogenous mass around abdominal aorta (below celiac artery branch till bifurcation) associated with aortic encasement & small size left kidney (Figure 1).

She was put on the antihypertensive drugs such as angiotensin converting enzyme (ACE) inhibitors & calcium channel blockers with good response.

Needle biopsy was done, then Pathology department reported the embryonal RMS. Immunohistochemical staining showed positivity of Desmin and Myogenin with negativity of neuronal specific enolase (NSE), Mic2, CA125 and Cytokeratinin that corroborated the RMS (figure 2)



**Figure 1:** abdominal CT scan shows aortic encasement and left kidney hypoplasia (pre treatment)

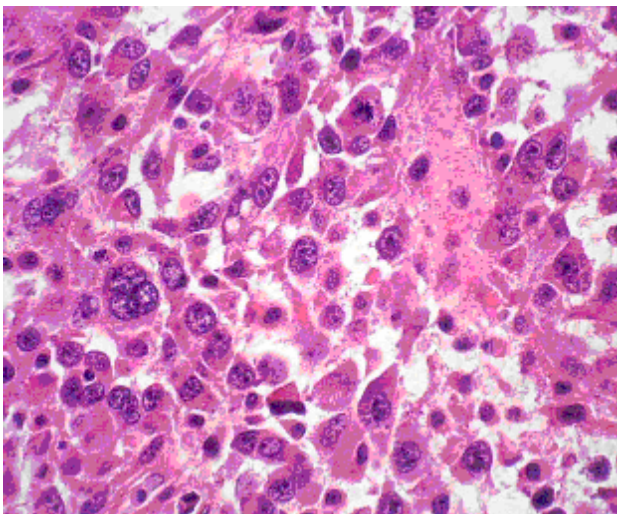
Investigations for distant metastasis was negative, thus due to these findings, chemotherapy started for her.

Few months later she developed the hypertension in upper extremities 170/120 mm.Hg & in lower extremities 130/100 mm.Hg- and rising in creatinine level. She was admitted in hospital

again.

The sonography showed left renal artery obstruction & consequent left kidney hypoplasia.

the Treatment such as debulking surgery , chemotherapy , radiation and anti hypertensive drugs was done for her .The BP went under control gradually.(Figure 3)



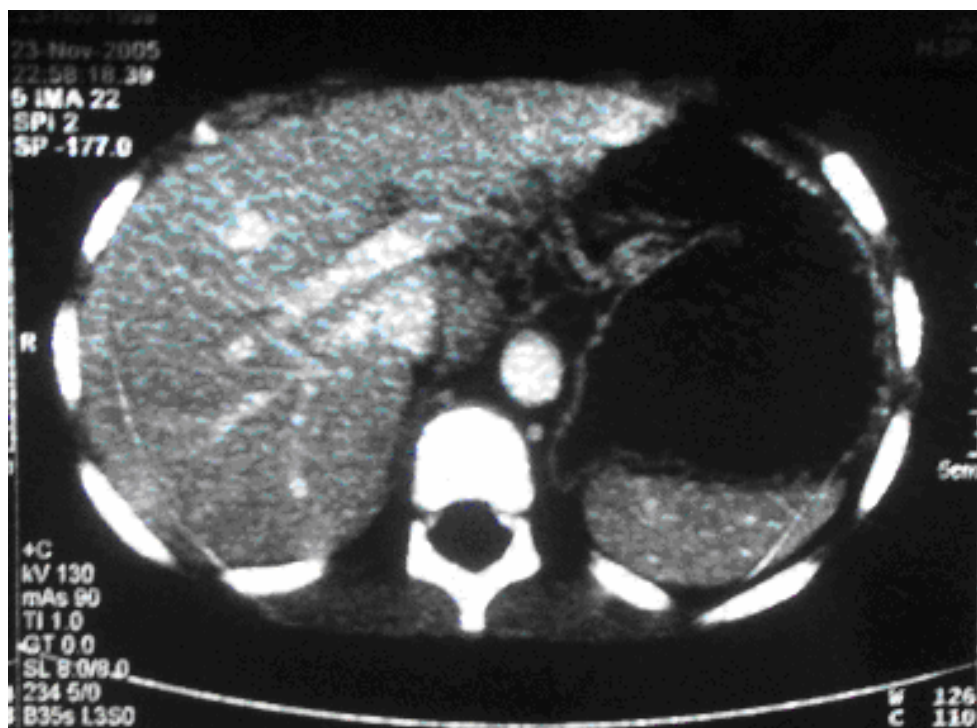
**Figure 2:** Histopathology shows malignant soft tissue tumor composed of mucoïd background and infiltration of neoplastic cells with round to ovaloid nuclei: Compatible with embryonal RMS.

## Discussion

Although the MHTN is a presenting sign of some solid intra abdominal tumors such as the neuroblastoma and wilm's tumor (1,2,3) but it is rarely associated with the RMS (2,3,6) ; however a huge mass can encase large arteries (the aorta or renal artery)and accompany with the HTN (1,5).

The RMS is the most common form of soft tissue sarcoma in children (2,3,6),containing 5-8% of all malignancies in this age (6)and it is the 3rd most common solid intraabdominal tumor (2,5,7),which originates from primitive mesenchyme (2,3,4,6,7). The RMS divides into four subtypes: Embryonal (60%)-Alveolar (15%)-Pleomorphic and undifferentiated (2,3,6).

The most presenting finding is a mass (2,3,4,6) that can produce organ displacement & mass pressure effect (2,3,6). The Retroperitoneal RMS accounts for 11% of cases (5,7)and can be either



**Figure 3:** The same case (Post treatment)

embryonal or alveolar (5,7) and has the worst prognosis especially with distant metastasis (2,6,7) which is usually seen in older children (5).

In our patient, encasement of the abdominal aorta and pressure effect on the left renal artery by a bulky embryonic RMS in retroperitoneal area has produced the MHTN and hypertensive encephalopathy, then after treatment, the HTN became normal. But she became hypertensive again in spite of getting anti hypertension therapy due to left renal hyperplasia

## Conclusion

Most of children with the HTN have so called secondary HTN(8) that means the HTN caused by a specific disorder of a particular organ or blood vessels such as the kidneys, adrenal gland or aortic artery.(9,8)

The kidney serves as endocrine organ to control the blood pressure via rennin secretion.(10) Increased rennin secretion plays a role in several hypertensive conditions associated with kidney dysfunction.(11)

the Renovascular hypertension is caused by artery narrowing of gives rise one or both kidneys, which to renal artery stenosis.(12)

Decreased kidney perfusion, triggers the rennin\_angiotensin system, causing increased secretion of rennin, which leads to HTN.(12)

This unique case shows association of MHTN and hypertensive encephalopathy with the retroperitoneal embryonal RMS, that we believed it as the first report.

One clinical point of this case is importance of measuring BP as a part of physical examination especially with seizure, when the HTN supervened, renal causes should be regarded. Recognition of this entity as a potential cause of the MHTN is important for an appropriate management.

This case also emphasized that the RMS should be included (albeit rare) in differential diagnosis of the HTN.

## References

1. Daniel Bernstein, *Nelson Textbook of Pediatrics 17th edition 2004:1592\_1598.Saunders Company.*
2. Leonard H. Wexler & William H. Neyer, *Principal & Practice of Pediatric Oncology 5th edition 2006:971\_991*

3. Philip Lanzkowsky et al, *Manual of Pediatric Hematology & Oncology* 4th edition 2005:561\_579

4. Sarah Zarbock, *New recommendation for treatment of hypertension in children: The American Academy of Physician Assistants (AAPA) conference*

5. Philip R. Exelby, *Malignant Abdominal Tumors in Children: A Cancer Journal for Clinicians*, 2006; 20:342\_351

6. Carola A.S. Arndt, *Nelson Textbook of Pediatrics*, 17th edition, 2004:1714\_1717

7. Agarwala Sandeep, *Pediatric Rhabdomyosarcoma and Nonrhabdomyosarcoma Soft Tissue Sarcoma: Journal of Indian Association of Pediatric Surgeon*; 2006; 11:15\_23.

8. *Medicine Net.com: high blood pressure; causes and medications.*

9. *American Heart Association. 2002 Heart and Stroke Statistical Update. Dallas, Tex: American Heart Association; 2001.*

10. Lavagh J. *Lavagh's lesson in pathophysiology and clinical Pearls for treating HTN. American Journal Hypertension*. 2001; 14(2):186\_194.

11. Alosachie IJ, Lad PM. *Laboratory diagnosis in hypertension. Journal of clinical Lab Anal*. 1994; 8(5):293\_308.

12. Safian RD, Textor SC. *Renal artery stenosis. New England Journal of Medicine*. 2001; 344(6):431\_442.