IJBC 2014;6(3): 159-161

Platelet Satellitism in a Three and Half Year Old Girl with Hemolytic Anemia and Normal Platelet Count

Baghersalimi A [1], Darbandi B [1], Alizadeh H [1]*
1. Guilan University of Medical Sciences, Rasht, Iran.

***Corresponding Author:** Alizadeh H, Email: hamidalizadeh1359@ gmail.com

Submitted: 07-12-2013 , Accepted: 30-04-2014

Abstract

Platelet adherence surrounding leucocytes in a rosette formation or platelet satellitism is a rare phenomenon. This finding has been observed almost exclusively in Ethylenediaminetetraacetic acid treated blood at room temperature. The mechanism underlying this phenomenon is not fully understood. In many reports of platelet satellitism platelets clump to polymorphonuclear neutrophils in healthy persons undergoing routine checkup, and sometimes this phenomenon could be a reason for spurious thrombocytopenia. Herein, we report a case of platelet rosetting around monocytes in a patient who was admitted with acute hemolysis due to G6PD deficiency with normal platelet count.

Keywords: Platelet satellitism, monocyte, G6PD deficiency.

Introduction

Platelet satellitism is virtually always an in vitro phenomenon involving polymorphonuclear neutrophils in Ethylenediaminetetraacetic acid (EDTA) treated blood [1, 2, 3, 4]. This phenomenon was reported for the first time in 1963 by Field and MacLoad 3. Since then around 100 cases have been reported in the literature [4, 5]. The precise underlying mechanism of this finding remains to be fully elucidated.

Bizzaro and Goldschmeding showed that autoantibodies directed to the glycoprotein 2b/3a complex on the platelet membrane, as well as against the neutrophil FC receptor, are involved [6,7].

There is a possibility that the epitopes for those antibodies are hidden in leukocyte and platelet membrane and EDTA exposes them with physically or chemically changing the membrane, which would explain why satellitism is observed exclusively with this specific anticoagulant [8]. The clinical importance of this condition is its association with pseudothrombocytopenia [4,5,9].

Report of the case

A three and half year old girl presented to our hematologic ward with complaints of acute pallor and change in urine color (cola like urine). She had a history of G6PD (glucose 6 phosphate dehydrogenase) deficiency and underwent her first acute hemolytic anemia due to exposure to fava bean. Her hemoglobin at admission was 5 g/dl with normal platelet count (402. 10^3) and the white blood cell count was 9500/cu mm with normal differential count. Blood samples were drawn in plastic syringes and collected in standard tubes containing EDTA and sodium citrate as anticoagulant.

All related tests of the coagulation profile including bleeding time, clotting time, prothrombin time and partial thromboplastin time were within normal limits.

In Wright- stained peripheral blood smear prepared from EDTA anticoagulated blood sample we saw platelets clumping to monocytes (Figure 1). Platelet morphology and size was normal and there was no platelet satellitism with polymorphoneuclears. When we repeated the sample with sodium citrate as anticoagulant (in sampling as serial hemoglobin checking to manage acute hemolysis) this finding was absent. The patient was treated with hydration and packed cell transfusion.

She was discharged with hemoglobin level of

9.6 g/dl and follow up was suggested.

Discussion

The phenomenon of platelet adherence to leukocytes or so called platelet satellitism, have been observed with polymorphonuclear leukocytes in almost all reports [4, 5, 7, 9]. The pathophysiology of PS is still unclear. It has been demonstrated that platelet adhesion to neutrophils is mediated by IgG [10] which binds to glycoprotein 2b/3a on platelet membrane and FcRIII on the surface of neutrophils [7]. It has also been suggested that the adhesion phenomenon might be mediated by thrombospondin or some other alpha granule protein [11]. Phagocytosis of entire platelets has also been reported [1]. The platelet profiles that participate in rosette formation reveal a large number of glycogen particles compared with unattached ones [12]. The phenomenon is usually dependent on the presence of EDTA that exposes some antigens which are normally not exposed on circulating platelets [13].

The main clinical significance of this event lies in false low automated platelet counts or pseudothrombocytopenia. It may be seen in any age and most of individuals showing this phenomenon are asymptomatic. This finding has been seen in patients with vasculitis, lupus, mantel cell lymphoma and marginal zone B-cell lymphoma and most commonly in healthy individuals [3, 4, 5, 6]. Healthy individuals having platelet satellitism have been followed for 15 to 20 years without any ill effect [14].

The key commonality between our case and more classic platelet satellitism was that platelet clumping occurred only in the presence of EDTA as the anticoagulant and was absent with sodium citrate. The present case varied from other reports by her normal platelet count. We interestingly observed the platelet satellitism with monocytes which only few other studies have reported [6, 13], but almost all reports have reported this phenomenon with polymorphonuclear leukocytes [4, 5, 7, 9]. In review of litterateur we did not find any report of platelet satellitism in a G6PD deficiency patient. Although it seems to be a surprising phenomenon but maybe we report an incidental coherence.

Conclusion

A rare case of G6PD deficiency with concurrent platelet satellitism was presented. This is to our knowledge the first report of such a case in English

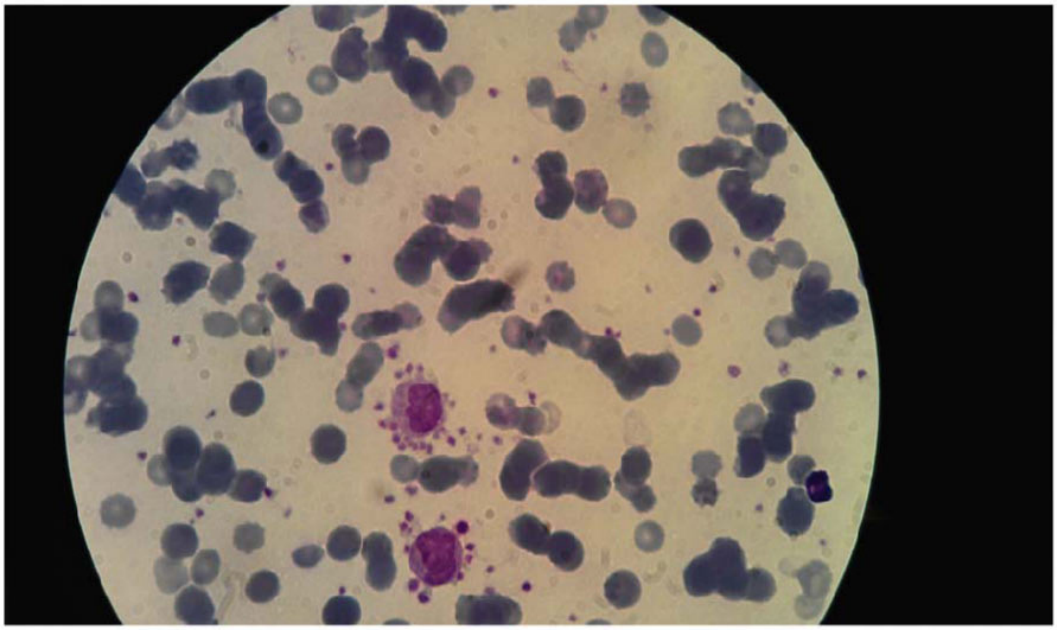

Figure 1: Two monocytes with platelet satellitism.

literature.

References

1. Paul P, Kaur M, Kakkar N, Kumar N. Co-existent Platelet Phagocytosis, Satellitism and Clumping Causing Spurious Thrombocytopenia.Indian J Hematol Blood Transfus. 2013;29(3):158-60.
2. Montague N, Blackwelder P, Alsayegh H, Ochoa R, Vial X, Byrne GE. Platelet satellitism and dual surface immunoglobulin light-chain expression in circulating splenic marginal zone lymphoma cells.. Ann Diagn Pathol. 2013;17(1):117-22.
3. Field EJ, MacLeod I. Platelet adherence to polymorphs. Br Med J. 1963; 2(5353): 388-9.
4. Withana RJ. Platelet satellitism--a curious phenomenon causing spurious thrombocytopaenia. Ceylon Med J. 1996;41(2):75-6.
5. Bobba RK, Doll DC. Platelet satellitism as a cause of spurious thrombocytopenia. Blood. 2012;119(18):4100.
6. Cesca C, Ben-Ezra J, Riley RS. Platelet satellitism as presenting finding in mantle cell lymphoma. A case report. Am J Clin Pathol. 2001;115(4):567-70.
7. Bizzaro N, Goldschmeding R, von dem Borne AE. Platelet satellitism is Fc gamma RIII (CD16) receptor-mediated. Am J Clin Pathol. 1995;103(6):740-4.
8. Criswell KA, Breider MA, Bleavins MR. EDTA-dependent platelet phagocytosis. A cytochemical, ultrastructural, and functional characterization. Am J Clin Pathol. 2001;115(3):376-84.
9. Kjeldsberg CR, Swanson J. Platelet satellitism. Blood. 1974;43(6):831-6.
10. Bodensteiner D, Talley R, Rosenfeld C. Platelet satellitism: a possible mechanism. South Med J. 1987;80(4):459-61.
11. Christopoulos C, Mattock C. Platelet satellitism and alpha granule proteins. J Clin Pathol. 1991 Sep;44(9):788-9.
12. Peters M, Heyderman RS, Klein NJ. Platelet satellitism. N Engl J Med. 1998;339(2):131-2.
13. Criswell KA, Breider MA, Bleavins MR. EDTA-dependent platelet phagocytosis. A cytochemical, ultrastructural, and functional characterization. Am J Clin Pathol. 2001;115(3):376-84.
14. Morselli M, Longo G, Bonacorsi G, Potenza L, Emilia G, Torelli G. Anticoagulant pseudothrombocytopenia with platelet satellitism. Haematologica. 1999;84(7):655.