Iranian Journal of Blood & Cancer

Journal Home Page: www.ijbc.ir

Case Report

Pneumothorax and Acute Kidney Injury in the Early Phase of Acute Lymphoblastic Leukemia Induction Therapy due to *Aspergillus Fumigatus* and *Pneumocystis Jirovecii* Co-Infection: A Case Report

Parinaz Sedighi[1,2], Hossein Esfahani[3]*

[1]Student Research Committee, Hamadan University of Medical Sciences, Hamadan, Iran
[2]Universal Scientific Education and Research Network (USERN), Tehran, Iran
[3]Department of Pediatrics, Faculty of Medicine, Hamadan University of Medical Sciences, Hamadan, Iran

ARTICLE INFO

Article History:
Received: 01.09.2019
Accepted: 13.11.2019

Keywords:
Acute Lymphoblastic Leukemia
Aspergillus Fumigatus
Pneumocystis Jirovecii Pneumonia
Pneumothorax
Cavitation

**Corresponding author:*
Hossein Esfahani
Associate Professor of Pediatric Hematology and Oncology,
Hamadan University of Medical Sciences, Hamadan, Iran.
Mobile: +98-912-3033080
Email: hesfehani@yahoo.com

ABSTRACT

Leukemia is the most common malignancy in children which leads to immunosuppression and predisposes patients to opportunistic infections. We report a 12-year-old girl with acute lymphoblastic leukemia (ALL) who developed simultaneous infection with *pneumocystis Jirovecii* pneumonia and *aspergillosis* in the induction phase of chemotherapy. The patient developed pulmonary cavitation and pneumothorax which was treated with trimethoprim-sulfamethoxasole in addition to intravenous liposomal Amphotrecin B. Pediatric oncologists should consider concurrent co-infection of opportunistic infections such as *aspergillus* fumigatus and *Pneumocystis Jirovecii* in immunocompromised patients especially if pneumothorax develops in early stages of disease or immunosuppressive therapy.

Please cite this article as: Sedighi P, Esfahani H. Pneumothorax and Acute Kidney Injury in the Early Phase of Acute Lymphoblastic Leukemia Induction Therapy due to *Aspergillus Fumigatus* and *Pneumocystis Jirovecii* Co-Infection: A Case Report. IJBC 2019; 11(4): 139-142.

Introduction

Leukemia is the most common hematological malignancy in children. Acute lymphoblastic leukemia (ALL) is the most common childhood leukemia (1) with an incidence of 5.45:100,000 persons in Iraq (2). Several genetic susceptibilities have been suggested for ALL, are considered important in response to treatment (3, 4). Patients with leukemia are susceptible to opportunistic infections due to defective mucocutaneous barriers, alterations in microbial colonization, defects in phagocytosis, cytokine release and toll-like receptor, disorders of adaptive immunity and reticuloendothelial system (5). Accordingly, leukemic patients are susceptible to opportunistic infections such as *pneumocystis Jirovecii* pneumonia and different kinds of fungal infections including aspergillosis (6). *Pneumocystis Jirovecii* can be a life-threatening condition in immunodeficient patients such as patients with acquired immunodeficiency syndrome (AIDS), malignancies or congenital immunodeficiencies, which necessitates greater attention and special care in these patients (7). The lymphocyte disorder in ALL patients, which may be due to the underlying disease or the effect of treatment, can predispose patients to more aggressive pneumocystis pneumonia infections that may lead to hypoxia, tachypnea, dyspnea and cough (8). One of the most common fungal infections in leukemic children is pulmonary aspergillosis, which can present with fever, cough, chest pain, hemoptysis and pulmonary infiltrates on radiological imaging (9, 10).

Herein, we present an adolescent girl suffering from leukemia with pulmonary cavitation and pneumothorax due to co-infection of *Pneumocystis Jirovecii* pneumonia and *aspergillus fumigatus* in the induction phase of chemotherapy.

[Downloaded from ijbc.ir on 2024-10-12]

Case Presentation

A 12-year-old girl with a diagnosis of pre-B cell ALL who was scheduled to receive induction chemotherapy with "BFM 2009 ALL" protocol, (Vincristine, Daunarubicin, L-Asparaginase and Dexamethasone) was admitted to Besat Hospital, Hamadan, Iran. Two weeks after commencement of chemotherapy, the patient suffered from acute chest pain. At physical examination, tachypnea with decreased right-sided breathing sounds was detected during auscultation. Chest radiography demonstrated right sided pneumothorax. As a result, chest tube was inserted which resulted in improvement of respiratory symptoms. In addition, trimethoprim-sulfamethoxasole was started to cover the probable infection with *Pneumocystis Jirovecii* pneumonia. One week after removing the chest tube, chest pain reappeared in the patient. Chest CT scan was performed in which repeated pneumothorax and cavity shaped lesions were identified in the right lung, so chest tube was re-inserted (figures 1 and 2). The patient underwent lung biopsy where the tissue was submitted for bacteriologic culture, pathological examination and analysis of Polymerase Chain Reaction (PCR) for mycobacterium tuberculosis and other causes of respiratory infections in immunocompromised patients (table 1). The result of PCR revealed *aspergillus fumigatus* and *Pneumocystis Jirovecii* co-infection, hence antifungal treatment with liposomal Amphotrecin B was added to trimethoprim-sulfamethoxasole. By resolution of respiratory symptoms, the patient was discharged with oral trimethoprim-sulfamethoxasole and itraconazole to complete the entire course of the treatment.

Discussion

Patients suffering from ALL are susceptible to opportunistic infections such as *Pneumocystis Jirovecii* pneumonia and invasive aspergillosis due to severe immunosuppression, protracted neutropenia and consumption of high-dose corticosteroid therapy (11). In the present case, concomitant infection of *Pneumocystis Jirovecii* pneumonia with aspergillosis resulted in progression of the disease to severe respiratory distress. This was due to the fact that in the early phase, only *Pneumocystis Jirovecii* pneumonia infection was diagnosed based on the clinical manifestations and imaging results of the patient. Therefore, insufficient treatment resulted in the recurrence of the symptoms after removal of the chest tube and the co-infection of *Pneumocystis Jirovecii* pneumonia and aspergillosis was diagnosed after PCR.

PJP is an important and life threatening infection, observed in HIV and non-HIV immunocompromised

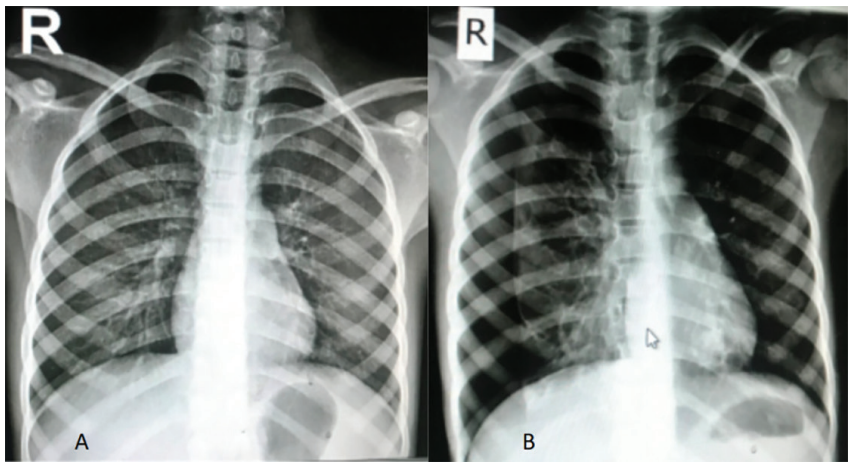

Figure 1: The first chest radiograph (A, on admission), demonstrate peribronchial cuffing, and the second chest radiograph (B, at the time of respiratory distress) demonstrate multiple cavities with right-sided pneumothorax.

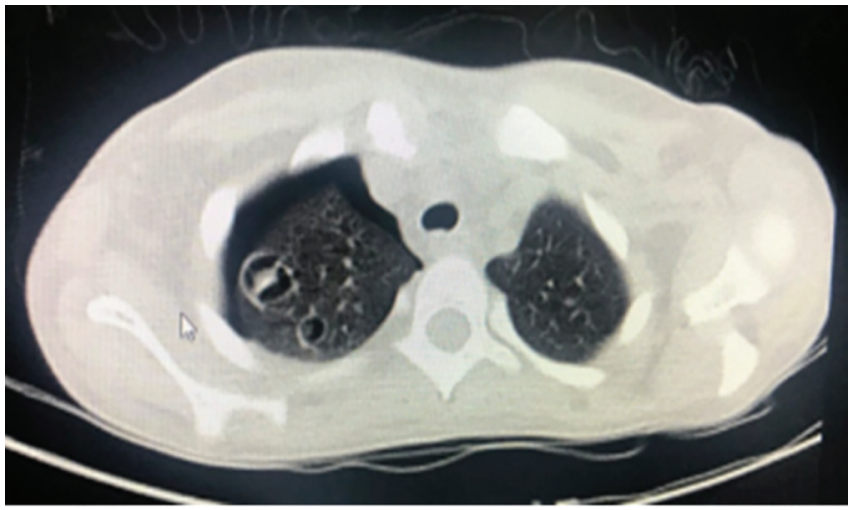

Figure 2: Chest computed tomography; demonstrating multiple cavities and right-sided pneumothorax.

[Downloaded from ijbc.ir on 2024-10-12]

Table 1: Initial and subsequent hematology and biochemistry findings

Laboratory tests	Result	Unit
White blood cell	7800	cells /micro liter
Hemoglobin	7	g/dL
Mean corpuscular volume (MCV)	?????	Femtoliter (fL)
Platelets	63000	cells /micro liter
Blood urea nitrogen: (in order)	10, 61, 68, 72, 81,	mg/dL
Creatinine: (in order)	0.6, 1/4, 1/6, 1/9, 2/1	mg/dL
Aspartate Aminotransferase	25	unit/L
Alanine Aminotransferase	36	unit/L
Erythrocyte sedimentation rate	110	ml/hour
C-reactive protein	+	Qualitative

patients and its co-infection with several pathogens have been reported (12). Co-infection of *Pneumocystis Jirovecii* pneumonia with aspergillosis is considered a diagnostic challenge, usually observed in immunocompromised patients. There are reports of co-infection of *Pneumocystis Jirovecii* pneumonia and aspergillosis in non-HIV old patients, immunocompromised due to systemic steroid therapy after brain surgery (9, 13). Short-term and high-dose steroid therapy has been considered as one of the risk factors of co-infection of *Pneumocystis Jirovecii* pneumonia and aspergillosis in non-HIV patients, which resulted in death of a patient, as reported by Hagia and colleagues (14). In their reported case, co-infection of *Pneumocystis Jirovecii* pneumonia and invasive pulmonary aspergillosis was diagnosed by CT-guided necroscopy and based on the results of pathologic examination (14). Although the underlying disease and the age range of our patient were different from the above-mentioned studies, they confirm the risk of co-infection of *Pneumocystis Jirovecii* pneumonia with pulmonary aspergillosis in immunocompromised patients.

The case presented by Lee and colleagues (15) was a 28-year-old women who developed *Pneumocystis Jirovecii* pneumonia and aspergillosis after organ transplantation. In their reported case, chest radiograph showed diffuse reticulonodular infiltration which progressed to "halo sign" after 3 weeks of treatment for *Pneumocystis Jirovecii* pneumonia and finally, bronchoalveolar lavage (BAL) confirmed the diagnosis in the patient. Although the age range of this patient (15) was closer to our case, compared to other studies (9, 12-14), the underlying disease and the method of diagnosing co-infection was different from ours. In another report, presented by Markantonatou and co-workers (16), co-infection of *Pneumocystis Jirovecii* pneumonia with pulmonary aspergillosis was reported in two cases; one patient suffered from crescentic IgA nephropathy, who received immunosuppressive therapy (corticosteroids) and responded to TMP-SMX treatment plus voriconazole, while the other patient, who suffered from non-Hodgkin lymphoma and developed the co-infection under chemotherapy did not respond to this treatment (16). The second case presented by Markantonatou and co-workers was one of the few cases, reporting co-infection of *Pneumocystis Jirovecii* pneumonia with pulmonary aspergillosis in a patient with leukemia, similar to that reported in the present study, while the type of leukemia differed from that of ours. All in all, all the above-mentioned studies, like ours, emphasize on the risk of co-infection of *Pneumocystis Jirovecii* pneumonia and aspergillosis in immunocompromised patients, which highlights that the physician must pay greater attention and have stronger clinical suspicion for appropriate diagnosis and management of this co-infection in such patients.

As presented above, co-infection of *Pneumocystis Jirovecii* pneumonia and aspergillosis was detected in patients with different diseases and was diagnosed by different methods. According to Fifth European Conference on Infections in Leukaemia (ECIL-5), immunofluorescense assay is defined as the most sensitive paraclinical diagnostic for diagnosis of *Pneumocystis Jirovecii* pneumonia and Real-Time PCR (RT-PCR) is advised for fluid specimens, although negative results are not able to rule out *Pneumocystis Jirovecii* pneumonia (17). In our case, co-infection of *Pneumocystis Jirovecii* pneumonia and aspergillosis was successfully diagnosed by PCR.

Conclusion

Aspergillosis and pneumocystis jirovecii are uncommon causes of pneumothorax, more commonly observed in immunocompromised patients. The co-infection, if it occurs in patients with leukemia, usually presents in late phases of cancer treatment. In the present case, pneumothorax happened in the first stages of the chemotherapy. Therefore, physicians should be aware of *aspergillus fumigatus* and *Pneumocystis jirovecii* co-infection in early stages of immunosuppressive or corticosteroid therapy.

Conflict of Interest: None declared.

References

1. Siegel DA, Henley SJ, Li J, Pollack LA, Van Dyne EA, White A. Rates and trends of pediatric acute lymphoblastic leukemia—United States, 2001–2014. MMWR Morbidity and mortality weekly report. 2017;66(36):950.
2. Alrudainy LA, Salih HM, Aldorky M. Incidence and pattern of childhood leukaemia in Basrah, Iraq during 2003-2007. Iran J Blood Cancer. 2009;2(1):11-7.
3. Miladpour B, Nejat Shokouhi A, Shirdel A, Entezari Heravi R, Banihashem A, Esmaeili H, et

[Downloaded from ijbc.ir on 2024-10-12]

al. Association of Acute Lymphoblastic Leukemia and MDR1 Gene Polymorphism in an Ethnic Iranian Population. Iranian Journal of Blood and Cancer. 2009;1(2):63-7.
4. Safaei A, Zaker F. Influences of Genetic Abnormality on the Risk of Acute Lymphoblastic Leukemia. Iranian Journal of Blood and Cancer. 2012;4(4):169-78.
5. Andrew Y. Koh PAP. Supptive Care of Children with Cancer. In: Philip A. Pizzo DGP, editor. Principles and Practice of Pediatric Oncology. 2. Philadelphia: Wolters Kluwer; 2015. p. 1190-242.
6. Ponce CA, Gallo M, Bustamante R, Vargas SL. Pneumocystis colonization is highly prevalent in the autopsied lungs of the general population. Clinical infectious diseases : an official publication of the Infectious Diseases Society of America. 2010;50(3):347-53.
7. Sheikholeslami MF, Sadraei J, Farnia P, Forozandeh M. Colonization of Pneumocystis jirovecii in Chronic Obstructive Pulmonary Disease (COPD) patients and the rate of Pneumocystis pneumonia in Iranian non-HIV+ immunocompromised patients. Iranian journal of microbiology. 2013;5(4):411.
8. Hallek M, Shanafelt TD, Eichhorst B. Chronic lymphocytic leukaemia. The Lancet. 2018;391(10129):1524-37.
9. Kaira K, Shimoyama Y, Takahashi Y, Iida T, Yanagitani N, Sunaga N, et al. Coinfection of Invasive Pulmonary Aspergillosis and Pneumocystis Jiroveci Pneumonia in a Non-HIV Patient. Acta Med Okayama. 2007;61(4):235-8.
10. Gigliotti F, Wright TW. Fungal Infections. In: Kliegman RM, editor. Nelson text book of pediatrics. 1. 21 ed. Philadelphia: Elsevier; 2020. p. 6696-701.
11. Vernovsky I, Dellaripa PF. Pneumocystis carinii pneumonia prophylaxis in patients with rheumatic diseases undergoing immunosuppressive therapy: prealence and associated features. Journal of clinical rheumatology : practical reports on rheumatic & musculoskeletal diseases. 2000;6(2):94-101.
12. Guo F, Chen Y, Yang S-L, Xia H, Li X-W, Tong Z-H. Pneumocystis pneumonia in HIV-infected and immunocompromised non-HIV infected patients: a retrospective study of two centers in China. PLoS One. 2014;9(7):e101943.
13. Baumann S, Reinwald M, Haghi D, Hofmann W-K, Buchheidt D. Coinfection of Pneumocystis jirovecii and invasive pulmonary aspergillosis in an immunocompromised patient: a diagnostic challenge. Oncology Research and Treatment. 2013;36(10):582-4.
14. Hagiya H, Miyake T, Kokumai Y, Murase T, Kuroe Y, Nojima H, et al. Co-infection with invasive pulmonary aspergillosis and Pneumocystis jirovecii pneumonia after corticosteroid therapy. Journal of Infection and Chemotherapy. 2013;19(2):342-7.
15. Lee PH, Fu PK. Coinfection of pneumocystis jiroveci pneumonia and pulmonary aspergillosis in a non-HIV-infected patient. Journal of microbiology, immunology, and infection = Wei mian yu gan ran za zhi. 2018;51(6):860-1.
16. Markantonatou AM, Ioakimidou A, Arvaniti K, Manou E, Papadopoulos V, Kiriklidou P, et al. Pulmonary co-infections by Pneumocystis jirovecii and Aspergillus fumigatus in non-HIV patients: A report of two cases and literature review. Mycoses. 2017;60(10):626-33.
17. Alanio A, Hauser PM, Lagrou K, Melchers WJ, Helweg-Larsen J, Matos O, et al. ECIL guidelines for the diagnosis of Pneumocystis jirovecii pneumonia in patients with haematological malignancies and stem cell transplant recipients. The Journal of antimicrobial chemotherapy. 2016;71(9):2386-96.

[Downloaded from ijbc.ir on 2024-10-12]