



## CASE REPORT

# Solitary Fibrous Tumor of Testis: A rare Case with Review of Literature

Parham Nejati<sup>1</sup>, Farhad Amirian<sup>2</sup>, Masoud Sadeghi<sup>1</sup>, Kimia Karami<sup>3</sup>, Mazaher Ramezani<sup>2\*</sup>

<sup>1</sup>Medical Biology Research Center, Kermanshah University of Medical Sciences, Kermanshah, Iran

<sup>2</sup>Molecular Pathology Research Center, Imam Reza hospital, Kermanshah University of Medical Sciences, Kermanshah, Iran

<sup>3</sup>Students Research Committee, Kermanshah University of Medical Sciences, Kermanshah, Iran

## ARTICLE INFO

### Article History:

Received: 12.11.2019

Accepted: 18.01.2020

### Keywords:

Solitary fibrous tumor

CD34

CD99

Paratesticular

Case report

\*Corresponding author:

Mazaher Ramezani,  
Molecular Pathology Research Center,  
Imam Reza Hospital, Kermanshah  
University of Medical Sciences,  
Kermanshah, Iran

Email: [mazaher\\_ramezani@yahoo.com](mailto:mazaher_ramezani@yahoo.com)

## ABSTRACT

Solitary fibrous tumors (SFTs) more commonly arise in the pleura but recently, they have been reported in several extrapleural organs. Urogenital localization is rare, and only small numbers of cases of paratesticular SFT have been reported. An 81-year-old male with a history of colon carcinoma and complaint of testis swelling was referred for evaluation of a right paratesticular mass. Physical examination revealed a 2 cm oval-shaped paratesticular mass and herniation of intestinal loops in the right inguinal region after cough and Valsalva maneuver. An ultrasound examination was found in the upper pole of testis a well-defined hypoechoic mass in favor of testicular mass. It also revealed moderate to severe bilateral hydrocele and calcified wall in favor of benign lesion. In conclusion, SFT should be considered in the differential diagnosis of paratesticular masses and needs to be confirmed by IHC. CD34 and CD99 biomarkers are useful for confirmation of SFT.

Please cite this article as: Nejati P, Amirian F, Sadeghi M, Karami K, Ramezani M. Solitary Fibrous Tumor of Testis: A rare Case with Review of Literature. IJBC 2020; 12(1): 34-37.

## Introduction

The solitary fibrous tumor (SFT) is a less frequent spindle cell neoplasm stemming from mesenchymal cells. It was first described by Klemperer and Rabin.<sup>1</sup> In the past, most SFTs were known as hemangiopericytomas. Then after, pathologists used "solitary fibrous tumor" instead of "hemangiopericytoma".<sup>2</sup> SFTs more commonly arise in the pleura, but recently they have been identified in many extrapleural sites such as; meninges, oral cavity, nasal cavity, mediastinum, orbit, pelvis, retroperitoneum, kidney, vagina, vulva, urinary bladder, seminal vesicles, prostate, testis, and paratesticular region.<sup>3-6</sup>

To the best of our knowledge, the SFTs in the urogenital organs are rare and uncommon<sup>7</sup> and only a limited number of Paratesticular SFTs have been reported. So there are controversies on histopathogenesis of these tumors.<sup>8-11</sup> It is very important to make a differential diagnosis with the help of immunohistochemistry examinations. In the present report, we introduce a rare

case of paratesticular SFT and its clinical, pathological and immunohistochemical characteristics.

## Case Presentation

An 81-year-old male with a history of colon carcinoma and complaint of right testis painless swelling was referred for evaluation of a right paratesticular mass. In the past medical history, there was a transurethral resection of the bladder that the patient was not aware of the pathology report. The report was not available and no significant treatment was done.

Physical examination revealed a 2 cm oval-shaped paratesticular mass and herniation of intestinal loops in the right inguinal region after cough and Valsalva maneuver. Complete blood count and routine blood biochemistry reports were within the normal range. Testis tumor markers were evaluated and a mild increase in carcinoembryonic antigen (CEA) of serum was seen (7.6 ng/ml; reference range: 0-4 ng/ml). Alpha-

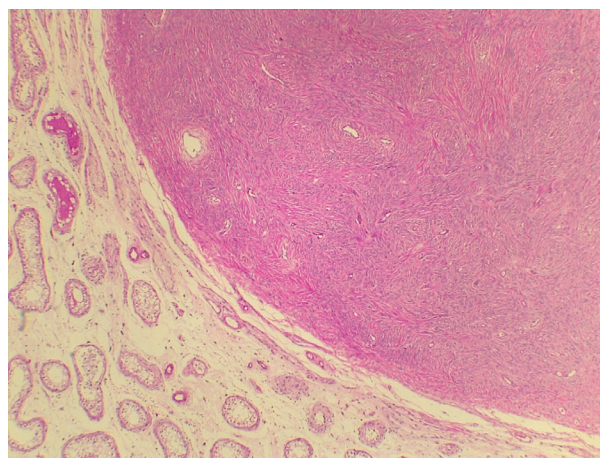
fetoprotein (AFP) was 101.5ng/ml, (reference range: up to 8.75 ng/ml), lactate dehydrogenase (LDH) was 290 IU/L (reference range: 225-500 IU/L), and beta-human chorionic gonadotropin ( $\beta$ hCG) was 0.95 mIU/ml (reference range: up to 2.24 mIU/ml). An ultrasound examination was found in the upper pole of testis a well-defined hypoechoic mass (9\*7mm) in favor of testicular mass. It also revealed moderate to severe bilateral hydrocele and calcified wall in favor of benign lesion. Meanwhile left kidney simple cortical cyst (27mm) in ultrasound examination was detected. Size of each testis was 45\*23 mm. The paratesticular tumor was excised and sent to the pathologist. Hematoxylin-Eosin stain showed a proliferation of spindle cells in storiform pattern with a few dilated vessels (Figure 1). Immunohistochemical examination showed the cluster of differentiation (CD) 99 positive and strong focally positivity CD34 in the neoplastic cells of the tumor but it was negative for B-cell lymphoma 2 (BCL-2), (Figure 2). Thus, the diagnosis of a paratesticular solitary fibrous tumor confirmed by histopathology and immunohistochemical findings. Follow-up after surgical treatment was not available and the patient's written consent to report the case obtained.

### Discussion

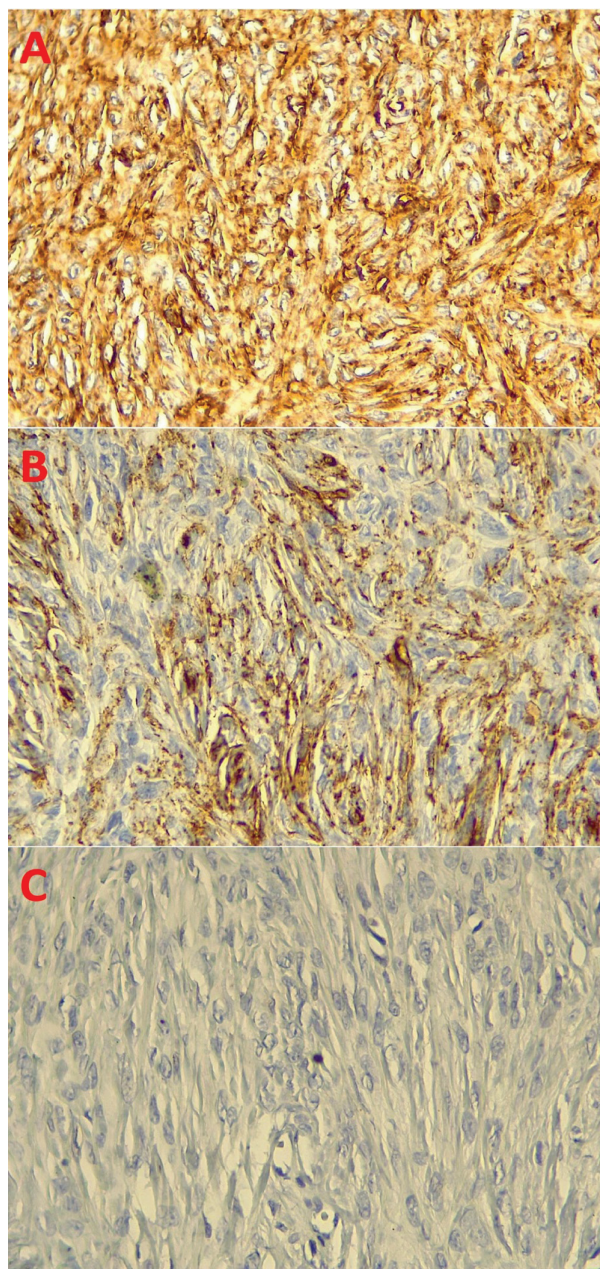
SFT is a mesenchymal neoplasm and it was first reported in 1931.<sup>1</sup> SFT is pathologically characterized by spindle cell proliferation. Although it is suggested that SFTs are limited to the pleura, they have been increasingly identified in many extrapleural sites.<sup>3-6</sup> Currently, only a small number of SFT cases have been recognized in the urogenital organs, testis and paratesticular region.<sup>7-11</sup> Immunohistochemistry has a prominent role in accurate diagnosis of tumor and ruling out of differential diagnosis.<sup>12</sup>

Our IHC results showed focal positivity for CD34 which is compatible with previous studies.<sup>7, 13-16</sup> CD34 immunoreactivity has been reported strongly in most SFTs. Although CD34 is considered as the most prominent feature in the diagnosis of SFTs,<sup>17</sup> about 5-10% of SFTs do not show any positivity for CD34.<sup>18</sup> Moreover, malignant SFTs mostly showed less CD34 reactivity. The histological criteria in favor of malignancy are larger tumors (more than 5 cm) with hypercellularity, nuclear pleomorphism, necrosis, more than 4 mitoses/10 HPF, and infiltrative borders.<sup>19</sup>

Other positive immunoreactivities in the present case include CD99. On the other hand, IHC examination showed negative expression of BCL-2 in our case while in contrast to our result, previous studies generally showed positivity for BCL-2.<sup>13-15</sup> Moreover, C Gengler & L Guillou showed positive reactivity for BCL-2 (30%), CD34 (80-90%), CD99 (70%), EMA (30%) and actin (20%) and negative reactivity for Desmin, cytokeratin and S-100 protein.<sup>19</sup> Despite the fact that the above mentioned IHC markers are strongly suggested in SFT diagnosis, Chmielecki and colleagues<sup>19</sup> reported a novel fusion gene, NAB2-STAT6, to characterize the SFTs. Several studies also revealed that STAT6 can be used for differential diagnosis of SFTs.<sup>20-22</sup>



**Figure 1:** Hematoxylin-Eosin staining: Paratesticular SFT with spindle cells in storiform pattern ( $\times 40$  magnification).



**Figure 2:** Immunohistochemistry staining: A) CD99 positivity, B) CD34 focal positivity, and C) BCL-2 negativity ( $\times 400$  magnification).

As most of the SFTs are benign and well encapsulated,

complete removal of the tumor with negative margins is the common treatment for SFTs<sup>23,24</sup> and those with malignant characteristics need more therapeutic measures.<sup>9</sup> However, several studies have demonstrated that radiotherapy and chemotherapy, with ifosfamide and adriamycin, was effective.<sup>9,25</sup> The role of radiotherapy and chemotherapy is uncertain and further study is needed.<sup>7</sup> Therefore, differentiating the malignant SFTs from benign ones using IHC and histopathology can help to choose the most effective way of management.

### Conclusion

SFT should be considered in the differential diagnosis of paratesticular masses and needs to be confirmed by IHC. CD34 and CD99 biomarkers are useful for confirmation of SFT.

**Conflict of Interest:** None declared.

### References

- Kelemperer P, Rabin C. Primary neoplasm of the pleura: a report of 5 cases. *Arch Pathol.* 1931;11:385-412. PubMed PMID: 1415270.
- Gengler C, Guillou L. Solitary fibrous tumour and haemangiopericytoma: evolution of a concept. *Histopathology.* 2006;48(1):63-74. doi: 10.1111/j.1365-2559.2005.02290.x. PubMed PMID: 16359538.
- Brunnemann RB, Ro JY, Ordonez NG, Mooney J, El-Naggar AK, Ayala AG. Extrapleural solitary fibrous tumor: a clinicopathologic study of 24 cases. *Mod Pathol.* 1999;12(11):1034-42. PubMed PMID: 10574600.
- Fukunaga M, Naganuma H, Nikaido T, Harada T, Ushigome S. Extrapleural solitary fibrous tumor: a report of seven cases. *Mod Pathol.* 1997;10(5):443-50. PubMed PMID: 9160308.
- Kpolat N, Ardiçoğlu A, Yahşi S, Onur AR. Paratesticular Solitary Fibrous Tumour: Case Report and Review of the Literature. *Turk J Med Sci.* 2003;33(2):121-5.
- Jones MA, Young RH, Scully RE. Benign fibromatous tumors of the testis and paratesticular region: a report of 9 cases with a proposed classification of fibromatous tumors and tumor-like lesions. *Am J Surg Pathol.* 1997;21(3):296-305. PubMed PMID: 9060599.
- Zhou Y, Gong G, Tang Y, Tang J, Gan Y, Dai Y. Paratesticular solitary fibrous tumor: a case report and review of literature. *Int J Clin Exp Pathol.* 2015;8(3):3358. PubMed PMID: 26045868
- Cafiero F, Gipponi M, Peressini A, Barabino P, Queirolo P, Nicolo M, et al. Solitary fibrous tumor of the inguinal region: a clinicopathological, light-microscopic, immunohistochemical, electron microscopic and flow-cytometric DNA study. *Anticancer Res.* 2001;21(6A):4091-4. PubMed PMID: 11911298.
- Gold JS, Antonescu CR, Hajdu C, Ferrone CR, Hussain M, Lewis JJ, et al. Clinicopathologic correlates of solitary fibrous tumors. *Cancer.* 2002;94(4):1057-68. PubMed PMID: 11920476.
- Ilica AT, Ors F, Bag M, Guvenc I, Duran C, Buyukbayram H. An uncommon cause of inguinoscrotal swelling: Solitary fibrous tumor of the spermatic cord. *Eur J Radiol.* 2008;67(1):25-8. doi: 10.1016/j.ejrex.2008.04.020.
- Márquez AM, Vicioso LR, Castro AL, Casals JS, Alcázar JR, Matilla AV. Paratesticular solitary fibrous tumor. *Arch Esp Urol.* 2001;54(7):716-8. PubMed PMID: 11692438.
- Selves J, Long-Mira E, Mathieu MC, Rochaix P, Ilié M. Immunohistochemistry for Diagnosis of Metastatic Carcinomas of Unknown Primary Site. *Cancers (Basel).* 2018;10(4):108. Published 2018 Apr 5. doi:10.3390/cancers10040108. PubMed PMID: 29621151.
- Hanau CA, Miettinen M. Solitary fibrous tumor: histological and immunohistochemical spectrum of benign and malignant variants presenting at different sites. *Hum Pathol.* 1995;26(4):440-9. doi: 10.1016/0046-8177(95)90147-7. PubMed PMID: 7705824.
- Rao N, Colby TV, Falconieri G, Cohen H, Moran CA, Suster S. Intrapulmonary solitary fibrous tumors: clinicopathologic and immunohistochemical study of 24 cases. *Am J Surg Pathol.* 2013;37(2):155-66. doi: 10.1097/PAS.0b013e31826a92f5. PubMed PMID: 23108019.
- Hu S, Yi L, Yang L, Wang Y. Solitary fibrous tumor of the spermatic cord: A case report and literature review. *Experimental and therapeutic medicine.* 2015;9(1):55-8. doi: 10.3892/etm.2014.2066. PubMed PMID: 25452776.
- Zhao X-y, Zeng M, Yang Q-y, Jing C-p, Zhang Y. Scrotum solitary fibrous tumor: A case report and review of literature. *Medicine.* 2017;96(48). doi: 10.1097/MD.00000000000008854. PubMed PMID: 29310366.
- Ma J, Du J, Zhang Z, Wang H, Wang J. Synchronous primary triple carcinoma of thyroid and kidney accompanied by solitary fibrous tumor of the kidney: a unique case report. *Int J Clin Exp Pathol.* 2014;7(7):4268. PubMed PMID: 25120808.
- Chan J. Solitary fibrous tumour—everywhere, and a diagnosis in vogue. *Histopathology.* 1997;31(6):568-76. PubMed PMID: 9447390.
- Parikh BJ, Parikh SB, Panjvani SI, Shah AA, Joshi DS. Paratesticular Solitary Fibrous Tumour: A Case Report. *Gujarat Med J.* 2012;67(2):126-8.
- Yoshida A, Tsuta K, Ohno M, Yoshida M, Narita Y, Kawai A, et al. STAT6 immunohistochemistry is helpful in the diagnosis of solitary fibrous tumors. *Am J Surg Pathol.* 2014;38(4):552-9. doi: 10.1097/PAS.0000000000000137. PubMed PMID: 24625420.
- Doyle LA, Vivero M, Fletcher CD, Mertens F, Hornick JL. Nuclear expression of STAT6 distinguishes solitary fibrous tumor from histologic mimics. *Mod Pathol.* 2014;27(3):390. doi: 10.1038/modpathol.2013.164. PubMed PMID: 24030747.
- Huang SC, Li CF, Kao YC, Chuang IC, Tai HC, Tsai JW, et al. The clinicopathological significance

- of NAB 2-STAT 6 gene fusions in 52 cases of intrathoracic solitary fibrous tumors. *Cancer Med.* 2016;5(2):159-68. doi: 10.1002/cam4.572. PubMed PMID: 26686340.
23. Marak CP, Dorokhova O, Guddati AK. Solitary fibrous tumor of the pleura. *Med Oncol.* 2013;30(2):573. doi: 10.1007/s12032-013-0573-0.
24. Uemura K, Hayashi T, Matsuoka K, editors. Solitary fibrous tumor of the greater omentum in an inguinal hernia sac. *Int Canc Conf J.* 2012;1(2):70-3. doi: 10.1007/s13691-011-0013-y.
25. de Perrot M, Fischer S, Bründler M-A, Sekine Y, Keshavjee S. Solitary fibrous tumors of the pleura. *The Annals of thoracic surgery.* 2002;74(1):285-93. doi: 10.1016/s0003-4975(01)03374-4. PubMed PMID: 12118790.