



CASE REPORT

Papillary Adenocarcinoma of the Lung in a Young Man: A Case Report

Mazaher Ramezani¹, Ruhollah Heydari^{2,3}, Farhad Amirian¹, Masoud Sadeghi⁴

¹Molecular Pathology Research Center, Imam Reza Hospital, Kermanshah University of Medical Sciences, Kermanshah, Iran

²Students Research Committee, Kermanshah University of Medical Sciences, Kermanshah, Iran

³Clinical Research Development Center, Imam Reza Hospital, Kermanshah University of Medical Sciences, Kermanshah, Iran

⁴Medical Biology Research Center, Kermanshah University of Medical Sciences, Kermanshah, Iran

ARTICLE INFO

Article History:

Received: 21.02.2020

Accepted: 18.05.2020

Keywords:

Papillary adenocarcinoma

Lung

Youth

*Corresponding author:

Masoud Sadeghi,
Medical Biology Research Center,
Kermanshah University of Medical
Sciences, Kermanshah, Iran
Tel: +98 9185960644
Email: sadeghi_mbrc@yahoo.com

Please cite this article as: Ramezani M, Heydari R, Amirian F, Sadeghi M. Papillary Adenocarcinoma of the Lung in a Young Man: A Case Report. IJBC 2020; 12(2): 64-66.

ABSTRACT

Lung cancer is the leading cause of cancer mortality worldwide. Adenocarcinoma is the most frequent pulmonary malignancy in most parts of the world. The papillary predominant subtype is applied when more than 75% of the tumor has the papillary architecture in histopathology. This subtype consists of about one-tenth of pulmonary adenocarcinomas. A 27-year-old man was referred with the history of dyspnea for the past three months. The patient had a diagnosis of right pulmonary empyema and was on medical treatment. After non-response he underwent surgery. The pathologist reported papillary adenocarcinoma of the lung, moderately differentiated with pleural involvement. Immunohistochemistry confirmed the diagnosis. Correct diagnosis of this subtype in histopathology is necessary for the determination of prognosis, cytogenetic changes, and selecting best treatment modalities.

Introduction

Lung cancer is the principal cause of cancer mortality in the United States and the whole world.^{1,2} It is the second cancer causing mortality in Iranian men after gastric cancer. In women, lung cancer is the fifth cause of cancer mortality after breast, stomach, esophagus and colorectal cancers.³ Adenocarcinoma is the most frequent malignancy of the lung in most parts of the world which constitutes about half of the cases.^{4,5} Lung adenocarcinoma is seen mainly in female and non-smokers.⁵ Invasive adenocarcinoma of the lung is histologically classified as: Lepidic, Acinar, Papillary, Micropapillary and Solid patterns with mucin production.² Papillary subtype is applied when more than 75% of the tumor has papillary architecture on histopathology. This subtype comprises about 7.4-12% of pulmonary adenocarcinomas.⁵ Definite subtyping is necessary for precise diagnosis and determination of prognosis.⁵

There are some known mutations and gene

rearrangements in patients with papillary pattern of adenocarcinoma.^{6,7} These genetic aberrations may be the target for future treatments. Herein, we report a young man with papillary predominant subtype of lung adenocarcinoma from the west of Iran.

Case Presentation

A 27-year-old man was referred to the department of surgery with a history of dyspnea for the last three months. He was diagnosed with empyema in another center receiving antibiotics for fifty days. He admitted in our hospital to undergo thoracotomy for further evaluation. The patient had non-productive cough, chest wall pain and exertional dyspnea. In past medical history, he was hospitalized for electrical burns 3 years ago for 5-6 months which multiple debridement and grafting were performed. Family history was unremarkable. On physical examination, vital signs were stable with a respiratory rate of 18/min. Grafted skin in upper and

lower limbs and decreased right lung sounds mainly in basilar portion was noted.

Computer tomography scanning of the chest showed moderate to massive pleural effusion in right hemithorax and a massive consolidation in right middle and lower lobes with air bronchogram suggestive of pneumonia and parapneumonic effusion. Ground glass opacities in right pulmonary apex were also observed. Laboratory data including arterial blood gas were within normal limits, but a leukocytosis and mild anemia (Hemoglobin: 11.3 gr/dL). A chest tube was inserted for the patient. Thoracotomy was performed and specimens were taken from visceral and parietal pleura, pleural peel, superior and inferior lung lobes. The pathology was reported as papillary adenocarcinoma of the lung, moderately differentiated with pleural involvement (Figure 1). Immunohistochemistry (IHC) confirmed the diagnosis which was positive for "Thyroid transcription factor-1 (TTF-1)" (Figure 2) and cytokeratin 7 (Figure 3), weakly positive for cytokeratin 20 and carcinoembryonic antigen and negative for thyroglobulin and calretinin. Written informed consent was obtained from the patient to report the case.

Discussion

Our patient was a young man who was diagnosed with papillary adenocarcinoma of the lung on thoracotomy. In such cases, one should be cautious to rule out mesothelioma with secondary pulmonary involvement and papillary carcinoma of the thyroid (PTC) with lung metastasis. In this case, IHC was compatible with papillary adenocarcinoma. Negativity for calretinin and positivity for CEA (albeit weak) ruled out the mesothelioma. Meanwhile, negativity for thyroglobulin was enough to rule out PTC. IHC positivity for CK7, CK20, and TTF-1 is shown in adenocarcinoma of the lung with strong positivity for CK7.² However, CK20 positivity was not shown by Kuroda and the colleagues.⁸ They have reported a Japanese 72-year-old man with papillary adenocarcinoma whose IHC was positive for CK7, CK19, TTF-1, CEA and surfactant apoprotein A (SP-A) and negative for CK20, estrogen receptor, progesterone receptor, uroplakin III and CA125.⁸ Hano and colleagues have reported papillary adenocarcinoma in a 52-year-old man with "placentoid bullous lesion of the lung". IHC was positive for CAM 5.2, epithelial membrane antigen and pulmonary surfactant apoproteins (detected by PE10 monoclonal antibody).⁹ There is another report of a 59-year-old non-smoking lady with papillary adenocarcinoma of the lung with metastasis to the larynx whose IHC was positive for pulmonary surfactant apoprotein.¹⁰

Papillary adenocarcinoma of the lung may be associated with paraneoplastic syndromes and resection of the tumor can relieve the symptoms. Evans syndrome has been reported as a paraneoplastic syndrome in a 39-year-old non-smoking woman with lung papillary adenocarcinoma. Resection of the tumor resulted incomplete remission of the Evans syndrome and normalizing of laboratory data.⁴ Another woman with papillary adenocarcinoma

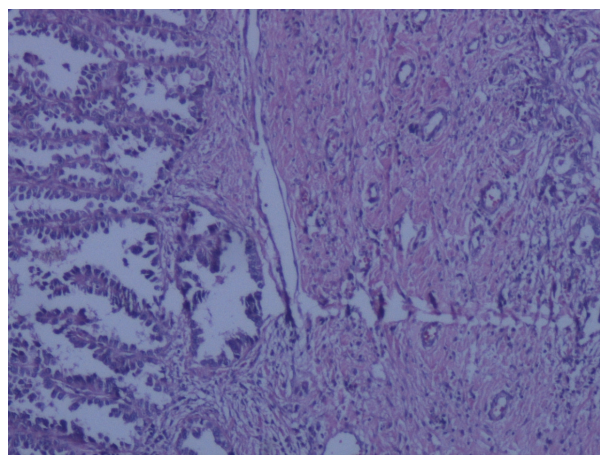


Figure 1: Hematoxylin-Eosin staining showing papillary predominant pattern of lung adenocarcinoma, left side of the field (×100 magnification)

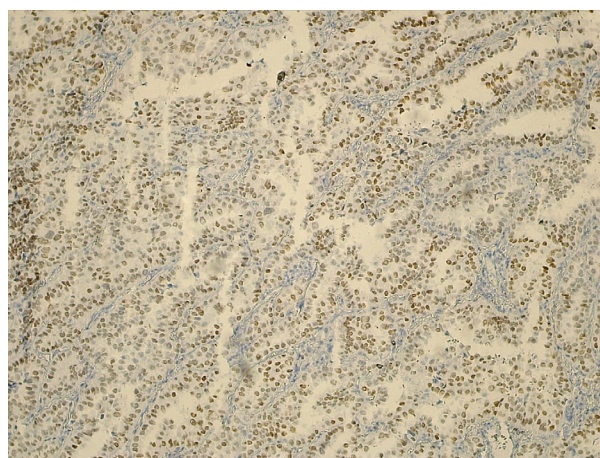


Figure 2: Immunohistochemistry of the papillary lung adenocarcinoma showing TTF-1 positivity, nuclear staining (×100 magnification)

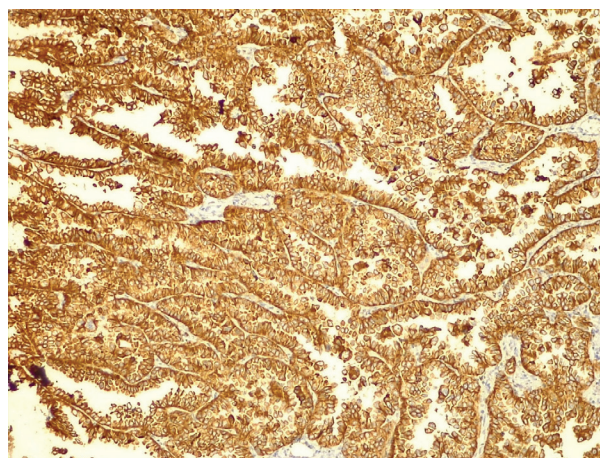


Figure 3: Immunohistochemistry of the papillary lung adenocarcinoma showing CK7 positivity, cytoplasmic staining (×100 magnification)

of the lung showed evidence of preceding autoimmune hemolytic anemia before the diagnosis was made. Again, the hemolytic process subsided following the surgery.¹¹

Salisbury et al. reported a 52-year-old woman with papillary adenocarcinoma with numerous psammoma bodies which was derived from type II pneumocytes. They stated that alveolar cell carcinoma should be considered

as differential diagnosis.¹² There are numerous metastatic sites for papillary lung carcinoma. Choroidal metastasis from pulmonary papillary adenocarcinoma and visual loss is reported in a 40-year-old smoker man from Romania.¹³ A young female has been reported who was presented with cardiac tamponade. The pericardial effusion showed metastatic cells characteristic of papillary tumor of lung origin.¹⁴ Prameela and co-workers reported a 63-year-old man with a papillary carcinoma in the thyroid originated from the lung.¹⁵ Karmakar and colleagues reported two cases of papillary adenocarcinoma of the lung in non-smoker men and emphasized on subtyping to determine prognostic and diagnostic purposes.⁵ A 19-year-old Italian woman with papillary adenocarcinoma of the lung showed rearrangement of EML4-ALK gene by fluorescence in situ hybridization method.⁷ Sakai and colleagues showed two different mutations in tubular and papillary adenocarcinoma of the lung in a patient and emphasized on heterogeneity of the tumors in an individual patient.⁶

Conclusion

Lung cancer with a high rate of mortality needs special attention. There are different subtypes of lung cancer including pulmonary adenocarcinoma. This type of tumor may consist of papillary structures in histopathology architecture. The papillary pattern of lung adenocarcinoma has its own prognosis, cytogenetic abnormalities and demands specific treatment modalities.

Acknowledgment

The authors would like to thank Ms. Elham Shahbazi for providing the data. The authors also would like to thank the “Clinical Research Development Center of Imam Reza Hospital” for consulting services.

Conflict of Interest: None declared.

References

1. Siegel RL, Miller KD, Jemal A. Cancer statistics, 2019. *CA Cancer J Clin.* 2019; 69:7-34. doi: 10.3322/caac.21551. PubMed PMID: 30620402.
2. Tang ER, Schreiner AM, Pua BB. Advances in lung adenocarcinoma classification: a summary of the new international multidisciplinary classification system (IASLC/ATS/ERS). *J Thorac Dis.* 2014; 6:S489-S501. doi: 10.3978/j.issn.2072-1439.2014.09.12. PubMed PMID: 25349701.
3. Amirkhah R, Naderi-Meshkin H, Mirahmadi M, Allahyari A, Sharifi HR. Cancer statistics in Iran: Towards finding priority for prevention and treatment. *Cancer Press.* 2017; 3:27-38.
4. Yu H, Fu R, Wang H, Liu H, Shao Z. Paraneoplastic Evans syndrome in a patient with adenocarcinoma of the lung: A case report. *Thorac Cancer.* 2017;8:57-60. doi:10.1111/1759-7714.12398. PubMed PMID: 28055149.
5. Karmakar S, Nath A, Neyaz Z, Agarwal V, Ahsan S. Primary papillary adenocarcinoma of the lung: Report of two cases. *Lung India.* 2017; 34:299-302. doi: 10.4103/lungindia.lungindia_467_15. PubMed PMID: 28474664.
6. Sakai H, Saji H, Kimura H, Tsuda M, Wakiyama Y, Miyazawa T, et al. Different EGFR gene mutations in two patients with synchronous multiple lung cancers: A case report. *Thorac Cancer.* 2018; 9(1):189-192. doi:10.1111/1759-7714.12554. PubMed PMID: 29090842.
7. Polo V, Zago G, Frega S, Canova F, Bonanno L, Favaretto A, et al. Non-Small Cell Lung Cancer in a Very Young Woman: A Case Report and Critical Review of the Literature. *Am J Case Rep.* 2015; 16:782-789. doi:10.12659/ajcr.894426. PubMed PMID: 26525068.
8. Kuroda N, Hamauzu T, Toi M, Yamaoka K, Miyazaki E, Hiroi M, et al. Pulmonary adenocarcinoma with micropapillary component: an immunohistochemical study. *Case report. APMIS.* 2005; 113:550-4. doi: 10.1111/j.1600-0463.2005.apm_151.x. PubMed PMID: 16086826.
9. Hano H, Cui S, Ushigome S, Kotajima F, Sato T. Papillary adenocarcinoma arising in placental bullous lesion of the lung: report of a case with immunohistochemical study. *Arch Pathol Lab Med.* 1998; 122:915-9. PubMed PMID: 9786354.
10. Ogata H, Ebihara S, Mukai K, Mashima K, Saikawa M, Asai M, et al. Laryngeal metastasis from a pulmonary papillary adenocarcinoma: a case report. *Jpn J Clin Oncol.* 1993; 23:199-203. PubMed PMID: 8350493.
11. Xing L, Wang H, Qu W, Fang F, Dong Q, Shao Z. Lung papillary adenocarcinoma complicated with paraneoplastic autoimmune hemolytic anemia: A case report. *Thorac Cancer.* 2014;5(1):82-84. doi:10.1111/1759-7714.12007. PubMed PMID: 26766978.
12. Salisbury JR, Darby AJ, Whimster WF. Papillary adenocarcinoma of lung with psammoma bodies: report of a case derived from type II pneumocytes. *Histopathology.* 1986; 10:877-84. doi: 10.1111/j.1365-2559.1986.tb02585.x. PubMed PMID: 3758952.
13. Turliuc MD, Sava A, Dumitrescu GF, Cucu A, Eşanu A, Tudorache C, et al. Right visual loss due to choroidal metastasis of a papillary adenocarcinoma of the lung: a case report. *Rom J Morphol Embryol.* 2015;56:1173-7. PubMed PMID: 26662155.
14. Gochhait D, Sreerekha J, Rangarajan V, Siddaraju N, Govindarajalou R, Penumadu P. Cardiac tamponade as an initial presentation of papillary carcinoma with psammoma bodies and intranuclear grooves-A diagnostic dilemma. *Diagn Cytopathol.* 2019;47:927-9. doi: 10.1002/dc.24215. PubMed PMID: 31120622.
15. Prameela CG, Ravind R, Sruthi K. Nonthyroidal metastatic lesion in thyroid: A missed diagnosis and a lesson learnt. *J Can Res Ther.* 2019;15:665-8. doi: 10.4103/jcrt.JCRT_1043_16. PubMed PMID: 31169237.