



## CASE REPORT

# Submandibular Hemangioma with Cardiorespiratory Arrest in an Infant

Jose Arriola-Montenegro<sup>1</sup>, MD; Pedro Guerra-Canchari<sup>2,3\*</sup>, Patricia Cabanillas-Lozada<sup>4</sup>, MD; Pamela Contreras-Chavez<sup>5</sup>, MD; Liliana Arriola-Montenegro<sup>6</sup>, MD; Karina Ordaya-Gonzales<sup>7</sup>, MD; Marilyn Sabogal-Deza<sup>8</sup>, MD

<sup>1</sup>Sociedad Nacional de Capacitación, Lima - Perú

<sup>2</sup>Universidad Nacional Mayor de San Marcos, Facultad de Medicina, Lima - Peru

<sup>3</sup>Sociedad Científica de San Fernando, Lima – Peru

<sup>4</sup>Universidad Nacional de Trujillo, Trujillo – Peru

<sup>5</sup>Advocate Illinois Masonic Medical Center, Illinois – US

<sup>6</sup>Universidad Peruana de Ciencias Aplicadas, Lima - Peru

<sup>7</sup>Policlinico Naval de San Borja, Lima – Peru

<sup>8</sup>Universidad Nacional de Trujillo, Trujillo - Peru

## ARTICLE INFO

### Article History:

Received: 12.05.2020

Accepted: 18.07.2020

### Keywords:

Submandibular gland neoplasms

Hemangioma

Infant

### \*Corresponding author:

Pedro Guerra-Canchari,  
Jr. Chinchá 398, San Martín de Porres,  
Lima – Peru

Tel: +51-995601084

Email: [pguerrac100@gmail.com](mailto:pguerrac100@gmail.com),  
[pedro.guerra2@unmsm.edu.pe](mailto:pedro.guerra2@unmsm.edu.pe)

## ABSTRACT

Hemangiomas are defined as soft tissue lesions in the maxillofacial or oral region. Hemangiomas of salivary glands constitute 30% of the non-epithelial tumors in major salivary glands. Benign tumors in salivary glands are located 85% in parotid gland and 13% in submandibular gland. We present a case of submandibular hemangioma in an infant patient that had some complications and a challenging diagnosis. A 3- month-old female patient presented a giant hemangioma located in the submandibular, preauricular and right malar region with purplish color that during hospitalization had a cardiorespiratory arrest as a severe complication of the disease.

Please cite this article as: Arriola-Montenegro J, Guerra-Canchari P, Cabanillas-Lozada P, Contreras-Chavez P, Arriola-Montenegro L, Ordaya-Gonzales K, Sabogal-Deza M. Submandibular Hemangioma with Cardiorespiratory Arrest in an Infant. IJBC 2020; 12(3): 104-107.

## Introduction

Hemangiomas are defined as soft tissue lesions in the maxillofacial or oral region, hemangiomas of salivary glands constitute 30%, of the most common non-epithelial tumors, in the major salivary glands.<sup>1</sup> Benign tumors represent an 85% of tumors in parotid gland, 13% in submandibular gland, 1% in sublingual gland and 1% in minor salivary glands; this also represents distribution of hemangiomas in salivary glands.<sup>2</sup> It is difficult to determine the incidence for minor salivary glands due to lack of biopsies made, the diffuse anatomic distribution of these glands and difficulties differentiating origin from affected tissue between minor salivary gland and connective tissue that surrounds it.<sup>3</sup> Hemangiomas account for the majority of all salivary tumors in children

younger than 1 year with a 90% prevalence, and have typically an initial rapid growing during the first 3 months of life followed by a second growth that can occur up to 4 and 6 months of age.<sup>4</sup> The submandibular area as we see is a rare location for hemangiomas, but also it has been a challenge to diagnose hemangiomas in submandibular gland because this location is related with other pathologies that could simulate this disease, like sialadenitis, abscess or a cyst.<sup>5</sup> Also a hemangioma could exist with some benign pathology at the same time, like hemangioma with multiple phleboliths that could make it harder to diagnose.<sup>6</sup>

We present a case of submandibular hemangioma in pediatric patient that had some complications and its diagnosis was challenging.

### Case Report

A 3-month-old female patient presented with a red-wine colored macular lesion at birth in the right preauricular region of 1 cm, which progressively increased volume and size.

A month before admission (January 2019), the patient was evaluated by the dermatology department, and on biopsy presence of the hemangioma was confirmed (Figure 1). A soft tissue ultrasound showed evidence compatible with an extensive submandibular glandular hemangioma with high-flow arterial compromise and high resistance, in addition to multiple arteriovenous shunts.

The hemangioma continued to grow, and the patient presented episodes of demanding dry cough and nasal discharge one week before being admitted to the hospital. She received treatment with antipyretics and antibiotics for five days. Two days before admission, the hemangioma continued to increase in volume and size, and the patient experienced shortness of breath during sleep with deep inspiration, cough associated with difficulty in breastfeeding and feverish sensation for which she came to the emergency department at Belen Hospital in Trujillo, Peru.

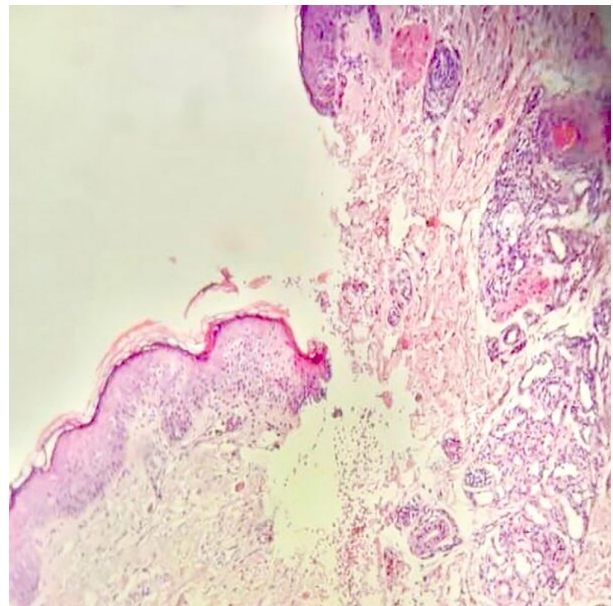
Upon admission, the patient presented with mild respiratory distress at rest and difficulty during lactation. They described a 15cm long by 7.5cm wide hemangioma located in the submandibular, preauricular and right malar region (Figure 2) with purplish color, telangiectasias disseminated inside, not mobile nor painful on palpation. In addition, the presence of another 3 cm of diameter hemangioma at the midline of the upper third of the left hemithorax. Treatment with propranolol is started to decrease the size of the hemangioma.

A chest x-ray showed airway displacement, and the otorhinolaryngology service suggested endotracheal intubation, verifying displacement of the trachea. The patient is transferred to the ICU and is started in mechanical ventilation. She experienced a fever peak, so laboratory tests were requested, including blood and urine culture. A globular package is transfused due to a drop in hemoglobin and antibiotic treatment is started due to a pathological urine test.

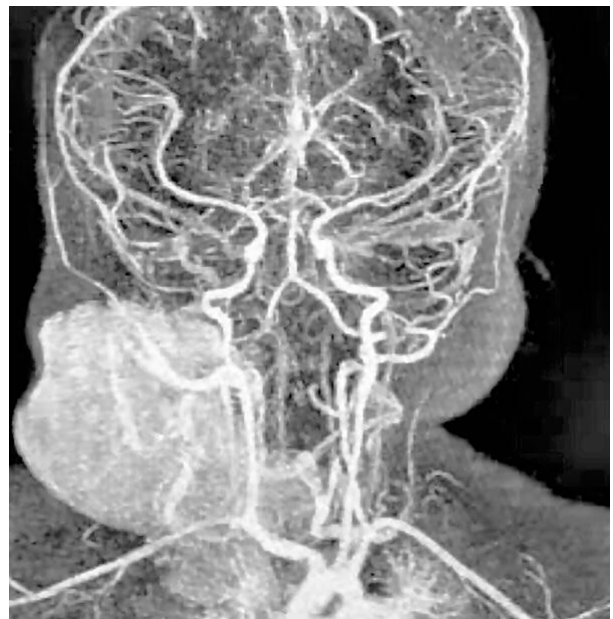
During hospitalization, she presented a desaturation episode attributed to the mass effect produced by the hemangioma. On physical examination, a decrease in vesicular murmur is evident in the right hemithorax, expiratory wheezing, and subcrepits. Control x-ray showed evidence of a consolidation pattern in the right hemithorax. The patient started double antibiotic coverage, atenolol instead of propranolol and corticosteroid therapy.

On the fourth day of hospitalization, the patient presented cardiorespiratory arrest. Treatment with captopril is started orally due to increased blood pressure. Respiratory symptoms were clinically stationary but had progressive reduction of the hemangioma dimensions. On the ninth day, she presented a feverish peak and got switched to a broad-spectrum antibiotic coverage with gradual suspension of corticosteroid.

During the tenth day of hospitalization, the patient



**Figure 1:** Biopsy of the Submandibular Hemangioma showing vascular proliferations at a depth of the surface epithelium and displaced salivary gland structures (hematoxylin-eosin). (January; 2019)



**Figure 2:** Cerebral angiography showing presence of a 15cm long by 7.5 cm wide hemangioma located in the submandibular, preauricular and the right malar region. (February; 2019)

was extubated, tolerating spontaneous ventilation with mild stridor and aphonia, nebulized with adrenaline and restarting corticosteroid therapy. The patient was transferred to another hospital where she continued with antibiotic treatment, atenolol and captopril with favorable evolution and reduction of the hemangioma. She is discharged with oral antibiotic treatment and indication of outpatient center control.

The patient continues with the follow-up in the other hospital until today, on May 2020 she does not have any complication or recurrence of the tumor.

### Informed Consent

We got an informed consent by the infant's parents

## Discussion

Salivary glands are frequently located in the parotid gland which is why the majority of neoplastic processes and hemangiomas are studied at that level.<sup>7, 8</sup> Hemangiomas are mesenchymal benign tumors and usually presents as a unilateral hard mass.<sup>7</sup> Within the parotid, it has been described that 5% of benign tumors from this gland are hemangiomas which is considered to be a rare tumor type.<sup>8</sup> Diagnosis can be challenging in this type of tumors, however it gets even difficult and rare when it presents at the sublingual area, that usually compromise the upper airway due to late diagnosis.<sup>9</sup>

Less than 20 submandibular benign tumor cases have been reported in literature, between removable and biopsied lesions, it was found that hemangiomas represented 1.7% of the cases.<sup>10</sup> Clinical course varies, and the majority presents only with pain or minor symptoms,<sup>10</sup> but can also present with recurrent upper respiratory infections<sup>11</sup> or severe complications such as described in our case.

The diagnosis can be arduous in this type of benign tumors especially due to their localization.<sup>12</sup> Previous studies in parotid glands show the efficacy of doppler ultrasound as first diagnostic step, followed by MRI-imaging where further details can be seen.<sup>13</sup> In our case, ultrasound was highly beneficial to the diagnosis of hemangioma.

Some differential diagnosis can have similar clinical presentations such as hemangioendotheliomas,<sup>14, 15</sup> these are benign tumors with the same origin as hemangiomas, but has chronic lesions and syndromes associated.<sup>14</sup> The presentation of this tumor is very rare and usually grows within the submandibular triangle, where also pleomorphic adenomas can be located.<sup>16</sup> In our case, the submandibular hemangioma was found in the submandibular triangle as well. Hemangiomas can grow extensively and it can generate severe dysphagia,<sup>17</sup> however this compromise may become worse with acute respiratory distress and cardiac arrest due to severe respiratory failure as happened to our patient.

Treatment has changed recently, according to a 40 years cohort study, steroids and surgery have been well-tolerated by patients with excellent response and very few adverse effects.<sup>18</sup> Nowadays, majority of hospitals follows a regimen based on oral propranolol which is usually well tolerated as well.<sup>19</sup>

In our case our patient followed this last regimen and up to this date there has not been any issues so far.

As a conclusion; our patient had a hemangioma in a very rare location with few previous reports. She had a severe complication managed in the hospital with no recurrences or complications until today.

**Conflict of Interest:** None declared.

## References

- Childers ELB, Furlong MA, Fanburg-smith JC. Hemangioma of the salivary gland: A study of ten cases of a rarely biopsied/ excised lesion. *Ann Diagn Pathol.* 2002;6: 339-44. doi: 10.1053/adpa.2002.36662.

- PubMed PMID: 12478482.
- Carlson ER, Ord RA. Benign pediatric salivary gland lesions. *Oral Maxillofac Surg Clin North Am.* 2016;28(1):67–81. doi: 10.1016/j.coms.2015.07.004.
- Ponniah I, Sureshkumar P, Karunakaran K, Shankar KA, Kumaran MG, et al. Hemangioma in minor salivary gland: real o illusion. *Diagn Pathol.* 2006; 17: 1–21. doi: 10.1186/1746-1596-1-21.
- Mehta D, Willging JP. Pediatric salivary gland lesions. *Semin Pediatr Surg.* 2006; 15(2):76–84. doi: 10.1053/j.sempedsurg.2006.02.004. PubMed PMID: 16616310.
- Cho JH, Nam IC, Park JO, Kim MS, Sun DI. Clinical and radiologic features of submandibular triangle hemangioma. *J Craniofac Surg.* 2012;23(4):1067–70. doi: 10.1097/SCS.0b013e31824e6cbf. PubMed PMID: 22777461.
- Chen Bo. Cavernous hemangioma with multiple phleboliths of the parotid gland in adult masquerading assialolithiasis. *Int J Clin Exp Med.* 2017;10(7):11097-100.
- Lennon P, Silvera VM, Perez-Atayde A, Cunningham MJ, Rahbar R. Disorders and tumors of the salivary glands in children. *Otolaryngol Clin North Am.* 2015; 48(1):153-73. doi: 10.1016/j.otc.2014.09.011.
- Lee DH, Yoon TM, Lee JK, Lim SC. Clinical features of pediatric parotid tumors: 10-year experience of a single institute. *Acta Otolaryngol.* 2013;133(11):1213–8. doi: 10.3109/00016489.2013.822554.
- Pérez-Macias Martín O, Peral Cagigal B, Madrigal Rubiales B, Blanco Sanfrutos S, Redondo González LM, Verrier Hernández A. Hemangioma cavernoso sublingual. *Rev Esp Cir Oral Maxilofac.* 2013; 35(1): 44–6. doi: 0.1016/j.maxilo.2011.10.004.
- Kumar S, Gupta AK, Bakshi J. Submandibular gland hemangioma: clinicopathologic features and a review of the literature. *Ear Nose Throat J.* 2010; 89(11): E14–E7. doi: 10.1177/014556131008901105. PubMed PMID: 21086266.
- Lee HJ, Kwon OJ, Lee JS, Park JJ. A case of cavernous hemangioma in the submandibular gland: a review of clinicoradiologic features and treatment methods. *Korean J Otorhinolaryngol Head Neck Surg.* 2015; 58(10):699-703. doi: 10.3342/kjorl-hns.2015.58.10.699.
- Wallace AN, Vyhmeister R, Kamran M, Teeffey SA. Submandibular venous hemangioma: Case report and review of the literature. *J Clin Ultrasound.* 2015; 43(8):516–9. doi: 10.1002/jcu.22258.
- Weber FC, Greene AK, Adams DM, Liang MG, Alomari MH, Voss SD. Role of imaging in the diagnosis of parotid infantile hemangiomas. *Int J Pediatr Otorhinolaryngol.* 2017; 102:61–6. doi: 10.1016/j.ijporl.2017.08.035.
- Kumar M, Acharya S, Pai K, Kumar V, Thotan SP. Unusual neoplasm on the hard palate of a child: a case report. *J Med Case Reports.* 2017; 11(1). doi: 10.1186/s13256-017-1321-4.
- Leen SLS, Clarke PM, Chapman J, Fisher C, Thway K. Composite hemangioendothelioma of the submandibular region. *Head Neck Pathol.*

- 2015; 9(4):519–24. doi: 10.1007/s12105-015-0612-6. PubMed PMID: 25666464. PubMed Central PMCID: PMC4651927.
16. Ozturk M, Sari F, Erdogan S, Mutlu F. Submandibular cystic cavernous hemangioma: an unusual presentation. *J Craniofac Surg*. 2013; 24(5):1856–7. doi: 10.1097/SCS.0b013e3182997c65. PubMed PMID: 24036799.
  17. Azadarmaki R, Then MT, Walia R, Lango MN. Cavernous hemangioma of the submandibular gland with parapharyngeal extension in an adult: Case report. *Ear Nose Throat J*. 2016; 95(2): E11–E3. doi: 10.1177/014556131609500204.
  18. Sinno H, Thibaudeau S, Coughlin R, Chitte S, Williams B. Management of infantile parotid gland hemangiomas: a 40-year experience. *Plast Reconstr Surg*. 2010; 125(1):265–73. doi: 10.1097/PRS.0b013e3181c2a55a.
  19. Li G, Xu DP, Sun HL, Cheng C, Liu ZM, Xi SL, Wang XK. Oral propranolol for parotid infantile hemangiomas *J Craniofac Surg*. 2015;26(2): 438–40. doi: 10.1097/SCS.0000000000001335.