

## PHOTO CLINIC

# Imatinib Mesylate-Induced Periorbital Edema in a Child with Chronic Myeloid Leukemia

Samin Alavi<sup>1</sup>, Azin Ashnagar<sup>2\*</sup>

<sup>1</sup>Pediatric Congenital Hematologic Disorders Research Center, Shahid Beheshti University of Medical Sciences, Tehran, Iran.

<sup>2</sup>Ophthalmologist, Zanjan University of Medical Sciences, Zanjan, Iran

## ARTICLE INFO

### Article History:

Received: 27.11.2019

Accepted: 28.12.2019

### \*Corresponding author:

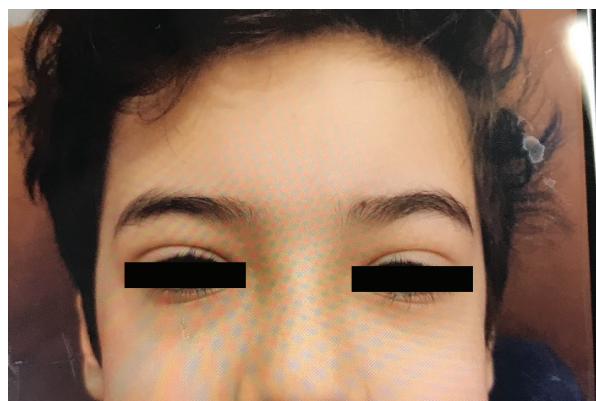
Azin Ashnagar,  
Ophthalmologist, Zanjan University  
of Medical Sciences, Zanjan, Iran  
**Tel:** +98 24 35277741  
**Fax:** +98 24 35231801  
**Email:** [azin\\_ashnagar2@yahoo.com](mailto:azin_ashnagar2@yahoo.com)

Please cite this article as: Alavi S, Ashnagar A. Imatinib Mesylate-Induced Periorbital Edema in a Child with Chronic Myeloid Leukemia. IJBC 2020; 12(2): 72-73.

A 10-year-old boy was referred to the pediatric oncology clinic with hyperleukocytosis and severe thrombocytosis after experiencing a mass in his left mandible for two weeks. On physical examination, he was pale and found to have a large spleen. Blood tests showed white blood cell count ( $250 \times 10^9/L$ ), hemoglobin 8.2 g/dL; and platelet count of  $1500 \times 10^9/L$ . After initial work-up, bone marrow aspiration and biopsy were performed which revealed a hypercellular marrow positive for t (9,22) in cytogenetic study which was consistent with chronic myeloid leukemia (CML) in the chronic phase (CML-CP). RT-PCR showed BCR-ABL1, Mbc (P210) with mRNA transcript level of 17.2% in quantitative study at the time of diagnosis. He was scheduled to start imatinib 340 mg/m<sup>2</sup> (300 mg/day).

The blood counts started to be normalized within two weeks; however, he complained of severe periorbital puffiness and a vague feeling of heavy droopy eyelids during this period (Figure 1). The patient developed thrombocytopenia and then mild neutropenia and was recommended to stop taking imatinib mesylate. Following cessation of imatinib, bilateral periorbital edema and also muscle cramps were ameliorated. The medication was restarted for the patient after 2-3 weeks with a lower dose, while the above-mentioned signs and symptoms did not recur.

Imatinib mesylate (Gleevec®) is a well-established pharmacological treatment for all phases of CML. Edema is a relatively common side effect in imatinib therapy.



**Figure 1:** Periorbital edema in a child on Imatinib Mesylate

According to the literature, the periocular region is reported as the most common site of edema present in 47–70% of patients taking imatinib.<sup>1</sup> The most accepted mechanism underlying imatinib-induced periorbital edema is inhibition of platelet-derived growth factor receptor (PDGFR) signaling by the drug which results in increased capillary permeability and extravasation of fluid.<sup>2</sup> Inhibition of PDGFRs on dermal dendrocytes has also been suggested as the causative role of periorbital edema by imatinib. The dense collagen tissue of the orbital septum and poorly developed lymphatic system of this region predisposes it to the development of edema.<sup>3</sup>

In a retrospective case series, ocular side effects of 104 patients on imatinib mesylate from Oregon Health and

Science University's Cancer Center has been described. Seventy-three (70%) of the patients developed periorbital edema and 19 patients (18%) developed epiphora after receiving imatinib mesylate with average doses. Periorbital edema occurred an average of  $68 \pm 48$  days after initiation of therapy.<sup>4</sup> However, the edema in our patient occurred soon after starting imatinib.

Periorbital edema secondary to imatinib is usually mild to moderate and can be managed conservatively. Severe cases of periorbital edema have been treated by prescribing a low-salt diet, topical 1% hydrocortisone, 0.25% topical phenylephrine or diuretics. It should be emphasized that even severe periorbital edema is not an indication for cessation of treatment with imatinib.<sup>5</sup> However, recurrence of significant edema often does not occur upon short periods of discontinuation of imatinib therapy and because of the risk of relapse, it is highly recommended that imatinib therapy be continued in all patients with CML in complete molecular response.<sup>6</sup>

Our patient also complained of serious muscle cramps in both legs. Again, discontinuation of imatinib due to myelotoxicity resulted in disappearance of the symptoms. It is assumed that the mechanism behind it must have been intramuscular edema. There is a report of a 35-year-old man who developed pain in both thighs, headache and sweating, 11 days after administration of 600 mg imatinib as daily dose. His physical examination revealed swelling of both thighs. MRI was suggestive of the presence of intramuscular edema. After ceasing imatinib, the muscle pain and swelling of both thighs decreased with a concomitant decrease in the CRP and CK levels. In that case, imatinib was restarted at a dose of 400 mg per day without recurrence of intramuscular edema at the time of the last follow-up.<sup>7</sup>

It is stressed that oncologists keep in mind edema as one of the most common adverse effects of imatinib occurring in more than 50% of the patients. It is dose-related, frequently involving the periorbital region or lower extremities.<sup>8</sup>

**Conflict of Interest:** None declared.

## References

1. McClelland CM, Harocopos GJ, Custer PL. Periorbital edema secondary to imatinib mesylate. *Clin Ophthalmol*. 2010;4:427-31.doi: 10.2147/opth.s8521. PubMed PMID: 20505834. PubMed Central PMCID: PMC2874269.
2. Pietras K, Östman A, Sjöquist M, Buchdunger E, Reed RK, Heldin C-H, et al. Inhibition of platelet-derived growth factor receptors reduces interstitial hypertension and increases transcapillary transport in tumors. *Cancer research*. 2001;61(7):2929-34. PubMed PMID: 11306470.
3. Esmali B, Prieto VG, Butler CE, Kim SK, Ahmadi MA, Kantarjian HM, et al. Severe periorbital edema secondary to STI571 (Gleevec). *Cancer*. 2002;95(4):881-7.doi: 10.1002/cncr.10729. PubMed PMID: 12209733.
4. Fraunfelder FW, Solomon J, Druker BJ, Esmali B, Kuyl J. Ocular side-effects associated with imatinib mesylate (Gleevec®). *J Ocul Pharmacol Ther*. 2003;19(4):371-5.doi: 10.1089/108076803322279426. PubMed PMID: 12964961.
5. Deininger MW, O'Brien SG, Ford JM, Druker BJ. Practical management of patients with chronic myeloid leukemia receiving imatinib. *J Clin Oncol*. 2003;21(8):1637-47.doi: 10.1200/JCO.2003.11.143. PubMed PMID: 12668652.
6. Druker BJ, Guilhot F, O'Brien SG, Gathmann I, Kantarjian H, Gattermann N, et al. Five-year follow-up of patients receiving imatinib for chronic myeloid leukemia. *New England Journal of Medicine*. 2006;355(23):2408-17.doi: 10.1056/NEJMoa062867. PubMed PMID: 17151364.
7. Shimazaki C, Ochiai N, Uchida R, Fuchida S, Okano A, Ashihara E, et al. Intramuscular edema as a complication of treatment with imatinib. *Leukemia*. 2003;17(4):804-5.doi: 10.1038/sj.leu.2402868. PubMed PMID: 12682642.
8. Kusumi E, Arakawa A, Kami M, Kato D, Yuji K, Kishi Y, et al. Visual disturbance due to retinal edema as a complication of imatinib. *Leukemia*. 2004;18(6):1138-9.