

CASE REPORT

Bilateral Multifocal Mesenchymal Hamartoma of Chest Wall Since Neonatal Period: A Case Report

Mitra Khalili¹, Mehrdad Izadi², Khashayar Atqiaee³, Mehdi Gholamzadeh Baeis⁴, Saran lotfollahzadeh², Maryam Panahi^{2*}

¹Department of Radiology, Shahid Beheshti University of Medical Sciences, Tehran, Iran

²Pediatric Surgery Research Center, Shahid Beheshti University of Medical Sciences, Tehran, Iran

³Department of Pediatric Surgery, School of Medicine, Ardabil University of Medical Sciences, Ardabil, Iran

⁴Department of Radiology, Imam Hossein Hospital, Shahid Beheshti University of Medical Sciences, Tehran, Iran

ARTICLE INFO

Article History:

Received: 25.10.2020

Accepted: 12.01.2021

Keywords:

Hamartoma
Mesenchymal
Bilateral
Chest wall
Benign
Neonate

*Corresponding author:

Maryam Panahi,
Mofid children's Hospital, Shariati
Avenue, Postal code: 15468-15514,
Tehran, Iran
Tel: +98-21-22227021
Fax: +98-21-22220254
Email: maryam.neda.panahi@gmail.com

ABSTRACT

Mesenchymal hamartoma of the chest wall is a rare benign tumor found in infants and young children. We present a male neonate with bilateral multifocal mesenchymal hamartoma of the chest wall since birth causing deformity of the chest wall and respiratory symptoms. Mesenchymal hamartoma is often unilateral and solitary, but multifocality could be expected in the absence of the malignancy. Mesenchymal hamartoma of the chest wall in infants should always be considered as the differential diagnosis of the chest wall masses in young children.

Please cite this article as: Khalili M, Izadi M, Atqiaee K, Gholamzadeh Baeis M, lotfollahzadeh S, Panahi M. Bilateral Multifocal Mesenchymal Hamartoma of Chest Wall Since Neonatal Period: A Case Report. IJBC 2021; 13(1): 26-28.

Introduction

Chest wall mesenchymal hamartoma is a benign neoplasm of the infants. The lesions are generally well circumscribed emanating from the chest wall (one or several ribs) which compress the adjacent thoracic structures. Typically, respiratory symptoms at presentation are dominant. Parents may also notice a palpable mass.¹ Male to female ratio is 1.6:1. It is reported that 80% of the cases were diagnosed prenatally or within the first six months of the life.² Mesenchymal hamartoma of the chest wall could be mistaken with a malignant tumor because of its clinical presentation and microscopic features; though might overlap with malignant soft tissue or bone tumors.³

Case Presentation

A 10-day-old boy neonate with a firm, non-tender, non-

mobile mass on right upper anterior chest wall with thoracic wall asymmetry at birth undertook for further evaluation. A biopsy was performed which was in favor of mesenchymal hamartoma with benign components. Due to lack of respiratory symptoms, close follow-up was decided for him. The patient gradually developed respiratory symptoms; while overgrowth of the mass was observed clinically. He was admitted to Mofid Children's Hospital, Tehran, Iran at the age of 5 months. On physical examination, tachypnea and failure to thrive was noticeable (figure 1).

Chest-x-ray at presentation showed a large well-defined soft tissue mass in the right hemithorax with deformity of the adjacent ribs and mediastinal shift to the contralateral hemithorax (figure 2). CT scan of the chest revealed a large lobulated mass measuring 105×92×66 mm containing

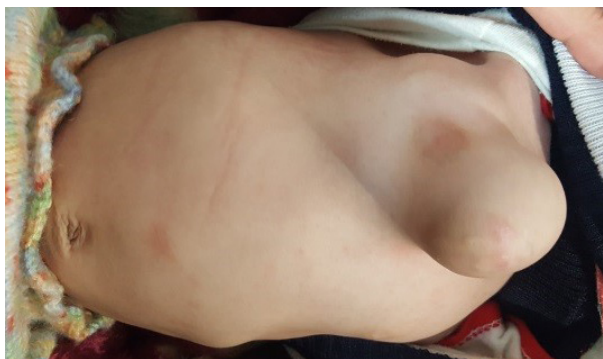

Figure 1: A large well-defined soft tissue mass in right side of the chest wall.

several hemorrhagic cysts with calcified matrix and ossified septa (figure 3A) without significant enhancement (figure 3B). The mass had both intra- and extrathoracic components originated from the fifth rib with compression on right pulmonary parenchyma, shifting the mediastinum to the left hemithorax, resulting in levoscoliosis and right hemithorax deformity. Another smaller chest wall mass with the same appearance medial to the eighth rib in the left side was also observed (figure 3C). The patient was scheduled for surgery. Extrathoracic component was removed and debulking of the intrathoracic remnants was proceeded. Histopathology was consistent with multiple hypercellular cartilaginous lobules admixed with benign spindle cell proliferation with a sharp interface alongside with multifocal endochondral ossification compatible with mesenchymal hamartoma. The infant had an uneventful course following surgery with no evidence of regrowth of the mass during six months of the follow up.

Discussion

Mesenchymal hamartoma of the chest wall is a rare benign neoplasm which was first described by Nash and Stout in 1961.^{4,5} Typically, it arises as a solitary lesion from the central portions of one or several ribs.¹ Mesenchymal hamartoma of the chest wall is usually unilateral;^{4,5} However, there were two large chest wall masses located bilaterally in our patient which is very rare.^{4,6}

Mesenchymal hamartoma can have variable manifestations depending on its size, from completely

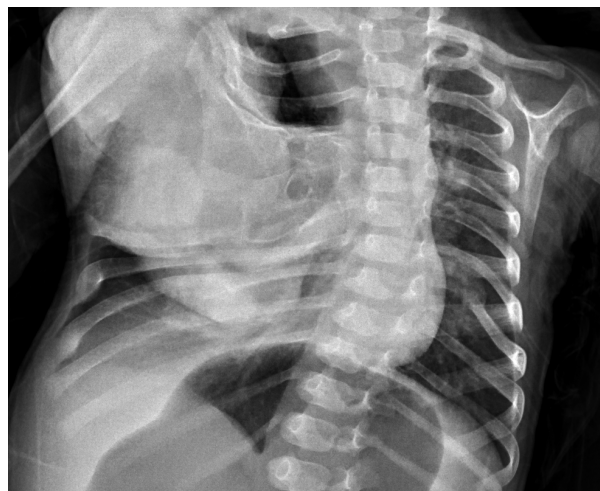

Figure 2: Chest-x-ray shows a large well-defined soft tissue mass in chest wall in right side with deformity of the adjacent ribs and mediastinal shift to the left.

asymptomatic tumors to those causing severe respiratory distress.⁴ In our patient, scoliosis and chest wall deformity were significant due to its large size.

Imaging studies could be helpful for diagnosis; although not exactly diagnostic of mesenchymal hamartoma, since they may possibly resemble malignant lesions.⁷ Ewing sarcoma and PNET can present with similar manifestations to mesenchymal hamartoma, so accurate diagnosis of mesenchymal hamartoma as a benign tumor is of utmost importance for appropriate management.⁸

In our case, according to CT findings (mineralization and hemorrhagic cysts) and patient age as a neonate, mesenchymal hamartoma of the chest wall was considered which was confirmed by the pathology report.

In review of articles published in recent years during 2019-2020, three other neonatal cases of bilateral multifocal mesenchymal hamartoma were reported; one of them was a neonate without severe respiratory symptoms at birth with a mass on his back, with involvement of multiple ribs in his CXR which underwent surgery later in infancy due to significant increase in size and extension to spinal canal.⁹ The other case was a neonate with a chest wall mass detected during prenatal ultrasound study with mild respiratory distress at birth in whom thoracotomy and rib excision was performed on 29 days of age.¹⁰ The third case

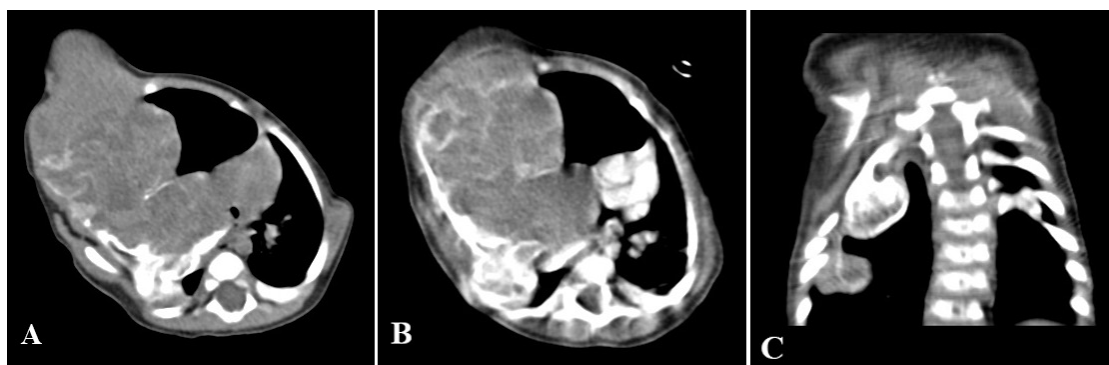


Figure 3: A) Axial CT-scan without contrast demonstrates a large lobulated mass containing several hemorrhagic cysts with calcified matrix and ossified septa. B) Axial CT with contrast demonstrates the large lobulated mass without significant enhancement. C) Coronal CT-section without contrast demonstrates bilateral involvement of the chest wall. Note the smaller mass with the same appearance medial to the eighth rib in right side

was a preterm neonate with respiratory distress intubated soon after birth. There was a large mass in his upper chest wall with tracheobronchial narrowing leading to thoracotomy and excision of the mass and involved ribs.¹¹

Conclusion

Mesenchymal hamartoma of the chest wall is often unilateral and solitary, but bilateral multifocal cases are being reported increasingly. Mesenchymal hamartoma should be considered as differential diagnosis of the chest wall masses specifically in neonates and young infants.

Conflict of Interest: None declared.

References

- Groom KR, Murphey MD, Howard LM, Lonergan GJ, Rosado-De-Christenson ML, Torop AH. Mesenchymal hamartoma of the chest wall: radiologic manifestations with emphasis on cross-sectional imaging and histopathologic comparison. *Radiology*. 2002;222(1):205-11. doi: 10.1148/radiol.2221010522. PubMed PMID: 11756727.
- Haase R, Merkel N, Milzsch M, Lieser U, Sauer H, Hinz L, et al. Mesenchymal chest wall hamartoma-surgery is preferred. *Arch Perinat Med*. 2007;13:56-61.
- Alfaraidi M, Alaradati H, Mamoun I, Mohammed S. Bilateral Mesenchymal Hamartoma of the Chest Wall in a 3-Month-Old Boy: A Case Report and Review of the Literature. *Case reports in pathology*. 2017;2017:2876342-.doi: 10.1155/2017/2876342. PubMed PMID: 28900550.
- Altaner S, Yoruk Y, Bilgi S, Puyan FO, Doganay L, Kutlu K. Multifocal mesenchymal hamartoma of the chest wall. *Respirology*. 2006;11(3):334-8. doi: 10.1111/j.1440-1843.2006.00853.x. PubMed PMID: 16635095.
- Pawel BR, Crombleholme TM. Mesenchymal hamartoma of the chest wall. *Pediatr Surg Int*. 2006;22(4):398-400. doi: 10.1007/s00383-005-1607-2. PubMed PMID: 16331523.
- Li R, Kelly D, Siegal GP. Bilateral mesenchymal hamartoma of the chest wall in an infant boy. *Fetal Pediatr Pathol*. 2012;31(6):415-22. doi: 10.3109/15513815.2012.659412. PubMed PMID: 22506929.
- Lisle DA, Ault DJ, Earwaker JW. Mesenchymal hamartoma of the chest wall in infants: report of three cases and literature review. *Australas Radiol*. 2003;47(1):78-82. doi: 10.1046/j.1440-1673.2003.01111.x. PubMed PMID: 12581063.
- Groom KR, Murphey MD, Howard LM, Lonergan GJ, Rosado-de-Christenson ML, Torop AH. Mesenchymal Hamartoma of the Chest Wall: Radiologic Manifestations with Emphasis on Cross-sectional Imaging and Histopathologic Comparison. *Radiology*. 2002;222(1):205-11.
- Özkale Yavuz Ö, Özcan HN, Gökçe Çınar H, Oğuz B, Haliloğlu M. Multifocal mesenchymal hamartoma of the chest wall in a newborn. *Turkish Journal of Pediatrics*. 2019 1;61(6).
- Sheidaei S, Ghasemi M, Mousavi SA. Prenatal chest wall mesenchymal hamartoma: a case report and review of the literature. *J Matern Fetal Neonatal Med*. 2020; 25:1-3.
- Swaminathan A, Taylor K, Ramaswamy M, Calder A, McHugh K, Muthialu N, Mok Q. Life-threatening mesenchymal hamartoma of the chest wall in a neonate. *BJR| case reports*. 2019;5(3):20190004.