



CASE REPORT

TdT Negative Lymphoblastic Lymphoma: A Case Report

Fariba Binesh^{1,2,3}, Alireza Jenabzadeh^{2,4}, Mohammad Ali Dideban¹, Najmeh Beheshti¹, Fatemeh Khaleghi⁵, Seyed Hossein Shahcheraghi^{3*}

¹Department of Pathology, Shahid Sadoughi University of Medical Sciences, Yazd, Iran

²Hematology and Oncology Research Center, Shahid Sadoughi University of Medical Sciences and Health Services, Yazd, Iran

³Infectious Diseases Research Center, Shahid Sadoughi Hospital, Shahid Sadoughi University of Medical Sciences, Yazd, Iran

⁴Children Growth Disorder Research Center, Shahid Sadoughi University of Medical Sciences, Yazd, Iran

⁵Department of Radiology, Shahid Sadoughi University of Medical Sciences, Yazd, Iran

ARTICLE INFO

Article History:

Received: 30.09.2021

Accepted: 27.11.2021

Keywords:

Terminal deoxynucleotidyl transferase (TdT)

Acute lymphoblastic leukemia/lymphomas

TdT negative T cell malignancy

Children

*Corresponding author:

Seyed Hossein Shahcheraghi,
Infectious Diseases Research Center,
Shahid Sadoughi Hospital, Shahid
Sadoughi University of Medical
Sciences, Yazd, Iran

Email: shahcheraghi@gmail.com

ABSTRACT

Acute lymphoblastic leukemia/lymphomas are tumors made of the precursor B or T cells. Precursor B cell type presents as acute leukemia, and most cases of pediatric leukemia are of this type. Malignancies originated from T cells are less common and are often manifested as lymphoma in adolescents. Terminal deoxynucleotidyl transferase (TdT) is a DNA polymerase that is present in immature pre-B and pre-T cells. TdT enzyme is a sign of cell immaturity and is used to differentiate the dominant types of lymphoblastic lymphoma from mature lymphoma/leukemia cells. TdT is expressed in 90%–95% of lymphoblastic lymphoma cells. Childhood TdT negative lymphoblastic leukemia/lymphoma is very infrequent and its prognostic significance remains challenging. It is suggested that TdT negative lymphoblastic leukemia/lymphoma shows poor response to chemotherapy and has a more disastrous course. Here, we report a case of TdT negative T-cell lymphoblastic lymphoma in a 10-year-old boy who presented with respiratory distress.

Please cite this article as: Fariba B, Jenabzadeh AR, Dideban MA, Beheshti N, Khaleghi F, Shahcheraghi SH. TdT Negative Lymphoblastic Lymphoma: A Case Report. IJBC 2021; 13(4): 140-143.

Introduction

Acute lymphoblastic leukemia (ALL) is the most common pediatric malignancy. Most childhood leukemias are of the pre-B cell phenotype. Precursor T cell immunophenotype is more common in male adolescents and manifests as lymphoblastic lymphoma (LBL).¹ It usually presents as a fast-growing mediastinal mass accompanied with pleural effusion. Bone marrow is spared frequently.² Immunohistochemistry staining is definitely required for correct diagnosis.

In addition to lineage specific markers, precursor lymphocytes are positive for markers of immaturity, including CD34, CD1a, and terminal deoxynucleotidyl transferase (TdT). TdT is an intranuclear DNA polymerase which catalyzes joining of deoxynucleotides to the 3'-hydroxyl terminus of oligonucleotide primers. TdT

is expressed in 95% of precursor T or B cell lymphoma/leukemia cells.³ This DNA polymerase enzyme is practical in recognizing ALL from mature lymphoid tumors. TdT-negative precursor T or B leukemia/lymphoma may be derived either from an early stage of precursors missing TdT expression or from a later stage of maturation with lack of differentiation. Scarcely, does the tumor cells lack both TdT and CD34. Fewer than 5% of pre-T cells in ALL/LBLs are negative for TdT.²

Here, a 10-year-old boy with TdT-negative T-cell lymphoblastic lymphoma is presented who was referred with respiratory distress.

Case Report

A 10-year-old boy presented to the pediatric emergency department with 10-days history of dry cough and

progressive dyspnea. General physical examination revealed a conscious boy suffering from dyspnea. His symptoms were aggravated by lying down. On physical examination, there was no evidence of peripheral lymphadenopathy or hepatosplenomegaly. His respiratory rate was 40/min, O₂ saturation 74%, pulse rate 70/min and blood pressure was 110/70 mmHg. Chest radiograph showed a right-sided white lung (Figure 1). Ultrasound examination revealed severe pleural effusion in the right side. Liver span was 98 mm and spleen was 92 mm in length. There was no evidence of para-aortic lymphadenopathy. Both testes had normal size and parenchymal echo. Spiral chest CT-scan showed severe right sided pleural effusion with collapse of right lung as well as deviation of heart and mediastinum to the left. A soft tissue mass in anterior mediastinum measuring 99 × 58 mm was noted (Figures 2 and 3). A few nonspecific sub-centimeter right axillary lymph nodes were also noted. Laboratory results were within normal range except for mild increase in LDH (823 IU/L). A thoracentesis was performed for the patient in which the aspirated fluid showed numerous dyscohesive small round cells with hyperchromatic nuclei, coarse chromatin and high N/C ratio (Figure 4). Flow cytometry of the pleural fluid was positive for CD45, CD3, CD99 and negative for CD20, ALK, CD117 and CD30. TdT was repeated twice which came to be negative (Figure 5). Based on morphologic and immunophenotyping results, TdT-negative T-cell lymphoblastic lymphoma was diagnosed for the patient.

Bone marrow aspiration and trephine biopsy revealed scattered atypical lymphoid cells infiltration in favor of bone marrow involvement. The patient received T-cell ALL directed chemotherapy. He is well in remission until this report. Informed consent was obtained from the parents to report this case.

Discussion

ALL is the most common pediatric hematologic malignancy. Most children with ALL are of B-cell immunophenotype. Correct diagnosis is based on morphologic characteristics and IHC/flow cytometry findings. While, TdT is expressed in most ALL/LBL cases in children, it is positive in about 10% of patients with acute myelogenous leukemia (AML).⁴ As a matter of fact, TdT expression along with other markers is the key method to differentiate ALL from AML. More to add, TdT is most useful in distinguishing ALL from mature B-lymphoid neoplasms, such as Burkitt lymphoma (FAB L3) and other lymphoid malignancies.⁴

Despite the fact that TdT is positive in 90-95% of ALL/LBL cases, it should be mentioned that lack of expression of TdT does not exclude the diagnosis of ALL/LBL.⁵ ⁶ In a study on adults with high-risk T-lymphoblastic leukemia/lymphoma, 12% of patients from a cohort of 59 de novo T-ALL/LBL were TdT negative. The TdT-negative and TdT-positive cases were similar regarding their gender, percentage of patients with high leukocyte counts, central nervous system involvement, and an abnormal karyotype. In addition, patients with TdT-negative T-ALL/LBL had a significantly higher rate of

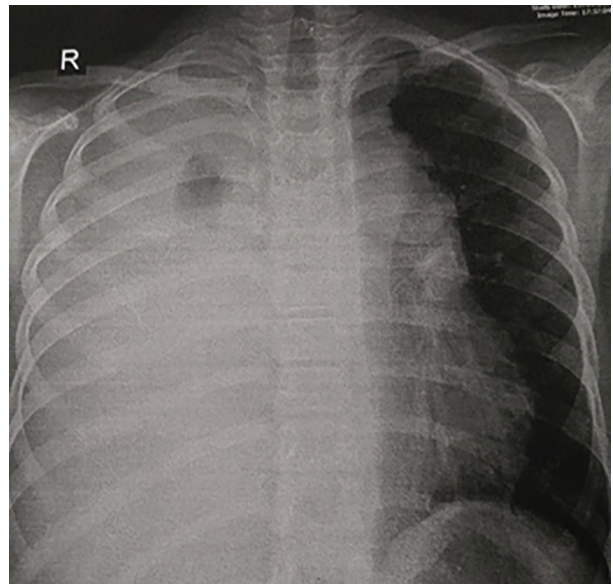


Figure 1: Chest X-ray showing right-sided unilateral white lung.

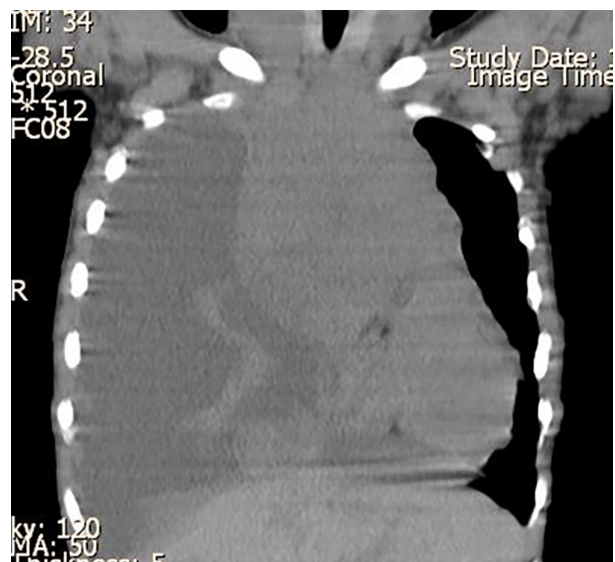

Figure 2: Spiral chest CT-scan revealed soft tissue mass lesion in anterior mediastinum.

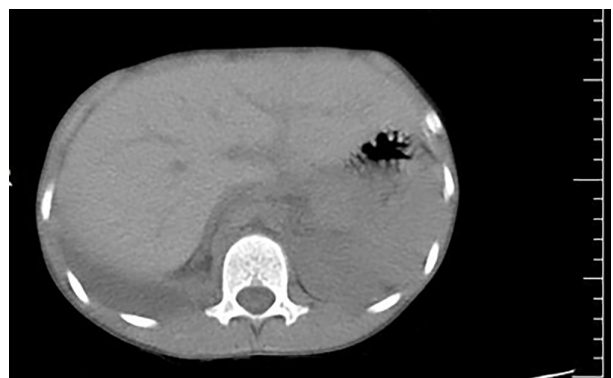

Figure 3: Spiral chest CT-scan showed severe right-sided pleural effusion.

disease progression and shorter overall survival and were associated with elder patients and higher percentage of “early T precursor” (ETP) immunophenotype than TdT-positive cases.⁷ Interestingly, although TdT negative

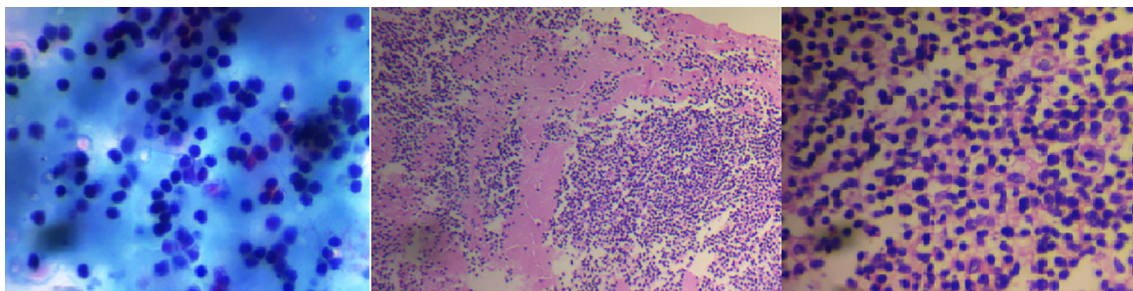


Figure 4: Left panel: smear of pleural fluid shows numerous small-sized lymphoid cells with round nuclei, high N/C ratio and inconspicuous nucleoli (papanicolaou staining method). Middle and right panels reveals neoplastic cells in cell bloc specimen (X10 and X40 respectively, H&E staining method)

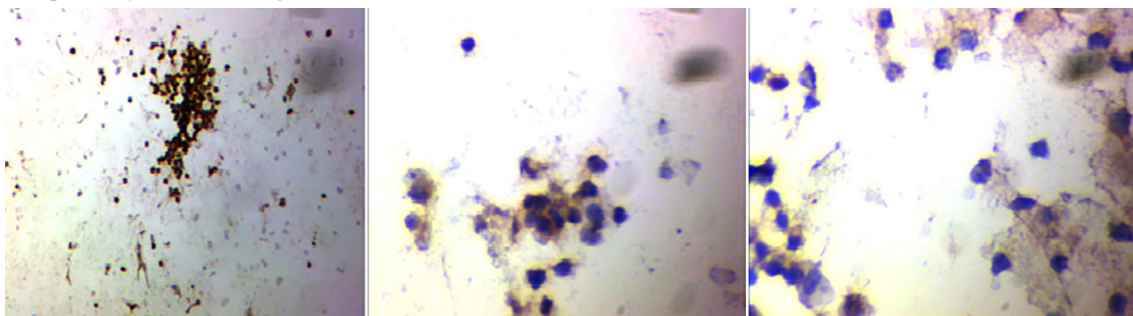


Figure 5: Tumor cells were positive for CD3 (left panel), negative for CD20 (middle panel) and negative for TdT (right panel).

T-cell ALL cases are rare, the frequency of TdT negative B-cell ALL has not been examined extensively. In a study on children with ALL, immunophenotypes of 186 new cases of pediatric B-cell ALL was reviewed which 5 (2.7%) TdT negative cases were found.⁸ They showed significantly higher frequencies of a WBC count of more than 50,000/microL, CD10 and CD34 negativity and MLL gene rearrangement compared with TdT positive cases.⁸ Faber et al. has reported 3 TdT negative out of 200 ALL cases. The three TdT negative patients in their study were of early T-cell lineage. Flow cytometric analysis confirmed a pre-T-cell immunophenotype in all 3 cases. One of the cases showed rearrangement of a T-cell antigen receptor and immunoglobulin heavy chain. A second case showed germline configuration of T-cell receptors, but also showed rearrangement of the immunoglobulin heavy chain, despite the expression of T-cell markers only.⁴

In a 10-years study, 43 pediatric patients were diagnosed with lymphoblastic leukemia, of which 6 (14%) were characterized as TdT negative by flow cytometric analysis. Four of these 6 patients had B-LL and the other 2 had T-LL. Two of the six TdT-negative patients also had undetectable CD34 expression by flow cytometry (TdT/CD34 double-negative). Surprisingly, immunohistochemistry on paraffin-embedded tissues of all 6 patients with negativity for TdT on flowcytometry showed weak TdT-like immunoreactivity in their marrow.⁹ It could be suggested that TdT negative pediatric B- and T-LL cases (especially those that are TdT/CD34 double-negative) confer diagnostic challenge to hematopathologists and further studies (paraffin immunohistochemistry) may be required in reaching the correct diagnosis.⁹

It is claimed that TdT negative T-ALL/LBL represents an aggressive subtype of T-ALL/LBL that has some common features with ETP leukemia (Early T-cell Precursor). In other words, TdT negativity has a

prognostic value. Yi Zhou et al. showed that patients with TdT negative T-ALL/LBL had more advanced disease, and higher rate of disease progression. As a result, they had a shorter survival time similar to ETP leukemia cases.⁷ Lanting Liu et al. also found that for TdT-negative T-ALL/LBL patients who suffered from a severe disease, allogeneic stem cell transplantation after complete remission is the best treatment option. In addition, the authors emphasized that TdT negativity does not exclude a diagnosis of ALL/LBL.⁸ Another interesting point is that the strength of TdT reactivity is far weaker in ALL with myeloid aberrancy than it is in myeloid-negative ALL.¹⁰ It should be noted that TdT expression can be down regulated after chemotherapy.⁷ A case of TdT negative T-LBL with aberrant Platelet Derived Growth Factor Receptor Alpha expression has been described by Terada et al.¹¹ Xubo Pan et al. described an elderly lady with TdT negative T cell LBL arising from heterotopic Warthin's tumor in cervical lymph nodes.¹² Although TdT is a valuable marker in the differential diagnosis of precursor T or B cell lymphoma/leukemia versus other malignant round cell neoplasms, it has been detected in rare other non-hematologic malignancies such as Merkel cell carcinoma.¹³ Furthermore, hematogones are also positive for TdT and this point should be taken into account when interpreting bone marrow biopsy slides.¹³ Normal cortical thymocytes are also positive for TdT and it should not be misinterpreted as T-LBL in a small mediastinal biopsy sample.¹³ In this regard, Oschlies et al. recommended that when we encounter a case with lymphoblastic morphology and TdT negative immunophenotype, either expression of CD1a or CD34, coexpression of CD79a and CD3 or co-expression of CD4 and CD8 could be useful.¹³ It should be noted that co-expression of CD4 and CD8 has also been described in some mature T cell neoplasms.¹³

Conclusion

Pediatric TdT negative precursor B- or T-lymphoblastic leukemia/lymphoma cases are rare and their prognostic significance remains controversial. TdT negativity does not exclude the diagnosis of LBL and searching for other markers of immaturity such as CD99 and CD34 are suggested in these cases. In addition, TdT negative pediatric B- and T-LL cases (especially those that are TdT/CD34 double negative) confer diagnostic challenge to hematopathologists and further studies (paraffin immunohistochemistry) are suggested in order to reach the correct diagnosis

Conflict of Interest: None declared.

References

- Hassan M, Abdullah HMA, Wahid A, Qamar MA. Terminal deoxynucleotidyl transferase (TdT)-negative T-cell lymphoblastic lymphoma with loss of the T-cell lineage-specific marker CD3 at relapse: a rare entity with an aggressive outcome. *BMJ Case Rep.* 2018; 2018: bcr2018224570. doi: 10.1136/bcr-2018-224570.
- Han X, Bueso-Ramos CE. Precursor T-Cell Acute Lymphoblastic Leukemia/ Lymphoblastic Lymphoma and Acute Biphenotypic Leukemias. *Am J Clin Pathol.* 2007; 127:528-44. doi: 10.1309/2QE3A6EKQ8UYDYRC.
- Seegmiller AC, Kroft SH, Karandikar NJ, McKenna RW. Characterization of immunophenotypic aberrancies in 200 cases of B acute lymphoblastic leukemia. *Am J Clin Pathol.* 2009; 132: 940–9. doi: 10.1309/AJCP8G5RMTWUEMUU.
- Faber J, Kantarjian H, Roberts WM, Keating M, Freireich E, Albitar M. Terminal deoxynucleotidyl transferase–negative acute lymphoblastic leukemia. *Arch Pathol Lab Med.* 2000; 124: 92-7. doi: 10.1043/0003-9985(2000)124<0092:TDTNAL>2.0.CO;2.
- Patel JL, Smith LM, Anderson J, Abromowitch M, Campana D, Jacobsen J, et al. The immunophenotype of T-lymphoblastic lymphoma in children and adolescents: a Children’s Oncology Group report. *Br J Haematol.* 2012; 159: 454–61. doi: 10.1111/bjh.12042.
- Borowitz MJ, Chan JKC. T lymphoblastic leukaemia/lymphoma. In: Swerdlow SH, Campo E, Harris NL, Jaffe ES, Pileri SA, Stein H, Thiele J, Vardiman JW, eds. *WHO classification of tumors of haematopoietic and lymphoid tissues.* 4th ed. Lyon: Int Agency Res Cancer. 2008.
- Zhou Y, Fan X, Routbort M, Yin CC, Singh R, Bueso-Ramos C, et al. Absence of terminal deoxynucleotidyl transferase expression identifies a subset of high-risk adult T-lymphoblastic leukemia/lymphoma. *Mod Pathol.* 2013; 26: 1338–45. doi: 10.1038/modpathol.2013.78.
- Liu L, McGavran L, Lovell MA, Wei Q, Jamieson BA, Williams SA, et al. Nonpositive Terminal Deoxynucleotidyl Transferase in Pediatric Precursor B-Lymphoblastic Leukemia. *Am J Clin Pathol.* 2004; 121: 810-85. doi: 10.1309/QD18-PPV1-NH3T-EUTF.
- Yasmeen S, Rajkumar A, Grossman H, Szallasi A. Terminal Deoxynucleotidyl Transferase (TdT)-negative Lymphoblastic Leukemia in Pediatric Patients: Incidence and Clinical Significance. *Pediatr Dev Pathol.* 2017; 20: 463-8. doi: 10.1177/1093526617698610.
- Paietta E, Racevskis J, Bennett JM, Wiernik PH. Differential expression of terminal transferase (TdT) in acute lymphocytic leukaemia expressing myeloid antigens and TdT positive acute myeloid leukaemia as compared to myeloid antigen negative acute lymphocytic leukaemia. *Br J Haematol.* 1993; 84: 416-22. doi: 10.1111/j.1365-2141.1993.tb03095.x.
- Terada T. TDT (-), KIT (+), CD34 (+), CD99 (+) precursor T lymphoblastic leukemia/lymphoma. *Int J Clin Exp Pathol.* 2012; 5: 167–70.
- Pan X, Yu S, Che L, Xu J, Zhou H. Terminal deoxynucleotidyl transferase negative T-cell lymphoblastic lymphoma from heterotopic Warthin’s tumor in cervical lymph nodes: a case report and review of literature. *Int J Clin Exp Pathol.* 2019; 12: 4167-70.
- Oschlies I, Burkhardt B, Chassagne-Clement C, d’Amore ES, Hansson U, Hebeda K, et al. Diagnosis and immunophenotype of 188 pediatric lymphoblastic lymphomas treated within a randomized prospective trial: experiences and preliminary recommendations from the European childhood lymphoma pathology panel. *Am J Surg Pathol.* 2011; 35: 836-44. doi: 10.1097/PAS.0b013e318213e90e.