IJBC 2009; 5: 7-10

Pediatric Meduloblastoma and the Prognostic Value of MIB-1 Proliferative Factor

Farzaneh Jadali [1], Elham Amini [1], Mandana Esfahani [2], Samin Alavi [3]

1. Department of Pathology, Mofid Children's Hospital, Tehran, Iran.
2. Department of Hematology, Mofid Children's Hospital, Tehran, Iran.
3. Department of Hematology, Mofid Children's Hospital, Tehran, Iran.

Corresponding author: Department of Hematology, Mofid Children's Hospital, Tehran, Iran.

Abstract

Background: Medulloblastoma is the most common malignant brain tumor in children. The important factors in predicting survival are the extent of disease, proliferation index of the tumor cells, histopathologic class and the age at diagnosis. The percentage of Ki-67 positive cells reflects the proliferation of the cells and is one of the critical factors which determine the growth of the tumor. Monoclonal MIB-1 antibody can be targeted against recombinant Ki-67 and then demonstrated by immunohistochemical methods.

Materials and Methods: Formalin-fixed, paraffin-embedded tissue of 18 pediatric patients with medulloblastoma at Mofid Children Hospital between January 2003 and December 2008 were used to perform Ki-67 (MIB-1) immunohistochemical analysis. Proliferative labeling index (LI) was scored in the tumor cells to determine the extent of proliferation.

Results: The mean±SD of MIB-1 LI index was 53%±21% (range 25% to 85%). Kaplan–Meier curves showed that patients with MIB-1 LI <40% had higher 5-year survival than patients with MIB-1 LI> 40% (p=0.04). This difference remained statistically significant in Cox regression analysis.

Conclusion: We suggest that MIB-1 LI is helpful as a prognostic factor in predicting survival of patients with pediatric medulloblastoma.

Keywords: Meduloblastoma, MIB-1, Prognosis.

Introduction

Approximately 70% of patients with medulloblastoma, the most common malignant brain tumor of childhood, are diagnosed before they reach the age of 20 years, with the peak incidence between 5 and 9 years.[1] These primitive neuroectodermal tumors of cerebellum, arise from granule cell precursors. Outcome depends on the extent of disease and the age at diagnosis.[2] Patients without metastatis (M0) have a higher five-year progression-free survival (PFS) (70% for M0 versus 57% for M1 and 40% for M2, M3, or M4 stage)[3]. The 2007 WHO classifications of medulloblastoma are desmoplastic/nodular; medulloblastoma with extensive nodularity (MBEN), anaplastic and large cell. Monoclonal MIB-1 antibody is used against recombinant Ki-67 and is demonstrated by immunohistochemical methods.[4] The percentage of Ki-67 positive cells reflects the proliferating fraction of a certain cell population. [4] Regarding to the scant experiments about medulloblastoma and the MIB-1 proliferation index we examined the expression of Ki-67 by MIB-1 in 18 formalin-fixed, paraffin-embedded biopsy samples of medulloblastoma pediatric patients whose both clinical data and pathological specimens were available.

Materials and Methods

Clinical Records and Pathological materials

Tumor specimens were obtained from 18 pediatric patients with Medulloblastoma at Mofid Children Hospital of Shaheed Beheshti Medical University between January 2003 and December 2008. All patients had sufficient paraffin-embedded tissue to perform Ki-67 (MIB-1) immunohistochemical analysis. Routine H&E

[Downloaded from ijbc.ir on 2026-11-28]

histological sections were reviewed according to the World Health Organization system (WHO) classification system.

Immunohistochemical Method and MIB- 1 Staining Index

Formalin fixed 4 mm sections were stained by hematoxylin-eosin (H&E) and immunohistochemistry with monoclonal anti Ki-67 antigen clone MIB-1 (Immunotech, catalog number 0505, France) using streptavidin-biotin-peroxidase complex technique. Sections were incubated overnight at 4^0 C with antibody MIB- 1 diluted 1:100 in 1% bovine serum albumin and phosphate buffered solution (PBS). Slides were then incubated for 30 min at 37^0 C with biotinylated goat anti-mouse/rabbit immunoglobin, followed by incubation for another 30 min at 37^0 C with the complex, streptavidin and biotinylated peroxydase (StreptABComplex/ HRP Duet, Dako, k492, USA). The color reaction was developed with 3,3' diaminobenzidine tetrahydrochloride (Sigma, D-5637, USA), 6% H_2O_2 and PBS. Sections were counterstained with Harris hematoxylin, dehydrated and coverslipped. Cells were positive when the entire nucleous or a portion of it was stained. The labeling index (LI) or growth fraction was the proportion of positive cells in relation to total of 1,000 cells. Negative and positive control slides were used to check the accuracy of final readings. Clinical data was extracted from patients' hospital records.

Outcome was defined in survival and disease free period .

Statistical Methods

Data was analyzed using SPSS ver. 15.0 software (Chicago, IL). Descriptive estimated were produced by the Kaplan-Meier method. Univariate and multivariate analysis were performed using the log-rank test and the Cox regression model.

Results

There were 10 males (56%) and 8 females (44%) in the population of patients. Age of diagnosis ranged between 1 to 10 years (mean 4.4 years). 11 tumors were in 4th ventricle (61%), 5 in cerebellum (28%), 1 in the right hemisphere (5%) and 1 in the right cerebropontine angle (5%). 14 patients suffered from obstructive ventriculomegaly (77%). 2 patients suffered from eye deviation and vomiting in the 10 days interval between their first symptoms and final diagnosis. One patient was diagnosed 150 days after his presenting sign of loss of visual acuity. Histopathologic tumor variants included 12 classic medulloblastoma (66%), 3 desmoplastic (16.5%) and 3 medulloblastoma with extensive nodularity (16.5%). Out of 18 patients, 9 died of the disease complications and three patients died because of surgical side effects within 2 months after surgery.

MIB-1LI and Survival

The mean±SD of MIB-1 LI was 53%±21% (range: 25% to 85%). Patients with MIB-1LI values from 25% to 85% had survival probability of 44% per year. All patients with MIB-1 LI lower than 53% were alive at their final follow up. Patients with MIB-1 LI higher than 53% showed yearly survival probability of 33%. Kaplan–Meier analysis showed that the event free survival of patients with MIB-1 LI <40% was higher than patients with MIB-1 LI> 40% (p=0.04). This difference remained statistically significant in Cox regression analysis. If the cut off point was chosen at 30%, the difference in survival was no longer statistically significant (p=0.06). (Figure 1) Nodular and desmoplastic variants had longer event free survival in comparison with the classic variant (p=0.01). Kaplan–Meier and Cox regression analysis did not reveal associations of gender (p=0.2), age at diagnosis (p=0.1) and tumor location (p=0.9) with survival.

Discussion

Medulloblastoma is the most frequent malignant brain tumor of childhood with an incidence of 25%; it is of embryonal neuroepithelial tumors and occurs in the cerebellum.[5] To improve high-risk patients outcome and survivors' quality of life, novel therapies and better tumor classification systems are required. [6]

We reviewed 18 pediatric patients with medulloblastoma. The prevalence was slightly higher in males than females (56% vs. 44%) which confirms the literature data. We did not find any correlation between gender and age with survival, as did Curran et al. on 763 males and 463 females from 1973 to 2002. [7] Natural history and response to treatment may differ in older as compared to younger children[8]. Young age at diagnosis has a

[Downloaded from ijbc.ir on 2026-11-28]

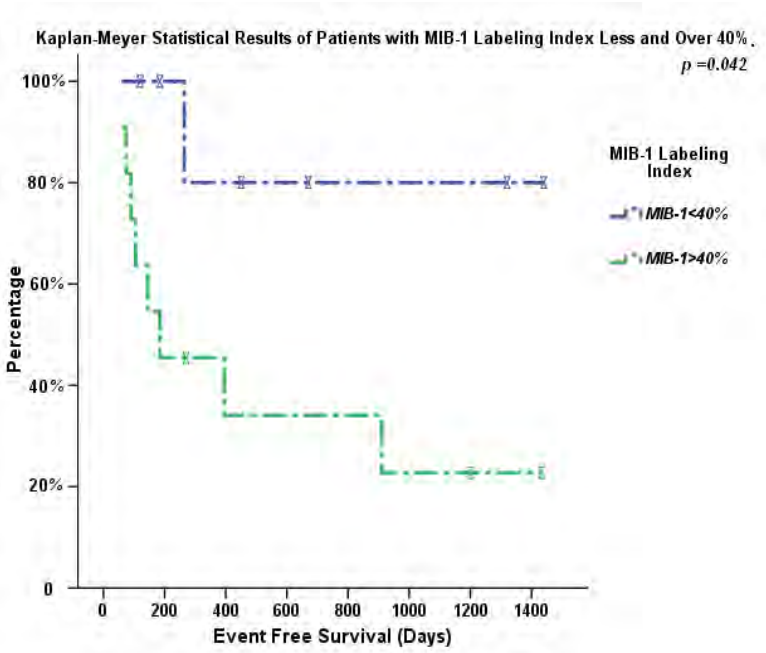

Figure 1. *Comparison of the event free survival for patients with MIB-1 labeling index lower or higher than 40%.*

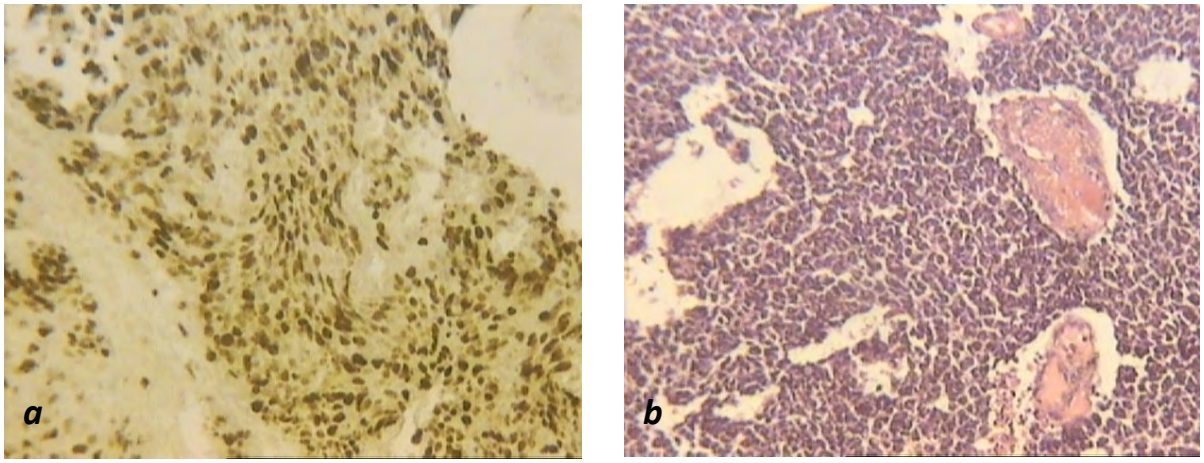

Figure 2. *(a) and (b) show the same tumor.(b) Shows strong MIB-1 positivity.*

negative impact on long-term survival and quality of life in survivors. [4] In one series, the estimated five-year progression free survival was 32 % in patients diagnosed at the age of 1.5 to 3 years versus 58% in those 3 years and older[9]. We did not find any correlation between age and prognosis due to the small sample size of our specimens. A study from the German Pediatric Brain Tumor Study Group has shown a better 5 year survival for infants with desmoplastic medulloblastoma than the classic variant (95 vs. 41%)[10]. A British study has confirmed this result in older children. In our study, nodular and desmoplastic tumors had a significant longer event free survival in comparison with the classic variant (p=0.01).

Ertan et al. aimed to assess the prognostic value of MIB-1 and p53 in pediatric medulloblastoma. Out of 35 patients in their study, 21 remained alive without any evidence of recurrent disease, three were alive with evidence of recurrent disease and

[Downloaded from ijbc.ir on 2026-11-28]

11 died of disease during their follow-up. The mean±SD of survival for these 11 patients was 21.9±10.4 months. Out of these 35 cases, 16 had MIB-1 values of 25% or lower and 19 had values of 26% or higher. In the 16 patients with low MIB-1 value, six died of the disease and in the 19 patients with high MIB-1 value, five died of the disease. The association between MIB-1 and prognosis was not statistically significant.[11]

In another study, Ferrari AF et al. determined the MIB-1 LI values in 22 patients and their prognostic values. The histopathological diagnosis was confirmed by H&E and proliferative index (LI) was achieved with MIB-1 which detects proliferating cells during G1, G2, S and M phases. The results demonstrated that the mean MIB-1 was 30.1%, and ranged from 5.2% to 62.0

Meurer RT et al. [13] studied immunohistochemical expression of Ki-67, NeuN, synaptophysin, HER2 and p53 in 40 patients with meduloblastoma and their correlation with clinicopathologic parameters and survival. In 29 patients (72.5%), >20% of cells were positive for Ki-67. Males showed greater ki-67 expression (p=0.02) and lower survival rates (p=0.002).[13]

In the present study, the mean MIB-1 LI was 53 % (ranged from 25% to 85%, SD=21%).MIB-1LI values, from 25% to 85% ,showed survival of 44 % per year. All patients with MIB-1 LI lower than 53% were alive. Survival of patients with MIB-1 LI higher than 53% was 33% in one year. Kaplan–Meier analysis showed that the patients with MIB-1 LI <40% had higher event free survival than patients with MIB-1 LI> 40% (p=0.04).

Conclusion

The MIB-1 LI is a prognostic factor in patients with medulloblastoma. The authors suggest determining MIB-1 L1 routinely in pediatric patients with medulloblastoma. For patients with MIB-1 LI greater than 40% more aggressive treatment might be needed. The authors recommend more researches regarding the correlation between MIB-1 LI and medulloblastoma prognosis.

References

1. Dhall G. Medulloblastoma. J Child Neurol. 2009 Nov; 24: 1418-30.

2. Deutsch M, Laurent JP, Cohen ME. Myelography for staging medulloblastoma. Cancer 1985; 56: 1763-6.

3. Zeltzer PM, Boyett JM, Finlay JL, Albright AL, Rorke LB, Milstein JM, et al. Metastasis stage, adjuvant treatment, and residual tumor are prognostic factors for medulloblastoma in children: conclusions from the Children's Cancer Group 921 randomized phase III study. J Clin Oncol. 1999; 17: 832-45.

4. Cattoretti G, Becker MH, Key G, Duchrow M, Schluter C, Galle J, et al. Monoclonal antibodies against recombinant parts of the Ki-67 antigen (MIB 1 and MIB 3) detect proliferating cells in microwave-processed formalin-fixed paraffin sections. J Pathol. 1992; 168: 357-63.

5. Mazzola CA, Pollack IF. Medulloblastoma. Curr Treat Options Neurol. 2003; 5: 189-98.

6. Gulino A, Arcella A, Giangaspero F. Pathological and molecular heterogeneity of medulloblastoma. Curr Opin Oncol. 2008; 20: 668-75.

7. Curran EK, Sainani KL, Le GM, Propp JM, Fisher PG. Gender affects survival for medulloblastoma only in older children and adults: A study from the surveillance epidemiology and end results registry. Pediatr Blood Cancer. 2009; 52: 60-4.

8. Tabori U, Sung L, Hukin J, Laperriere N, Crooks B, Carret AS, et al. Medulloblastoma in the second decade of life: a specific group with respect to toxicity and management: a Canadian Pediatric Brain Tumor Consortium Study. Cancer. 2005; 103: 1874-80.

9. Koeller KK, Rushing EJ. From the archives of the AFIP: medulloblastoma: a comprehensive review with radiologic-pathologic correlation. Radiographics. 2003; 23: 1613-37.

10. Grill J, Sainte-Rose C, Jouvet A, Gentet JC, Lejars O, Frappaz D, et al. Treatment of medulloblastoma with postoperative chemotherapy alone: an SFOP prospective trial in young children. Lancet Oncol. 2005; 6: 573-80.

11. Ertan Y, Sezak M, Demirağ B, Kantar M, Cetingül N, Turhan T, et al. Medulloblastoma: clinicopathologic evaluation of 42 pediatric cases. Childs Nerv Syst. 2009 Mar; 25: 353-6.

12. Ferrari AF, Araújo MB, Aguiar PH, Plese JP. Medulloblastoma: evaluation of proliferative index by monoclonal antibody MIB-1, its prognostic correlation and therapeutic implications. Arq Neuropsiquiatr. 2003 Sep; 61:547-51.

13. Meurer RT, Martins DT, Hilbig A, Ribeiro Mde C, Roehe AV, Barbosa-Coutinho LM,et al. Immunohistochemical expression of markers Ki-67, neun, synaptophysin, p53 and HER2 in medulloblastoma and its correlation with clinicopathological parameters. Arq Neuropsiquiatr. 2008 Jun; 66: 385-90.

[Downloaded from ijbc.ir on 2026-11-28]