Iranian Journal of Blood & Cancer

Iran J Blood Cancer, 2025, 17(4), 14-19
https://ijbc.ir

Case Report

A Novel Chromosomal Translocation t(X;10) in a Pediatric Acute Myeloid Leukemia Patient Complicated by Subarachnoid Intraventricular Hemorrhage

Suresh Kumar Prajapati[1], Charmi Jyotishi[1], Dharmesh Vaghasiya[2], Reeshu Gupta[1,3*]

[1]Parul Institute of Applied Sciences, Parul University, Post Limda, Waghodia Road, Vadodara, Gujarat, India.
[2]Blood Cancer Institute, Surat, Gujarat, India.
[3]Research and Development Cell, Parul University, Post Limda, Waghodia Road, Gujarat, India.

Scan and read the article online

Citation Kumar Prajapati S, Jyotishi Ch, Vaghasiya D, Gupta R. A Novel Chromosomal Translocation t(X;10) in a Pediatric Acute Myeloid Leukemia Patient Complicated by Subarachnoid Intraventricular Hemorrhage . Iran J Blood Cancer. 2025 Dec 30;17(4): 14-19.

doi 0

Article info:
Received: 26 Oct 2025
Accepted: 07 Dec 2025
Published: 30 Dec 2025

Abstract

Background: Acute myeloid leukemia (AML) is a malignancy of hematopoietic stem cells, seen rarely in children. Intraventricular hemorrhage (IVH) is an uncommon but often fatal complication of AML, and its management is difficult because it requires balancing intensive chemotherapy with supportive care for bleeding.

Case Presentation: We report the case of an 11-year-old child with newly diagnosed AML who presented with fever, neurological deterioration, and respiratory distress, and was found to have subarachnoid intraventricular hemorrhage.

Cytogenetic Findings: Bone marrow karyotyping demonstrated a novel translocation involving chromosomes X and 10 with breakpoints at Xq13 and 10p11.2 or 46,XY,t(X;10)(q13;p11.2). This was confirmed by fluorescence in situ hybridization (FISH). Other recurrent AML-associated abnormalities were not detected.

Clinical Course: The patient received antifibrinolytics, platelet support, anticonvulsants, and external ventricular drainage. Flow cytometry of bone marrow aspirate showed 85% blasts expressing CD34, CD117, HLA-DR, CD13, and CD33, consistent with AML. The patient developed refractory shock and cardiac arrest, and death occurred before leukemia-directed treatment could be initiated.

Conclusions: This case describes a rare cytogenetic abnormality in AML associated with IVH. A direct causal relationship cannot be inferred from a single report; however, documenting such rare findings adds to the body of knowledge and may help in future studies exploring genetic factors and clinical outcomes in AML.

Keywords:
Chromosome Translocation
Leukemia
Myeloid, Acute

* Corresponding Author:
Reeshu Gupta
Affiliation: Research and Development Cell, Parul Institute of Applied Sciences, Parul University, Post Limda, Waghodia Road, Vadodara, Gujarat, India
E-mail: **reeshu.gupta25198@paruluniversity.ac.in**

[Downloaded from ijbc.ir on 2026-11-24]

[DOI: 10.66224/ijbc.17.4.14]

1. INTRODUCTION

Chronic Acute myeloid leukemia (AML) is a hematopoietic stem cell cancer that originates in the bone marrow and blood. AML is rare in childhood compared to adults. Its estimated annual incidence is about 1.5 per 100,000 in infants, 0.9 per 100,000 in children aged 1–4 years, and 0.4 per 100,000 in children aged 5–9 years (1, 2). Various gene abnormalities and chromosomal rearrangements lead to the clonal transformation of hematopoietic progenitors in AML.[3]

According to the previous study, the most common cytogenetic abnormality is balanced translocation t (8; 21), followed by trisomy 8 and t (15; 17) (3) (4, 5). However, involvement of sex chromosomes in karyotype aberrations of AML patients is rare. As per documented studies, sex chromosomal abnormalities consist of deletions, duplications, or translocations of the long arm of chromosome X. For instance, karyogram showing loss of sex chromosomes (46,XX,t(8;21) (q22;q22.3)(2)/45,sl,-X/(16)/46,XX(2)) was found to be associated with greater incidence of complete remission (6). However, the involvement of sex chromosome abnormalities with intraventricular hemorrhage (IVH) in patients with AML has not been reported.

Here, we report a novel translocation between chromosomes X and 10, involving breakpoints at Xq13 and 10p11.2, in a pediatric AML patient who presented with subarachnoid intraventricular hemorrhage.

2. CASE PRESENTATION

2.1. Ethics approval and consent for participation

The study protocol was reviewed and approved by the Ethics Committee of Parul University (approval no. ECR/702/Inst/GJ/2015/RR-21/8702) and conducted in accordance with institutional ethical standards and regulatory guidelines. All procedures performed in this study were in accordance with the principles of medical research of the 1964 Declaration of Helsinki and its later amendments or comparable ethical standards.

2.2. Case history

Presentation: An 11-year-old child was admitted with a 5-day history of fever with chills, vomiting, loose motion, headache, cough, and cold. On admission, vital signs showed normal body temperature, pulse rate of 78/min, respiratory rate of 26/min, blood pressure of 136/90 mmHg, and a markedly elevated WBC count of 270,000/mm^3. The child developed respiratory distress, drowsiness, seizures, and hypoxia, and was shifted to the intensive care unit (ICU) for invasive mechanical ventilation.

Imaging: CT scan of the brain revealed intraventricular hemorrhage.

ICU Course: The patient was managed with intravenous fluids, tranexamic acid (500 mg twice daily), and levetiracetam (500 mg twice daily) to control bleeding and seizures. Despite these measures, no improvement was observed. On the following day, the patient developed tachycardia and transfusion-related acute lung injury (TRALI).

Interventions: Supportive management included administration of four units of fresh frozen plasma (FFP) and six units of random donor platelets (RDP). To manage TRALI, mannitol (100 ml, three times daily) was given. An external ventricular drain was performed. One unit of packed red blood cells was transfused, and sodium and potassium replacement were carried out as part of anti-edema therapy.

Cytogenetic Work-up: Fluorescence in situ hybridization (FISH) using a routine AML panel was negative for t(9;22) BCR/ABL1, PML-RARA, RUNX1-RUNX1T1, CBFB-MYH11 (inv16), deletions of 5/5q and 7/7q, and MLL (11q23) rearrangements. Subsequent bone marrow biopsy demonstrated hypercellular marrow with sheets of 85% blast cells and markedly suppressed erythropoiesis and megakaryocytes (**Table 1**).

Outcome: Despite aggressive supportive measures, the patient developed hypotension and bradycardia, culminating in cardiac arrest. The child was declared dead before AML was confirmed by bone marrow cytology and karyotyping.

Table 1. Differential count analysis of bone marrow aspiration.

Test	Result (%)	Reference Values (%)
Normoblast	2	0.4-4.6
Myelo + Metamyelocytes	1	5.8-24
Neutrophils	7	24.5-72.5
Lymphocytes	3	5.5-23.2
Blasts	85	5
Plasma cells	0	0-7
Eosinophils	0	0.5-7
Monocytes	2	0-6

2.3. Genetic Analysis

Results of flow cytometry predicted the presence of CD45 dim, CD34, CD38, CD117, CD13, CD36, HLA-DR, and

[Downloaded from ijbc.ir on 2026-11-24]

[DOI: 10.66224/ijbc.17.4.14]

cytoplasmic MPO biomarkers, suggesting the diagnosis of AML in the patient.

2.4. Karyotype aberrations analysis

Karyotypic analyses were performed by overnight cultures of bone marrow samples according to the recommendations of the International System for Human Cytogenetic Nomenclature (ISCN). Bone marrow chromosomal analysis revealed a novel translocation between the long arm of chromosome X and the short arm of chromosome 10, with breakpoints at Xq13 and 10p11.2, respectively 46,XY,t(X;10)(q13;p11.2) (Figure 1). This translocation was observed in all metaphases examined during karyotype analysis.

2.5. Fluorescence in situ hybridization

Owing to the lack of a commercially available probe specific to the t(X;10) translocation, an X chromosome-specific probe was applied to metaphases. The probe showed hybridization signals on both the normal X chromosome and derivative chromosome 10, confirming t(X;10) translocation at the molecular level (Figure 2).

Further chromosome analysis was performed using FISH for routine AML-associated genetic abnormalities, such as (t (8;21) BCR/ABL1, PML-RARA, RUNX1-RUNX1T1, CBFB-MYH11 (inversion 16), deletion 5/5q, deletion 7/7q, and MLL (11q23) rearrangement (Figure 3). The results were negative, suggesting that this translocation might be an independent, rare cytogenetic abnormality contributing to AML.

3. DISCUSSION

In this study, we are reporting a novel translocation consisting of Xq13 and 10p11.2 breakpoints. This has not been reported previously. Several reports suggest translocation between chromosomes X and 10 at various breakpoints. For example, a translocation consisting of 10p11 and Xp11 breakpoints has been reported in one case of AML (7). Therefore, t(X;10) (p11;p11) is regarded as a rare yet recurrent cytogenetic abnormality in AML. The translocation was balanced, therapy-related, and restricted to children. However, an unbalanced translocation was also observed in an elderly woman (der(10)t(X;10)(p11;p11)), where der(10)t(X;10)(p11;p11), rather than der(X)t(X;10)(p11;p11), suggested to play a key role in the development of leukemia in AML cases (8).

In the current study, we observed a novel translocation between chromosomes X and 10 in a patient with intraventricular hemorrhage. Notably, the breakpoints involved both the long arm of chromosome X (Xq13) and the short arm of chromosome 10 (10p11.2). It is different from previously reported six studies (4 pediatric and 2 adult cases of AML) which showed translocation between short arms of X and 10 chromosomes at different breakpoints of 10 or 11 (7, 9-12). The four pediatric patients responded well to treatment. However, adult patients do not respond well to these treatments. In the first adult case, treatment with Amphotericin B was initiated, but the patient's condition deteriorated, and he died one month after diagnosis. In the second adult case, the patient relapsed after 10 months of treatment with hyperfractionated Cytoxan, vincristine, adriamycin, and dexamethasone, followed by allogeneic bone marrow transplant from a matched unrelated donor. The patient was then treated with thiotepa and Cytoxan, followed by a second allogeneic bone marrow transplant from a matched unrelated donor. He developed chronic graft-versus-host disease after bone marrow transplantation. None of the patients suffered from intraventricular hemorrhage. Intraventricular hemorrhage is commonly observed in patients with APL subtype of AML. For instance, in one study, eight out of 12 APL patients showed intraventricular hemorrhage (13). This study documents a novel translocation between chromosomes X and 10, with breakpoints at Xq13 and 10p11.2, in a pediatric AML case presenting with intraventricular hemorrhage. While IVH is a recognized complication in acute promyelocytic leukemia (APL), no direct association can be inferred between the X;10 translocation and hemorrhage in this patient, as causality cannot be established from a single case. Previous reports(7, 9-12) have described translocations involving Xp10 and 10p10, but the present case is distinct in breakpoint location. Surprisingly, common cytogenetic abnormalities such as (t (8;21) BCR/ABL1, PML-RARA, RUNX1-RUNX1T1, CBFB-MYH11 (inversion 16), deletion 5/5q, deletion 7/7q, and MLL (11q23) rearrangement were absent in this case. These results suggest that this abnormality may be an independent contributing factor to AML. It has been reported previously that the clinical phenotypes of patients are variable and unpredictable due to differences in breakpoints and X chromosome inactivation (XCI) patterns. Therefore, physicians should focus on the characteristics of X chromosome translocations and provide personalized clinical evaluations during genetic counselling (14). This case highlights a novel translocation involving chromosomes Xp and 10q in a pediatric patient with AML complicated by subarachnoid intraventricular hemorrhage. Although intraventricular hemorrhage is well

[Downloaded from ijbc.ir on 2026-11-24]

[DOI: 10.66224/ijbc.17.4.14]

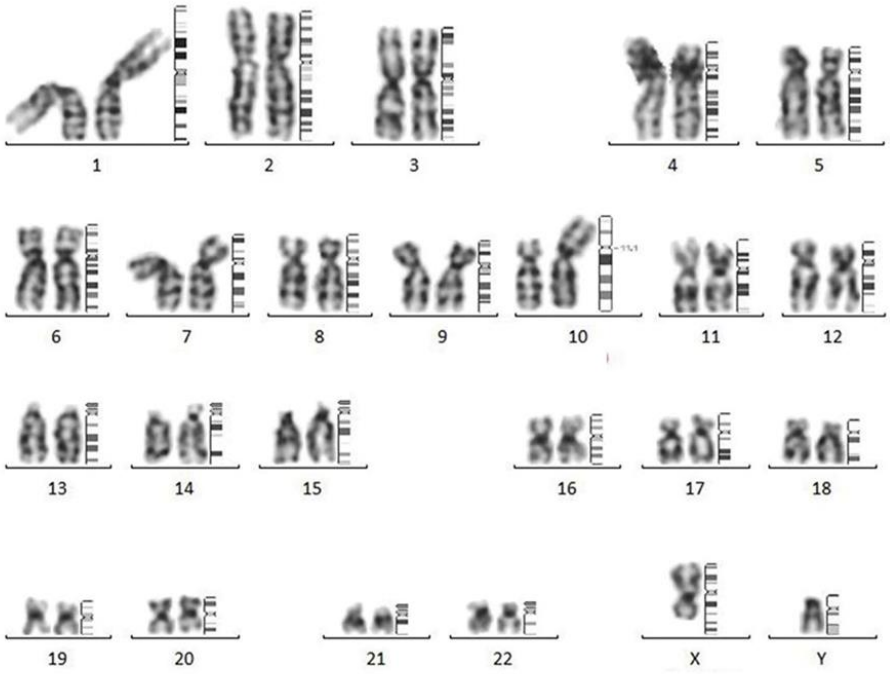

Figure 1. Karyogram of bone marrow cells.

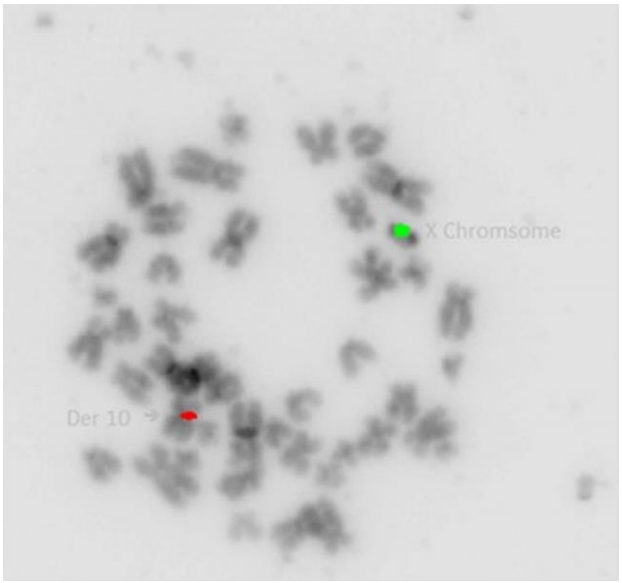

Figure 2. The probe showed hybridization signals on both the normal X chromosome and the derivative chromosome 10, **confirming the translocation X;10.**

recognized in acute promyelocytic leukemia due to coagulopathy, a direct link between the observed X;10 translocation and hemorrhage cannot be established from this single case. Furthermore, the current findings cannot determine whether this abnormality represents a balanced or unbalanced rearrangement, underscoring the need for high-resolution genomic studies to better understand its biological and clinical significance. Published data on the association between AML, hemorrhagic complications, and cytogenetic abnormalities outside of APL remain scarce. The coexistence of a rare cytogenetic abnormality with a fatal central nervous system event in this patient underscores the

[Downloaded from ijbc.ir on 2026-11-24]

[DOI: 10.66224/ijbc.17.4.14]

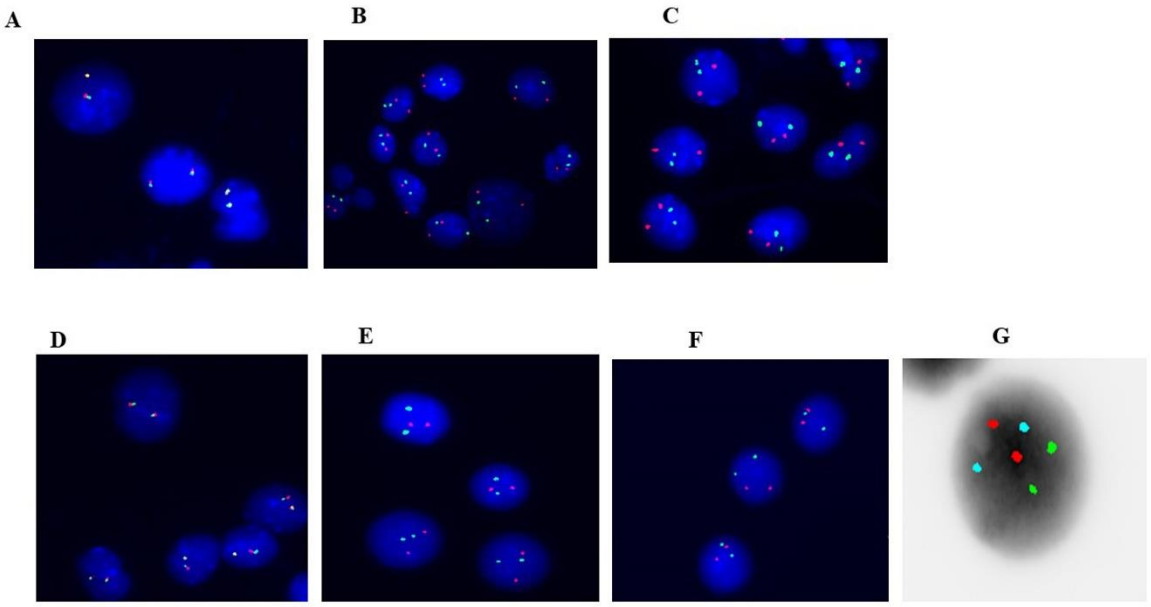

Figure 3. **(A)** MLL gene Rearrangement-The FISH images showing 2 fusion signals showing negative for MLL gene rearrangement. **B)** RUNX1-RUNX1T1 t(8;21)-The FISH images showing 2 spectrum green and spectrum orange signals indicating for negative for translocation t(8;21). **C)** PML-RARA t(15;17)-The FISH images showing 2 spectrum green and spectrum orange signals indicating for negative for translocation t(15;17). **(D)** inv(16) CBFB break-apart probe- FISH images show two fusion signals, indicating negativity for inv(16). **(E)** BCR-ABL t(9;22)- FISH images demonstrate two distinct green and two distinct orange signals, consistent with absence of the t(9;22) translocation. **(F)** Deletion 5q- FISH images reveal two green and two orange signals, indicating no evidence of 5q deletion. **(G)** Deletion 7q- FISH images show two green, two orange, and two blue signals, confirming negativity for 7p/7q deletion.

importance of comprehensive karyotypic and molecular evaluation in pediatric AML.

Acknowledgment

Not applicable.

Conflict of interest

The authors declare no competing interests.

Funding

This study was supported by intramural funding from Parul University (RDC/IMSL/213).

Ethical statement

The study protocol was reviewed and approved by the Ethics Committee of Parul University (approval no. ECR/702/Inst/GJ/2015/RR-21/8702) and conducted in accordance with institutional ethical standards and regulatory guidelines. All procedures performed in this study were in accordance with the principles of medical research of the 1964 Declaration of Helsinki and its later amendments or comparable ethical standards.

References

1. Tseng S, Lee ME, Lin PC. A Review of Childhood Acute Myeloid Leukemia: Diagnosis and Novel Treatment. Pharmaceuticals (Basel). 2023;16(11).

2. (2022) T-CY. Pediatric Acute Myeloid Leukemia (AML) Classifications. . Pediatr Ther. 2022;S5(002):1.

3. Meng CY, Noor PJ, Ismail A, Ahid MF, Zakaria Z. Cytogenetic Profile of de novo Acute Myeloid Leukemia Patients in Malaysia. Int J Biomed Sci. 2013;9(1):26-32.

4. Kumar CC. Genetic abnormalities and challenges in the treatment of acute myeloid leukemia. Genes Cancer. 2011;2(2):95-107.

5. Rorvik SD, Torkildsen S, Bruserud O, Tvedt THA. Acute myeloid leukemia with rare recurring translocations-an overview of the entities included in the international consensus classification. Ann Hematol. 2024;103(4):1103-19.

6. Chen G, Zhou W, Gong D, Li Y, Huang S, Wang N, et al. Loss of X chromosome predicts favorable prognosis in female patients with t(8;21) acute myeloid leukemia. Leuk Lymphoma. 2020;61(5):1168-77.

[Downloaded from ijbc.ir on 2026-11-24]

[DOI: 10.66224/ijbc.17.4.14]

7. Abla O, Dror Y, Shago M. Translocation (X;10) in a child with therapy-related acute myeloid leukemia following chemotherapy for Ewing's Sarcoma. Cancer Genet Cytogenet. 2007;178(2):168-9.

8. Manabe M, Tanizawa N, Nanno S, Hagiwara Y, Asada R, Koh KR. A rare der(10)t(X;10)(p11.2;p11.2) in an elderly patient with therapy-related acute myelomonocytic leukemia. EJHaem. 2022;3(1):256-8.

9. Bennour A, Sennana H, Zaier M, Ouahchi I, Mrad Z, Ben Youssef Y, et al. Translocation t(X;10)(p10;p10): a rare chromosomal abnormality in a new born female with acute myeloid leukemia. Med Oncol. 2012;29(2):1134-6.

10. Heim S, Bekassy AN, Garwicz S, Heldrup J, Kristoffersson U, Mandahl N, et al. Bone marrow karyotypes in 94 children with acute leukemia. Eur J Haematol. 1990;44(4):227-33.

11. Lelong F, Chretien P, Jouault H, Bayani N, Bernaudin F, Lemerle S. A case of peroxidase-positive acute leukaemia expressing only T lineage lymphoid markers. Br J Haematol. 1994;86(1):195-7.

12. Wong KF, Hayes KJ, Huh YO, Albitar M, Glassman AB. Translocation (X;10)(p10;p10): A rare but nonrandom chromosomal abnormality in acute leukemia of myeloid differentiation. Cancer Genet Cytogenet. 1996;86(2):153-5.

13. Chen CY, Tai CH, Tsay W, Chen PY, Tien HF. Prediction of fatal intracranial hemorrhage in patients with acute myeloid leukemia. Ann Oncol. 2009;20(6):1100-4.

14. Huang N, Zhou J, Lu W, Luo L, Yuan H, Pan L, et al. Characteristics and clinical evaluation of X chromosome translocations. Mol Cytogenet. 2023;16(1):36.

[Downloaded from ijbc.ir on 2026-11-24]

[DOI: 10.66224/ijbc.17.4.14]