

Synovial Sarcoma of the Head and Neck: A Case of Childhood Soft Tissue Sarcoma

Aazam-al-sadat Hashemi¹, Mahboubeh Abrishamkar¹, Reza Rahavi¹

1. Shahid Sadoughi Hospital, Yazd University of Medical Sciences, Yazd, Iran

Corresponding Author: Assistant Professor of Pediatric Hematology and Oncology, Shahid Sadoughi Hospital, Yazd University of Medical Sciences, Yazd, Iran. P.O. Box: 8916886938, Tel: +98(351)8224000, Fax: +98(351)8224100, E-mail: rdc_yazd@yahoo.com

Abstract

Although rare, synovial sarcoma is the most common malignant non-rhabdomyosarcomatous soft tissue sarcoma in children and adolescents. Synovial sarcoma typically involves the soft tissues of the extremities, especially near large joints, but it can occur anywhere in the body in locations far from joint spaces. Although this tumor typically affects adults in their fourth decade of life, nearly half of the reported cases have been children and adolescents.

We report a rare case of head and neck synovial sarcoma presented with tonsillar hemorrhage and painful facial contracture. Cervical computed tomography (CT) scan with contrast injection showed an asymmetrical respiratory tract image. Significant thickening of right (anterior) parapharyngeal soft tissue was revealed indicating a soft tissue mass. The mass was completely resected in a surgical procedure. In pathological examination of the mass, biphasic synovial sarcoma was reported.

At first, we treated the patient with VIE (Vincristin, Ifosfamide, Etoposide), but because of the severe neutropenia and hemorrhagic cystitis, we changed the protocol to VAC (Vincristin, Actinomycin, Cyclophosphamide).

The girl is 6 years old now and in a good condition without any pain or bleeding. Also, she has a normal cervical CT scan after more than two years. She is followed up every week and receives monthly Vincristin.

Keywords: synovial sarcoma, pediatrics

Introduction

Synovial sarcoma (SS) is the most common non-rhabdomyosarcomatous childhood soft-tissue sarcoma, with an annual incidence rate of 0.7 per million in children and adolescents younger than 20 years of age in the United States.¹ The mean age of patients at the time of diagnosis is in the third decade of life, with 31% of the cases being adolescents younger than 20 years of age.²

Recently, A specific chromosome aberration has been reported in synovial sarcoma. The translocation t (X; 18) (p11.2; q11.2) is believed to play a causative role in the development of synovial sarcoma.³ Synovial sarcoma usually involves the extremities, especially the lower extremities around the knees.⁴ SS arises in the para-articular regions, mainly in the tendons, tendon sheaths, bursal structures, and less frequently, in the fascial structures and ligaments.⁵

The disease is unique in its differentiation into two elements: epithelial cells with glandular components and spindle cells.

Case Report

A 4-year-old girl was admitted to our hospital due to painless tonsillar bleeding with fresh blood. The patient was also suffering from pain in the right ear and the right side of her face due to painful contractures of facial muscles for one year. The pain often occurred after coughing, chewing, and laughing. Based on the suspicious diagnosis of focal epilepsy, carbamazepin was administered but it was not helpful.

Physical examination revealed tonsillar bleeding, bulging of the right tonsil, a palpable submandibular mass with tenderness and some lip deviation to right. There was no evidence of metastasis to lung or other sites. Cranial nerves were normal in physical exam.

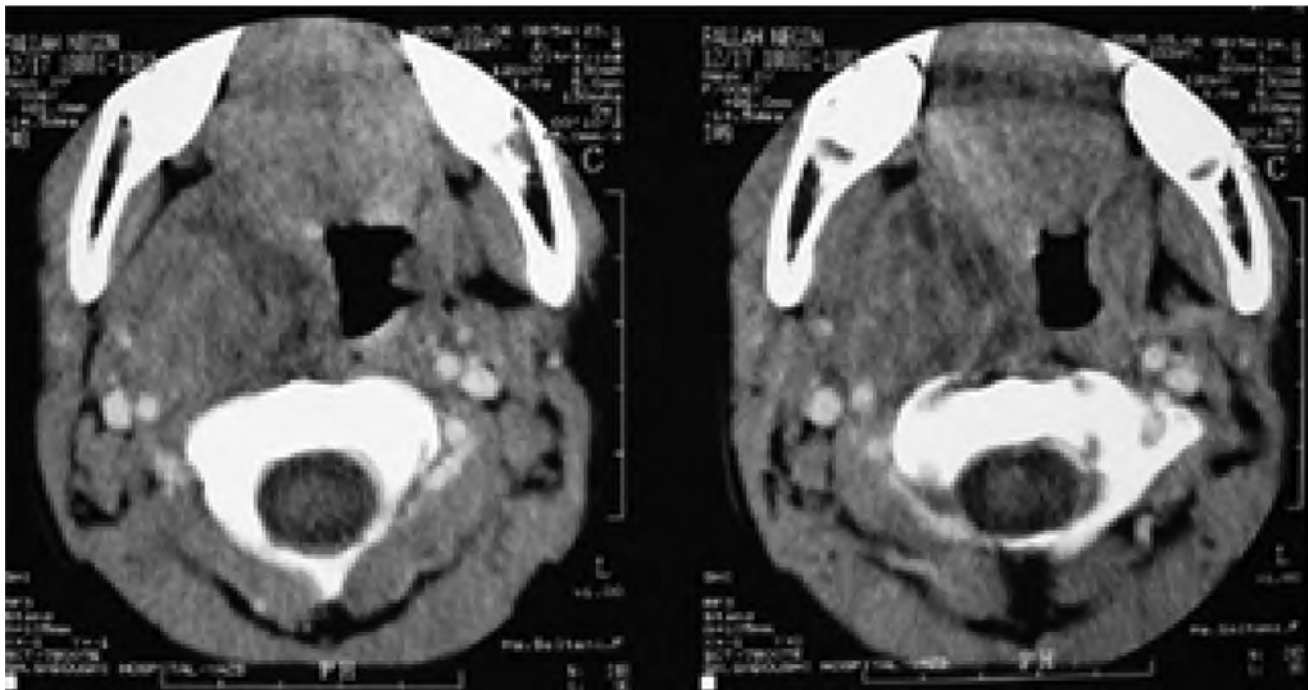


Figure 1: A 4-year-old girl's Cervical CT scan with contrast injection with synovial sarcoma before the surgery: Significant thickening of right (anterior) Para pharyngeal soft tissue was seen in the zone that indicate a soft tissue mass

Cervical computed tomography (CT) scan with contrast showed an asymmetrical respiratory tract image. Significant thickening of right (anterior) parapharyngeal soft tissue was seen indicating a soft tissue mass. This capsulated mass was about 4 cm in diameter, well defined, and similar to a vascular or nervous mass.

MRI showed, in precontrast T1W, T2W sagittal and post-contrast T1W axial and coronal images a T1W hypointense, T2W iso-hyperintense mass in the right prestyloid parapharyngeal space. A small cystic area was located in the medial lower portion of the lesion. This mass was enhanced with contrast injection and had caused medial deviation of lateral pharyngeal wall. Asymmetry of pharyngeal cavity was seen. The lesion was located adjacent to the right carotid artery but right carotid artery and jugular vein appeared intact. It seemed that there was no communication between the deep portion of the right parotid and the lesion. The visible part of the spinal cord, cervical vertebra, and posterior fossa appeared normal.

Chest CT scan with contrast showed a normal vascular view in pulmonary and mediastinal window. There was no sign of a mediastinal mass or hilar lymphadenopathy. Lung tissue was normal without signs of collapse, consolidation or plural effusion. Bronchial tissue was normal, too.

Brain and cervical spine MRIs were normal. Vascular tissue was intact.

The mass was completely resected through surgery and sent for pathologic study. In microscopic study, the mass consisted of fragments of fibrovascular tissue and some skeletal muscle with extensive tumoral infiltrations. Pathologic characteristics included:

- marked predominance of spindle cells arranged in solid sheets and interlacing bundles with relatively uniform fusiform oval nuclei.
- Presence of few small foci of epithelial differentiation in the form of small tubules.
- few small foci of hyaline change, rarely combined with nuclear palisading.
- a mitotic rate of lower than 1/10 hpf.
- Foci of recent and old hemorrhage but no necrosis.

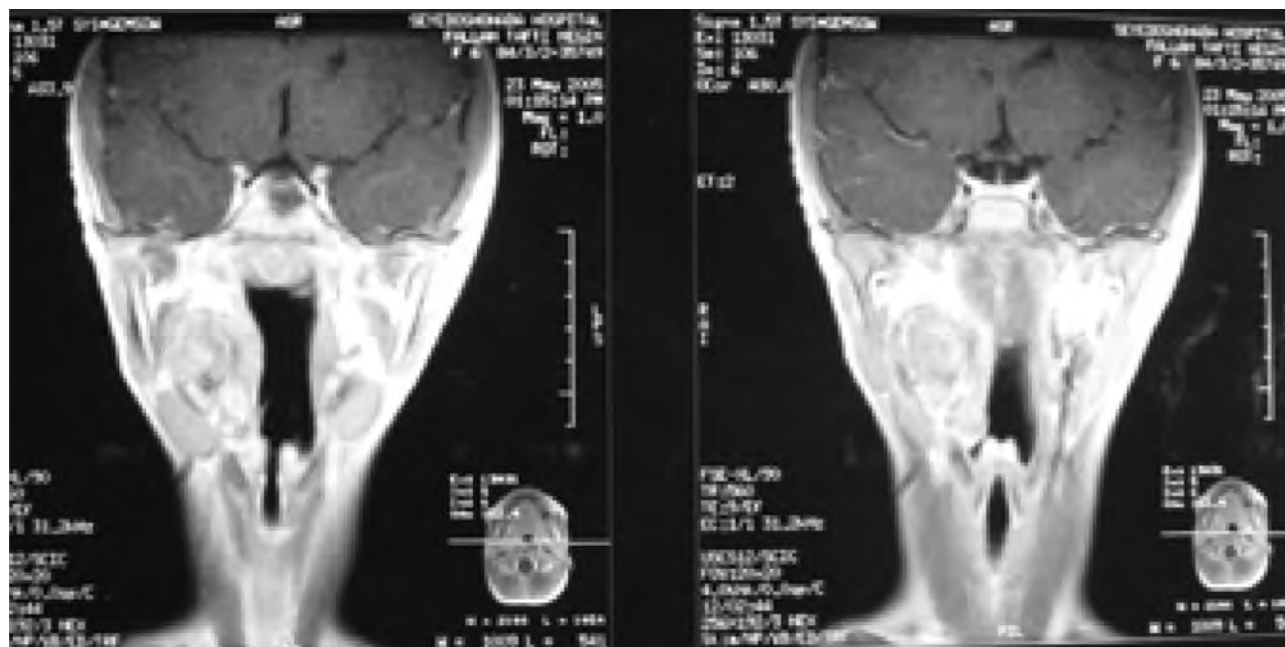


Figure 2: A 4-year-old girl's Head and neck coronal MRI before the surgery: there is T1 W hypo, T2 W iso-hyperintense mass at the right prestyloid Para pharyngeal space

In immunohistochemistry EMA and cytokeratin were focally positive staining while SMA was negative.

The pathologic diagnosis of the mass was biphasic synovial sarcoma.

Discussion

Synovial sarcoma can occur at all ages but most frequently affects young adults and adolescents (6). Synovial sarcomas often arise adjacent to joints, especially around the knees. These tumors do not originate from synovial tissues, but rather from pluripotential mesenchymal cells near or even remote from articular surfaces.^{6,7} In the head and neck, the hypopharynx is the most commonly involved site perhaps because of the abundant synovial tissue at the hypopharynx. Other locations in the head and neck reported in the literature include the masticator space, parapharyngeal space, sinonasal region, and pharynx.⁷

Usually, synovial sarcomas manifest as predominantly solid masses on CT scans or MRI images with well-defined smooth margins. Infiltration of the adjacent soft tissue is a less frequent finding. The lesions may appear as either

a homogeneous or heterogeneous mass, according to the degree of hemorrhage or necrosis. About half of the cases in the previous reports were those with homogeneous lesions.⁸

Approximately 30% of synovial sarcomas contain calcifications that may be apparent on the imaging study.⁷ The presence of calcifications tends to be associated with a better survival.^{9,10} In our case, no visible calcification was seen.

The most common presenting symptom is a painless mass that has been present for several weeks to years in the soft tissues of the lower extremity.³ Four other patterns of presentation also exist: a pre-tumor phase of pain and tenderness without a mass, acute arthritis or bursitis, a chronic contracture, and a tumor noted after an episode of trauma.¹¹

Since 1964, 59 patients between 2 to 22 years of age (mean: 12.7 years) have been treated at our institution for synovial sarcomas in the following sites: lower extremity ($n = 35$), upper extremity ($n = 11$), head and neck ($n = 4$), groin ($n = 2$), pelvis ($n = 2$), and other sites ($n = 5$).¹¹

An optimal approach to the treatment of synovial sarcoma remains undefined because no prospective clinical trials have compared different

therapeutic approaches.^{12,13} Complete surgical resection of the primary tumor is the mainstay of treatment. Adjuvant radiotherapy to treat microscopic residual disease after surgery provides excellent local control and obviates amputation for most patients with extremity tumors. The role of adjuvant chemotherapy remains controversial, and the small number of randomized prospective trials complicates interpretation of results. Most regimens that have shown activity in patients with a measurable disease include doxorubicin with or without an alkylating agent (cyclophosphamide or ifosfamide). Despite the chemosensitivity of synovial sarcoma, some series have failed to show a significant improvement in survival with addition of chemotherapy. Chemotherapy is probably beneficial only for those with high-risk features of distant disease recurrence, such as a large tumor size, invasion, and high histological grade. Prospective clinical trials to evaluate the benefit of adjuvant chemotherapy in the treatment of synovial sarcoma are needed.¹¹

The multimodality treatment approach has improved the prognosis of children with synovial sarcomas. Synovial sarcomas are reported to bear a better prognosis in childhood than in adulthood.¹⁴ Schmidt et al. reported that the survival rate at 7 years was 73 %.¹⁴ Pappo et al. in 1994 described an overall 5-year survival rate of 65 % in pediatric patients with synovial sarcoma.¹⁵

In this case, the mass was completely resected through surgery and sent for pathologic evaluation. At first we treated the patient with VIE (Vincristin, Ifosfamide, Etoposide), but because of the severe neutropenia and hemorrhagic cystitis, we change the protocol to VAC (Vincristin, Actinomycine, Cyclophosphamide).

Now the girl is 6 years old and in a good condition without any pain or bleeding. Also, she has a normal cervical CT scan after more than two years. She is followed up every week and receives monthly Vincristin.

References

1. Ries LAG, Smith MA, Gurney JG. Cancer incidence and survival among children and adolescents: U.S. Surveillance, Epidemiology, and End Results (SEER)

Program; 1975–1995. Bethesda, MD, National Cancer Institute. NIH Publication; 1999. 4649-99.

2. Weiss SW, Goldblum JR: Malignant soft tissue tumors of uncertain type: Goldblum JR, Weiss SW. Enzinger and Weiss's Soft Tissue Tumors. 4th ed. St. Louis, MO, Mosby; 2001. 1483–1509

3. Fligman I, Lonardo F, Jhanwar SC, Gerald WL, Woodruff J, Ladanyi M. Molecular diagnosis of synovial sarcoma and characterization of a variant SYT-SSX2 fusion transcript. *Am. J. Pathol*; 1995. 147: 1592-9.

4. Duh MJ, Gentili A, Masih S. Synovial Sarcoma. West Los Angeles Veterans Affairs Medical Center. Updated; 2007.

5. Miser JS, Triche TJ, Kinsella T. Other soft tissue sarcomas of childhood. In: Pizzo PA, Poplack DG: Principles and Practice of Pediatric Oncology, 3rd ed. Philadelphia, PA, Lippincott-Raven; 1997. 865–88.

6. Hirsch RJ, Yousem DM, Loevner LA. Synovial sarcomas of the head and neck: MR findings. *AJR Am J Roentgenol*; 1997. 169: P. 1185-88.

7. Rangheard A, Vanel D, Viala J. Synovial sarcomas of the head and neck: CT and MR imaging findings of eight patients. *AJNR Am J Neuroradiol*; 2000. 22: 851-7.

8. Park JK, Ham SY. Synovial Sarcoma of the Head and Neck: A Case of Predominantly Cystic Mass. *American Journal of Neuroradiology*; 2004. 25: 1103-5

9. Sigal R, Chancelier MD, Lubinski B. Synovial sarcomas of the head and neck: CT and MR findings. *AJNR Am J Neuroradiol*; 1992. 13: 1459-62.

10. Mamelle G, Richard J, Lubinski B. Synovial sarcoma of the head and neck: an account of four cases and review of the literature. *Eur J Surg Oncol*; 1986. 12: 347-9.

11. McCarville MB, Spunt SL. Synovial Sarcoma in Pediatric Patients. *AJR*; 2002. 179: 797-801.

12. Miser JS, Triche TJ, Kinsella TJ, Pritchard DJ. Other soft tissue sarcomas of childhood: Pizzo PA, Poplack DG, eds. Principles and practice of pediatric oncology, 3rd ed. Philadelphia: Lippincott-Raven; 1997. 865-88

13. Brennan MF, Alektiar KM, Maki RG. Sarcomas of the soft tissues and bones. In: DeVita VT Jr, Hellman S, Rosenberg SA, eds. Cancer: principles and practice of oncology, 6th ed. Philadelphia: Lippincott Williams & Wilkins; 2001. 1841-91.

14. Schmidt D, Thum P, Harms D, Treuner J. Synovial sarcoma in children and adolescents. A report from the Kiel Pediatric Tumor Registry. *Cancer*; 1991. 67: 1667-72.

15. Pappo AS, Fostanesi J, Luo X, Rao BN, Parham DM, Hurwitz C et al. Synovial sarcoma in children and adolescents: The St Jude Children's Research Hospital experience. *Clin. Oncol*; 1994. 12: 2360-66.