

Heterozygote Hemoglobin J Iran in Combination with Hemoglobin H Disease

Keikhaei B^{1*}, Galehdari H², Mohammadpour M³, Hamed M⁴

1- Research Center for Thalassemia and Hemoglobinopathy, Jundishapur University of Medical Sciences, Ahvaz-Iran

2- Department of Genetics, Shahid Chamran University, Research Center for Thalassemia and Hemoglobinopathy, Ahvaz, Iran

3- Anatomoclinical Pathologist, Ahvaz, Iran

4- Shafa Hospital, Ahvaz, Iran

*Corresponding Author: Keikhaei B, Email: keikhaeib@yahoo.com

Submitted: 29-07-2011, Accepted: 15-03-2012

Abstract

This is a report concerning a concurrent case of hemoglobin J Iran (Hb J Iran) and Hemoglobin H (Hb H) disease in an Iranian woman. The patient was coincidentally found during the course of routine pre-marital genetic counselling for her son. The diagnosis of heterozygote Hb J Iran for her son, ultimately led to the diagnosis of concurrent Hb J Iran and Hb H disease. The hematological examination of the patient showed a microcytic, hypochromic anemia, and hemoglobin electrophoresis on cellulose acetate media at alkaline PH depicted a profile of fast moving hemoglobins consisting of Hb J Iran, Hb Bart and hemoglobin H. Molecular analysis of alpha and beta chains of hemoglobin revealed a genotype of $-(\alpha)20.5/-\alpha3.7+\beta\beta77\text{ His}\rightarrow\text{Asp}$. To our knowledge, this is the first report of such patient with details of hematological and molecular analysis from south west Iran. This case report may provide a new insight into hemoglobin electrophoresis interpretation and hemoglobin disorders especially for health sector and genetic counsellors.

Key Words: Hemoglobin J Iran, hemoglobin H, hemoglobinopathies, Iran

Introduction

The most frequent Hb variants in south west Iran are Hb S followed by Hb D Punjab¹. The position of hemoglobin on cellulose acetate electrophoresis depends on the negative hemoglobin charges. Carrier subjects with Hb D heterozygous and Hb S heterozygous states have half normal Hb (Hb A) and half (or little lesser) Hb variant on cellulose acetate electrophoresis at alkaline PH. Among individuals with heterozygous states such as Hb E, Lepore, Knossos, K-Woolwich and Vicksburg, Koln and Zurich, the percent of Hb variants are very lower than hemoglobin A. These hemoglobin variants show a clinical picture identical to thalassemia syndrome². The Hb J Iran is a rare Hb variant in Iran³. Hb J Iran gives a negative charge to Hb and the $\beta77\text{ His}\rightarrow\text{Asp}$ makes a more potent chain compared to normal β chain to bind to α globin chain. Therefore, in Hb J Iran heterozygotes, the magnitude of Hb variant is higher than normal Hb A⁴. In the presence of α chain depletion such as Hb H disease (α -/-), the competition between normal β and $\beta77\text{ His}\rightarrow\text{Asp}$ to pair with remaining α chain leads to predominance of Hb variant. So, a more

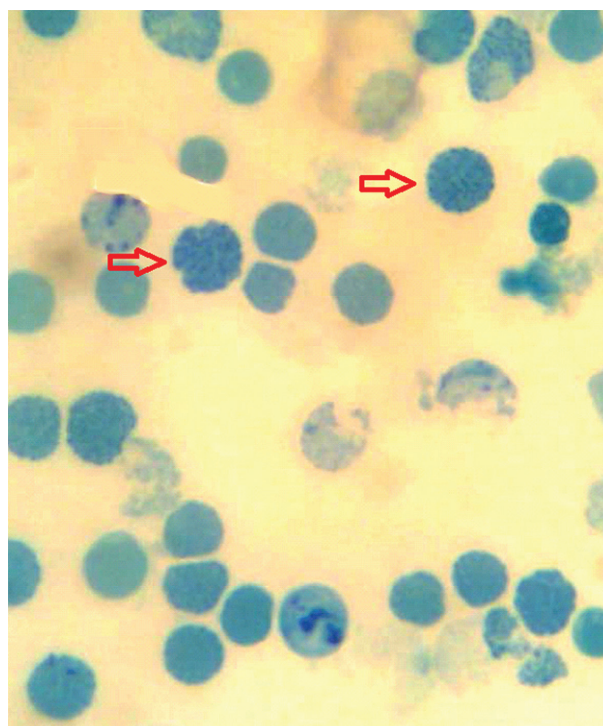


Figure 1: Peripheral blood smear: Supravital staining shows red blood cells resembling a golf ball.

severe depletion of α chain reserve may worsen the clinical manifestation of patients with both Hb J Iran and Hb H disease in comparison with Hb H disease alone.

Report of the case

A 60-year-old woman came to a private clinic to follow her son's pre-marital laboratory examination. She was detected coincidentally through her son pedigree. She had two children, both affected with Hb J Iran heterozygous state. At first visit, she appeared with pallor and breathlessness. She gave a long term history of using iron and folate supplement and only one episode of blood transfusion. In initial physical examination, the positive findings were: weight: 60 kg, height: 155 cm, sub conjunctivae pallor, normal face bone, pulse rate 120/min and respiratory rate 20/min. The spleen and liver were palpable 4 and 2 cm below costal margin, respectively.

A written informed consent for laboratory tests, DNA analysis and journal reporting was taken from the patient. Initially, 4 ml blood sample was drawn and collected in EDTA for cell blood count and Hb electrophoresis and supravital staining. Hematological parameters were determined by using an automated Coulter Cell Counter [Sysmex k1000], and hemoglobin electrophoresis was performed on cellulose acetate at pH = 8.6.

Genomic DNA from the proband was extracted and processed by routine salting out method. Alpha and beta globin genes were analyzed using reverse dot blot according to the manufacturer's instruction (Vienna Lab Co.). In addition, the whole beta globin gene was amplified by two primer pairs:

Primer pair (5- AGGTACGGCTGTCATCACTTAGA-3 and 5- TTCCAAATAGTAATGTACTAGGCA-3) for exons 1 and 2 and primer pair (5-TCTCTTTCTTTCAGGGCAATAATG-3 and 5-

CTTTATGTTTTAAATGCACTGACC-3) for exon 3, which generated products with 970 and 626 base pair lengths, respectively. The PCR products were directly sequenced by automated sequencer (ABI 3770).

The hemoglobin concentration was 8.3g/dl, hematocrit: 30.3, reticulocyte count: 7%, mean corpuscular volume: 64.2fl, mean corpuscular hemoglobin: 17.6 pg, mean corpuscular hemoglobin concentration: 27.4g/dl, red blood cell count: 4.72×10^{12} cells/litre, red cell distribution width: 25.3%, total bilirubin: 3.2mg/dl, direct bilirubin: 0.5 mg/dl and serum ferritin: 449ng/ml. Hemoglobin electrophoresis on alkaline acetate cellulose showed Hb H: 2%, Hb Bart: 1.3%, Hb J Iran: 49%, Hb A1:46.7%, Hb F: 0.1% and Hb A2:0.9%. Other findings consisted of Uric acid: 6.5 mg/dl, calcium: 9 mg/dl, phosphor: 4.5 mg/dl, AST: 44U/L, ALT: 41 U/L and NRBC: 50/100WBC. The patient's

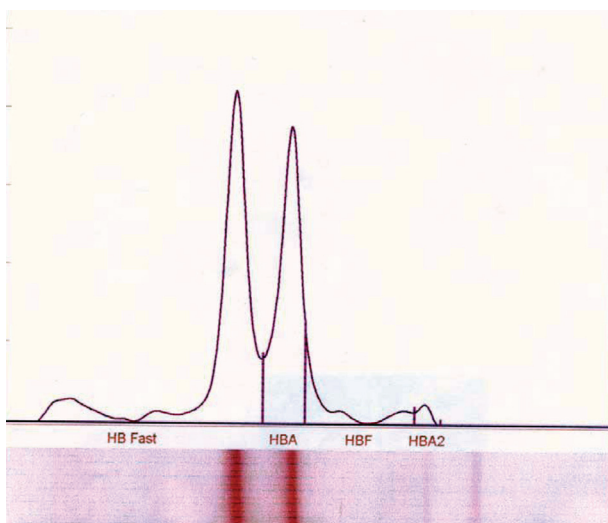


Figure 2: Hb- electrophoresis result shows fast moving hemoglobins consisting of from left to right: Hb-H, Hb-Bart, Hb-J Iran and other normal hemoglobins illustrated on the diagram.




Figure 3: Results of the reverse dot blot indicated two deletions (-3.7 and -20.5) causing loss of three alpha chains (Hb-H) in the patient.

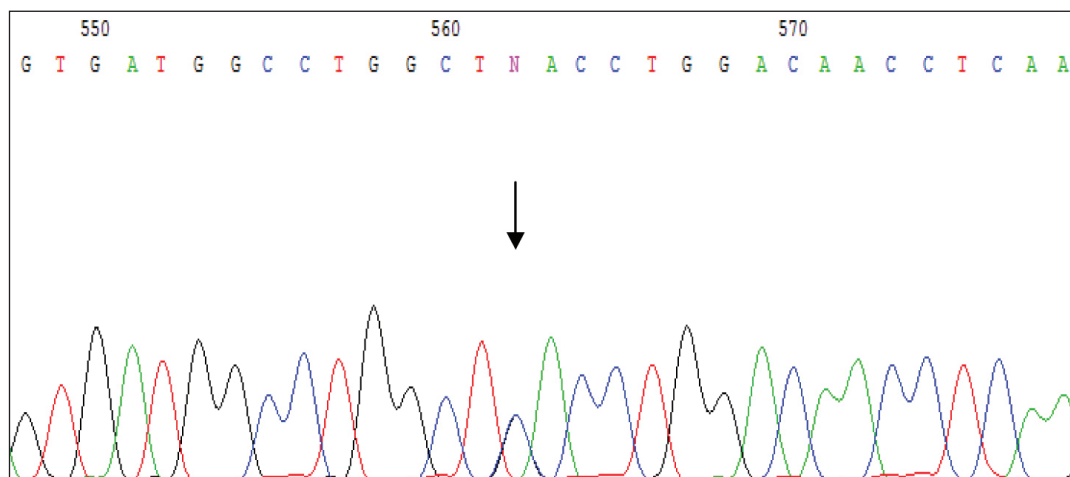


Figure 4: Autoradiogram of the sequencing reaction revealed a heterozygous cd77 (C>G) in the patient (arrow indicates the position of the nucleotide change).

chest X-ray was normal. Her peripheral blood supravital staining and her Hb electrophoresis are illustrated in Figures 1 and 2 respectively. Alpha and Beta globin genes of proband are depicted in Figure 3. Direct sequencing of the beta globin gene confirmed the $\beta 77$ His \rightarrow Asp. Sequencing results are shown as autoradiogram in Figure 4.

Discussion

Hb J-Iran [$\beta 77$ CAC>GAC His \rightarrow Asp] is an abnormal hemoglobin, reported first in Iran³. In Turkey, the first Hb J-Iran heterozygote was described by Arcasoy et al.⁵

Hb J-Iran is defined as the histidine at 77 β position replaced by aspartic acid³. This mutation produces a β subunit variant with an additional negative charge equal to 1.5 charge units. Thus the $\beta 77$ His \rightarrow Asp chain has more chance to couple with positively charged α chain in competition with normal β chain, thereby allowing more formation of Hb J Iran than normal Hb A in heterozygous state. This Hb variant shows a fast electrophoretic mobility⁴. Another fast moving Hb is Hb H. It is composed of four β globin chains and is produced in response to a severe shortage of alpha (α) chains. As mentioned before, Hb H behaves as a fast moving Hb like Hb J Iran. Hb H disease is divided into two groups, deletional and nondeletional. The clinical outcomes of patients with deletional type are better than nondeletional type⁶. In Iran, The most common type of Hb H disease is $-\alpha 3.7/-$ Med.⁷, but the molecular basis of our patient was $-(\alpha)20.5/-\alpha 3.7$. Hb Bart ($\gamma 4$) is another fast moving Hb². The presence of Hb Bart in the current case is

due to γ chain excess. The cause of γ globin excess is related to α chain reserve depletion. The α chain, partly couples with $\beta 77$ His \rightarrow Asp and partly with normal β subunit. The remaining α chain is not sufficient to meet γ globin chain.

Hb J Iran even in homozygous states is a silent Hb and does not create any health problem⁴. Hb H disease is usually presented with a mild to moderate anemia. However, some deletional types may need occasional transfusion therapy⁸.

The co-inheritance of Hb H disease and several other heterozygote Hb variants such as S, C, E and β New York (codon 113 GTG \rightarrow GAG or Val \rightarrow Glu),

Hb J Bangkok (codon 56 GGC \rightarrow GAC or Gly \rightarrow Asp), Hb Pyrgos (codon 83 GGC \rightarrow GAC or Gly \rightarrow Asp), and Hb Hope (codon 136 GGT \rightarrow GAT or

Gly \rightarrow Asp) has been described⁹⁻¹⁵. These syndromes give rise to different clinical manifestations.

There is only one report similar to the present report by Rahbar et al. but they have not reported hematologic parameters and propositus genotype³. Bunn et al. have reported a case with association of Hb J Baltimore and α thalassemia minor ($-\alpha/-\alpha$). Therefore we think that the present case is the first description of association between Hb J Iran and Hb H disease with comprehensive hematologic and genetic report from Iran.

Conclusion

The association of Hb J Iran /Hb H disease is very rare. The $\beta 77$ His \rightarrow Asp gives an additional negative charge to β subunit that can attract more remaining α chain and may worsen the clinical manifestations

of Hb H disease.

ACKNOWLEDGEMENT

We are grateful to Dr Mohammad pour's and Dr Galehdari's staff for their valuable technical assistance.

References

1. Keikhaei B, Galehdari H, Salehi B. Co-inheritance $\alpha\alpha\alpha$ anti 3.7 triplication with hemoglobin D/ $\beta 0$ thalassemia: A case report from South west of Iran. *Journal of Medical Genetics and Genomics*. 2010; 2(2), 18-23.
2. Bunn HF. Subunit assembly of hemoglobin: an important determinant of hematologic phenotype. *Blood*. 1987;69(1):1-6.
3. Rahbar S, Beale D, Isaacs WA, Lehmann H. Abnormal haemoglobins in Iran. Observation of a new variant--haemoglobin J Iran (α -2- β -2 77 His--Asp). *Br Med J*. 1967 18;1(5541):674-7.
4. Rahbar S, Bunn HF. Association of hemoglobin H disease with Hb J-Iran (β 77 His----Asp): impact on subunit assembly. *Blood*. 1987;70(6):1790-1.
5. Arcasoy A, Turhanoglu I, Gøzdasoğlu S, Ogur G. First observation of hemoglobin J-Iran [β 77 (EF1)His----Asp] in Turkey. *Hemoglobin*. 1986;10(2):209-13.
6. Higgs DR., Bowden DK. (2001) Clinical and laboratory features of the -thalassemia syndromes. In: Steinberg MH, Forget BG, Higgs DR, Nagel RL, eds. *Disorders of Hemoglobin; Genetics, Pathophysiology, and Clinical Management*. Cambridge, United Kingdom: Cambridge University Press; 431-469.
7. Yavarian M, Karimi M, Zorai A, Harteveld CL, Giordano PC. Molecular basis of Hb H disease in southwest Iran. *Hemoglobin*. 2005;29(1):43-50.
8. Mirabile E, Samperi P, Di Cataldo A, Poli A, La Spina M, Schilirò G. Phenotype-genotype correlation in Sicilian patients with Hb H. *Eur J Haematol*. 2000;65(5):306-9.
9. Matthay KK, Mentzer WC Jr, Dozy AM, Kan YW, Bainton DF. Modification of hemoglobin H disease by sickle trait. *J Clin Invest*. 1979;64(4):1024-32.
10. Giordano PC, Harteveld CL, Michiels JJ, Terpstra W, Batelaan D, van Delft P, et al. Atypical HbH disease in a Surinamese patient resulting from a combination of the -SEA and - α 3.7 deletions with HbC heterozygosity. *Br J Haematol*. 1997;96(4):801-5.
11. Fucharoen S, Winichagoon P, Thonglairuam V. Beta-thalassemia associated with alpha-thalassemia in Thailand. *Hemoglobin*. 1988;12(5-6):581-92.
12. Chan V, Chan TK, Tso SC, Todd D. Combination of three alpha-globin gene loci deletions and hemoglobin New York results in a severe hemoglobin H syndrome. *Am J Hematol*. 1987;24(3):301-6.
13. Fucharoen S, Ayukarn K, Sanchaisuriya K, Fucharoen G. Atypical hemoglobin H disease in a Thai patient resulting from a combination of alpha-thalassemia 1 and hemoglobin Constant Spring with hemoglobin J Bangkok heterozygosity. *Eur J Haematol*. 2001;66(5):312-6.
14. Jetsrisuparb A, Sanchaisuriya K, Fucharoen G, Fucharoen S, Wiangnon S, Komwilaisak P. Triple heterozygosity of a hemoglobin variant: hemoglobin Pyrgos with other hemoglobinopathies. *Int J Hematol*. 2002;75(1):35-9.
15. Svasti S, Yodsowon B, Sriphanich R, Winichagoon P, Boonkhan P, Suwanban T, et al.