

Clear cell sarcoma of the hand: a case of malignant melanoma of soft parts

Tavakoli R ¹, Sheibani K ^{2*}, Khayatkhoei M ³

1- Orthopedic surgeon, assistant professor, Imam Hossein Medical Center, Shahid Beheshti University of Medical Sciences

2- Chief Researcher, Clinical Research and Development Center, Imam Hossein Medical Center, Shahid Beheshti University of Medical Sciences

3- General practitioner, Imam Hossein Medical Center, Shahid Beheshti University of Medical Sciences

***Corresponding Author:** Kourosh Sheibani, Email: sh_kourosh@hotmail.com

Submitted: 28-04-2011, Accepted: 16-07-2011

Abstract

A case is reported with clear cell sarcoma (CCS) of the hand. Early diagnosis of clear cell sarcoma is always difficult due to its slow growing nature, benign clinical appearance, lack of pigmentation in most cases, and relatively young age of patients which make it to clinically appear as a benign soft tissue tumor. We report a case of clear cell sarcoma of hand in a 56 year old male with a non-painful, soft tissue tumor. Following suspicious appearance, rapid growth of the tumor and complications due to limited movement of the fingers, it was decided to perform excisional biopsy in order to remove the tumor and perform histological assessment. According to microscopic findings and immunohistochemical results, clear cell sarcoma was diagnosed. Our case reminds that clear cell sarcoma can develop in locations such as hand and upper extremities which are not common places to find it, therefore it is important to consider clear cell sarcoma in differential diagnosis of malignancies in hand and upper extremities.

Key Words: Clear Cell Sarcoma, Malignant Melanoma of Soft Parts, Metastasis, Skin Cancer

Introduction

Clear cell sarcoma (CCS) which was initially described by Enzinger as "clear cell sarcoma of tendons and aponeuroses" is a very rare malignant soft tissue tumor representing a minority of all soft tissue sarcomas ^{1, 2, 3} CCS is also called malignant melanoma of soft parts (MMSP) because of histologic similarities with conventional melanoma.¹

CCS is a tumor with unknown etiology which has a melanocytic nature. This tumor affects all age ranges but is more common in young adults, between ages of 20 and 40 years. CCS is a rare tumor accounting for less than 1% of soft tissue sarcomas.^{1,4} The tumor develops mainly in the extremities especially in lower extremities. Approximately forty percent of tumors arise in the foot and ankle, followed by the knee, thigh, forearm, elbow, and shoulder and is less common in head, neck and trunk^{1,3}; however there are reports of CCS in the hand and fingers.⁵ CCS is usually deeply seated and is often bound to tendons and aponeuroses.¹ Diagnosis of CCS is rather difficult because of its slow growing nature, benign clinical appearance, lack of pigmentation in most cases and relatively young age of patient patients.^{1, 5, 6}

The differential diagnosis includes other soft tissue sarcomas like malignant fibrous histiocytoma, rhabdomyosarcoma, fibrosarcoma, liposarcoma, epithelioid sarcoma, and malignant Schwannoma.⁷ Benign differential diagnosis include numerous conditions such as interdigital neuromas, nodular fascitis, benign adnexal tumors, lipomas, and many others.⁶ These tumors commonly metastasize in spite of radical ablative surgery and adjuvant therapy and have high rates of local and regional recurrences thus they have poor prognosis.^{3, 6, 8}

In tumor marker assessment of CCS, Vimentin, HMB45^{9,10} and S-100^{11, 12, 13} are positive and there should be negative epithelial markers to rule out synovial sarcoma and negative FMA to rule out muscular tumors. However, pathological workups are not very specific for diagnosis of CCS and the most leading point in the diagnosis is having CCS in mind since the beginning of assessment and before analyzing the pathological results.

The authors have obtained the patient's informed written consent for print and electronic publication of this case report.

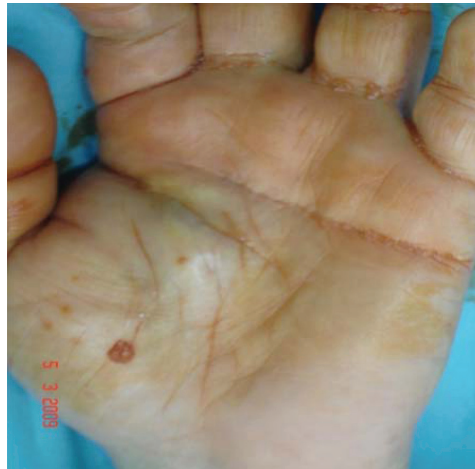

Figure 1: The lesion is irregular, firm and non-movable. It is not tender to palpation and has limited the movement of the index and middle fingers. It measures about 2 cm in diameter.

Case Report

A 56 year-old male presented with a non-painful, soft tissue tumor of the hand. The tumor was placed in the palmar surface of the left hand, close to the thumb and was irregular in shape, non-movable and firm to palpation. The patient did not have any tenderness in the area of the tumor. Size of the tumor was about 2cm × 1.5cm (Fig. 1). He indicated that the tumor first appeared eight months ago and was as small as a hazelnut in size and was not painful. He also stated that over the past eight months, the tumor had enlarged and limited the movement of his index and middle finger.

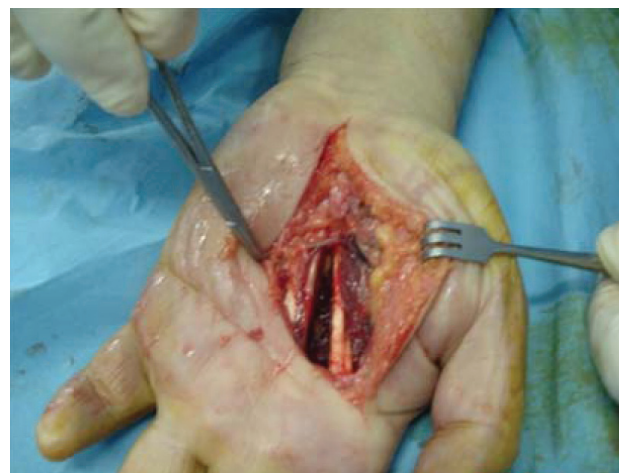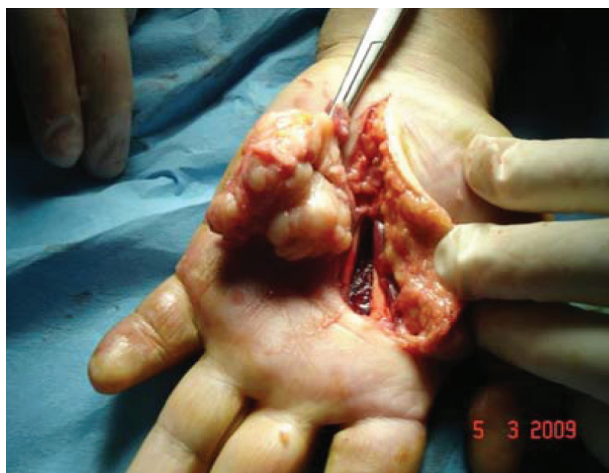Patient gave a history of trauma to his little finger about 20 years ago while he was involved in

Iraq-Iran war. The trauma had caused amputation of distal phalange of his little finger. Other than that, there was no history of resent trauma. Further questioning revealed no history of previous nodule or nevi on any part of his body. The patient implied that he had consulted three different doctors for this problem who suggested watching the lesion considering it a benign tumor.

Following suspicious appearance, rapid growth of the tumor and complications due to limited movement of the fingers, it was decided to perform excisional biopsy in order to remove the tumor and perform histological assessment.

Surgical Removal

The patient underwent local removal of the



Figures 2, 3: The tumor was nodular and firmly attached to adjacent structure and epidermal tissue.

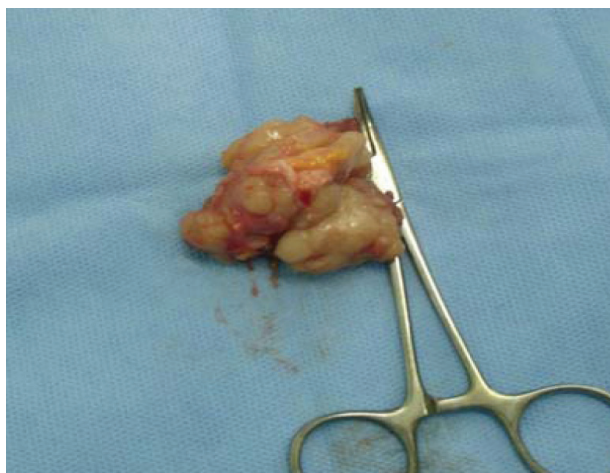

Figure 4: After removal, the tumor was a lobulated soft tissue mass, with 3×4×4 cm measurement.

tumor. A curve incision which was parallel with longitudinal thenar crease was planned to gain better exposure. The tumor was nodular and firmly attached to adjacent structure and epidermal tissue (Fig. 2, 3). The tumor was removed with blunt dissection and sent to pathology as an excisional biopsy for evaluation (Fig. 4). Redundant skin was also sent to pathology with the tumor.

Histology Report

The specimen was clinically diagnosed as “soft tissue mass”. Macroscopic examination showed a lobulated tumoral tissue measuring 3×4×4 cm, with a tan to yellow color and rubbery consistency in cut section (fig. 4).

Microscopic examination of H&E stained

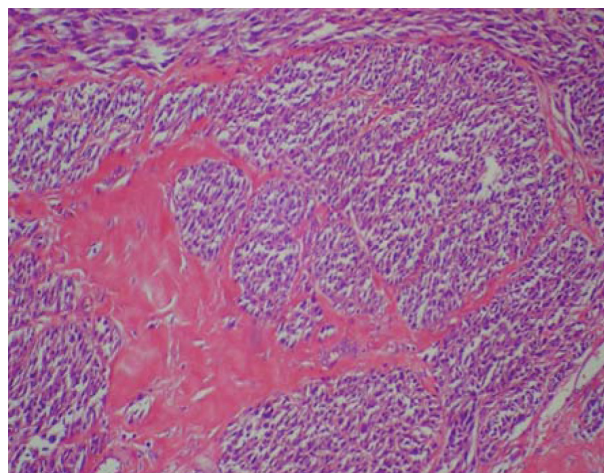


Figure 5: Tumor consisted of nests and fascicles of uniform clear and spindle-shaped cells separated with delicate collagenous septa.

prepared sections demonstrated a partially well circumscribed tumor composed of uniform spindle shaped cells with ovoid vesicular nuclei and pale eosinophilic or clear cytoplasm arranged in nests and fascicles, mostly producing an alveolar pattern. The fascicles were separated by delicate fibrous septa (fig. 5) and contained a few mitotic figures (fig. 6). There was also an extensive area of necrosis in between tumor nests (fig. 7) and some bland appearing multinucleated giant cells were identified (fig. 8).

In special immunostaining the tumor cells were diffusely positive for S-100 protein, HMB45, vimentin (fig. 9, 10, 11) and partially positive for SMA (smooth muscle actin), and EMA (epithelial membrane antigen) but negative for cytokeratin

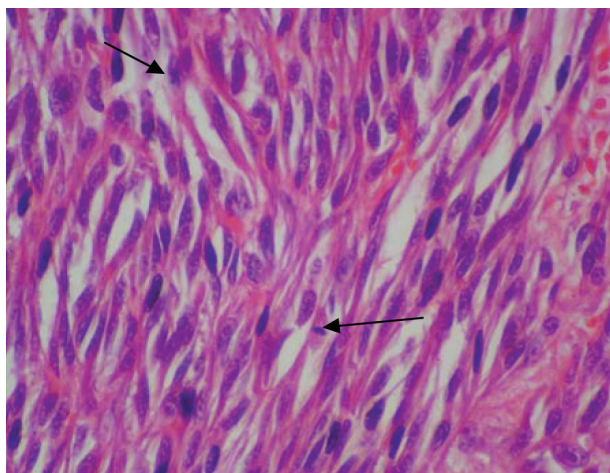


Figure 6: Scattered mitotic figures were seen within tumor nests.

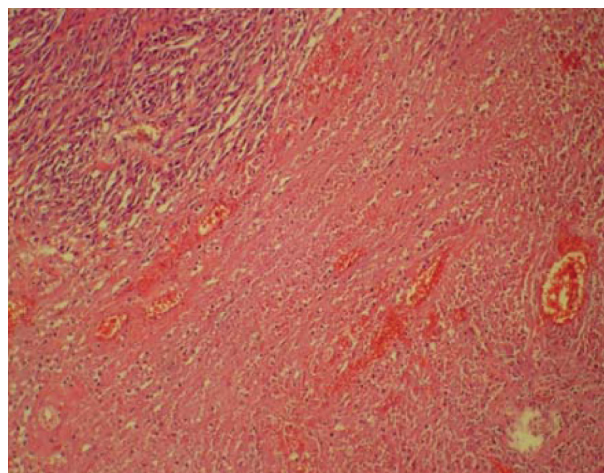


Figure 7: Areas of necrosis were seen in between tumor fascicles.

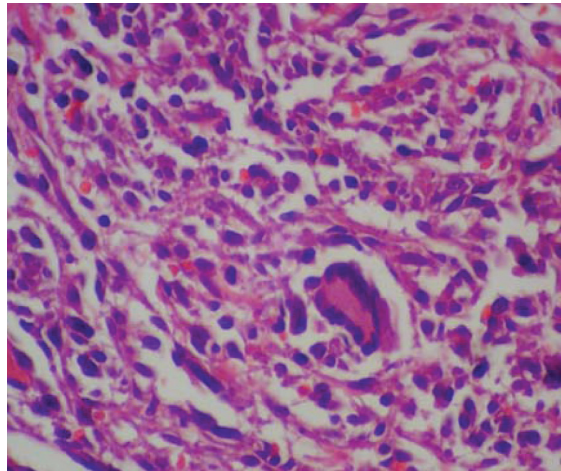


Figure 8: Bland multinucleated giant cells with peripheral nuclear arrangement scattered between tumor cells.

(CK) (fig. 12). Ki67 proliferative activity was about 15% of tumor cells (fig. 13). According to microscopic findings and immunohistochemical staining, clear cell sarcoma was histologically diagnosed.

Discussion

CCS tumor can lay in-situ for many years without any complication or change in size 1, 6 and then starts to grow rapidly⁸. A history of trauma is not uncommon in CCS.^{1, 6} CCS is known to appear mostly in lower extremities^{1,3, 6} however can also rarely occur in the hand, wrist and fingers.^{5,14, 15, 16} In our case CSS developed in patient's hand which is not a common place to see a CCS tumor. Even with having CCS in mind, the diagnosis is not easy and the primary lesion of CCS can be easily missed or considered a benign entity due to its slow growing nature, benign clinical appearance, lack of pigmentation in most cases and relatively young age of patients.^{1, 5,6} Although some reports indicate that CCS can cause mild pain or tenderness in early stages there are usually no epidermal changes

and the epidermis can be moved easily over the tumor and the lesion is not always tender.⁶ More troubling is that because of innocent presentation of the tumor in early stages, some patients may have symptoms for a long time (five or more years) before they seek medical attention and due to this delay and missed diagnosis, metastasis is frequently present in CCS at the time of diagnosis.³ This delay in prognosis was present in our case and the patient had consulted three different doctors for this problem who suggested watching the lesion considering it a benign tumor.

CCS has a high malignant potential and metastasis is common for this type of tumor.^{1, 6, 8} Once metastasis occurs the prognosis is dismal.⁸ Multiple literature reviews show that the size of the tumor is also important. Tumors smaller than 2cm have better prognosis¹ and tumors larger than 5cm have poor prognosis.^{8,17} Recurrence in CCS is very common^{1, 6, 8} and very late recurrence after 10 years is well recognized³ so, close clinical follow up of the CCS patients is necessary. Treatment should

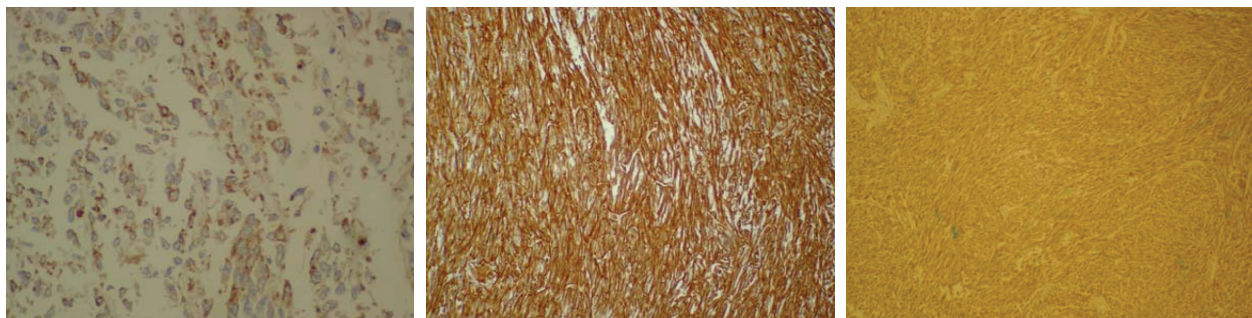


Figure 9, 10, 11: Clear cell sarcoma: tumor cells stain diffusely with antibodies to S-100 protein and HMB45 and Vimentin.

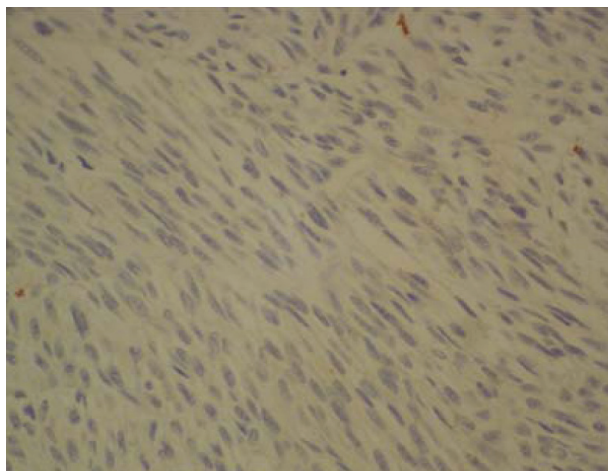


Figure 12: Clear cell sarcoma: tumor cells are negative for cytokeratin.

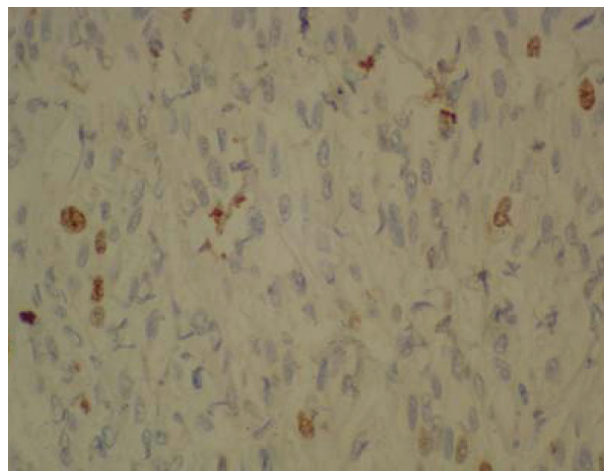


Figure 13: Clear cell sarcoma: tumor cells reveal variable Ki67 reactivity of about 15% in most portions.

be radical resection of the tumor followed by chemotherapy or radiotherapy^{1, 6, 18} however some studies indicate that chemotherapy or radiotherapy has minimal effect on stopping the recurrence of the CCS tumor particularly when there is an inadequate margin of excision.^{8,15,17}

In our case tumor diameter was over 2cm and less than 5cm which suggests better prognosis compared to tumors larger than 5cm in diameter. At the time of diagnosis, the patient underwent lymph node biopsy which was negative and ruled out metastasis. The patient received radiotherapy after removal of the tumor in order to minimize the chances of recurrence. Follow up CT scan examination six months after surgical removal was normal. At the time of this report (14 months after surgical removal), there is no evidence of metastasis thus the overall long-term prognosis of the patient looks good.

Conclusion

CCS can develop in locations such as hand and upper extremities which are not common places to find it, therefore it is important to consider CCS in differential diagnosis of malignancies in hand and upper extremities. A point to consider is the age of onset which was 56 in our patient. Although the common age of onset for CCS is known to be the third and fourth decade of life our case indicates a later onset which points to the fact that CCS should be considered in older patients as well.

References

1. Hermann G, Klein MJ, Springfield DS, Abdelwahab

- IF. Clear cell sarcoma (malignant melanoma of soft parts): case report and review of the literature. *Can Assoc Radiol J.* 2002 Oct;53(4):237-240.
2. Enzinger FM. Clear cell sarcoma of tendons and aponeuroses: an analysis of 21 cases. *Cancer.* 1965; 18:1163-74.
3. Chung EB, Enzinger FM. Malignant melanoma of soft parts. A reassessment of clear cell sarcoma. *Am J Surg Pathol.* 1983;7(5):405-13.
4. Kransdorf M, Murphey M: "Imaging of Soft Tissue Tumors." Philadelphia: WB Saunders, 1997.
5. Tyler G, Wirman J, Neale HW. Melanin containing clear cell sarcoma in a fingertip. Case report and review of the literature. *Hand.* 1980; 12(3):308-15.
6. Mackey SL, Hebel J, Cobb MW. Melanoma of the soft parts (clear cell sarcoma) : a case report and review of literature. *J Am Acad Dermatol* 1998; 38:815-19.
7. Prieskorn DW, Irwin RB, Hankin R. Clear cell sarcoma presenting as an interdigital neuroma. *Orthop Review* 1992;21(8):963-70.
8. Clark MA, Johnson MB, Thway K, Fisher C, Thomas JM, Hayes AJ. Clear cell sarcoma (melanoma of soft parts): The Royal Marsden Hospital experience. *Eur J Surg Oncol.* 2008; 34(7):800-804.
9. Hadjiyannakis MJ, Papadimitriou CA, Elemenoglou J: Clear cell sarcoma (malignant melanoma of soft parts): Presentation of two additional cases. *Eur J Surg Oncol* 1993;19:206-208.
10. Sonobe H, Furihata M, Iwata J, et al.: Establishment and characterization of a new human clear-cell sarcoma cell line, HS-MM. *J Pathol* 1993;169:317±322.
11. Kindblom LG, Lodding P, Angervall L: Clear cell sarcoma of tendons and aponeuroses: An

- immunohistochemical and electron microscopic analysis indicating neural crest origin. *Virchows Arch* 1983;401:109±128.
12. Mukai M, Torikata C, Iri H, et al.: Histogenesis of clear cell sarcoma of tendons and aponeuroses: An electron-microscopic, biochemical, enzyme histochemical, and immunohistochemical study. *Am J Pathol* 1984;114:264±272.
 13. Lombardi L, Rilke F: Ultrastructural similarities and differences of synovial sarcoma, epitheloid sarcoma, and clear cell sarcoma of the tendons and aponeuroses. *Ultrastruct Pathol* 1984;6:209-219.
 14. Yu SJ, Zhao ZG, Zang L, Lu HZ, Zhang HT, Xu L. Clinical treatment and prognosis for clear cell sarcoma: analysis of 19 cases. *Zhonghua Yi Xue Za Zhi*. 2008 Jun 3;88(21):1458-61.
 15. Pradhan A, Cheung YC, Grimer RJ, Peake D, Al-Muderis OA, Thomas JM, Smith M. Soft-tissue sarcomas of the hand: oncological outcome and prognostic factors. *J Bone Joint Surg Br*. 2008 Feb;90(2):209-14.
 16. Gürkan V, Ozger H. Sarcomas of the hand. *Acta Orthop Traumatol Turc*. 2007 Aug-Oct;41(4):286-90.
 17. Finley JW, Hanypsiak B, McGrath B, Kraybill W, Gibbs JF. Clear cell sarcoma: the Roswell Park experience. *J Surg Oncol*. 2001; 77(1):16-20.
 18. Ferguson PC. Surgical considerations for management of distal extremity soft tissue sarcomas. *Curr Opin Oncol*. 2005;17(4):366-9.