

# A case of Acquired Thrombotic Thrombocytopenic Purpura without Renal Dysfunction

Shahriari M <sup>1</sup>, Abdolkarimi B <sup>\*1</sup>, Mokhtari M <sup>2</sup>, Silavizadeh S <sup>1</sup>, Haghpanah S <sup>1</sup>

1. Hematology Research Center, Shiraz University of Medical Sciences, Shiraz, Iran.

2. Pathology department, Shiraz University of Medical Sciences, Shiraz, Iran.

**\*Corresponding Author:** Abdolkarimi B, Email: b.abdolkarimi@yahoo.com

Submitted: 06-08-2013 , Accepted: 12-11-2013

## Abstract

**Objective:** Thrombotic thrombocytopenic purpura (TTP) is the most malignant variant of microangiopathy that usually presents by typical symptoms including thrombocytopenia, hemolytic anemia, neurological abnormalities, fever and renal impairment.

**Report of the Case:** We report a 12-year-old male presented by cytopenia, fever, purpura on his extremities, seizure and lethargy. Peripheral blood smear revealed low platelet and increased schistocyte, but renal function tests were normal. Final diagnosis of TTP was confirmed by measuring ADAMTS-13 autoantibody (> 60).

**Conclusion:** Atypical TTP can presents without renal impairment. In these cases the measurement of ADAMTS-13 activity as a specific test as well as ruling out secondary TTP should be considered.

**Key word:** Renal dysfunction, thrombotic thrombocytopenic purpura, ADAMTS-13.

## Introduction

Thrombotic thrombocytopenic purpura (TTP) as a thrombotic microangiopathy (TMA) is the most malignant microangiopathy which is sometimes life threatening <sup>1</sup>. It is clinically characterized by five typical syndromes which consist of thrombocytopenia, hemolytic anemia (characterized by schistocytes), renal impairment, neurological abnormalities, and fever <sup>2</sup>. Microthrombosis without a deficiency in ADAMTS-13 activity can also be associated with other diseases such as hemolytic uremic syndrome (HUS), various autoimmune diseases, cytotoxic drug consumption, human immunodeficiency virus (HIV) infection, malignancies, disseminating intravascular coagulopathy (DIC), and pre-eclampsia <sup>3</sup>. Obvious renal involvement in TTP is lesser compared with HUS; but in 25% of cases there is progressive renal impairment <sup>4</sup>. The exact etiology of TTP is unknown. Most sporadic cases of TTP appear to be associated with severe deficiency of ADAMTS13 activity due to autoantibodies against this protease. Measuring ADAMTS13 activity level may aid in diagnosis. In fact pathophysiology of TTP due to severe deficiency of Von Willebrand factor cleaving protease, known as ADAMTS13, has improved diagnosis of TTP <sup>5</sup>.

Sometimes, diagnosis based on clinical findings by ruling out the similar clinical diagnosis may cause delay in the management of TTP.

## Report of the Case

A 12-year-old male was admitted to our hospital because of cytopenia and fever with initial diagnosis of aplastic anemia. He had mild purpura on his arms and legs during 2 weeks before the admission. In his physical examination, he had fever (38.2°C orally), but other vital signs were stable. Cardiopulmonary exams were normal and he did not have organomegaly. After sepsis work up, broad spectrum antibiotics were administered as initial therapy because severe bacterial infection was suspected in this condition. Microscopic hematuria, seizure and lethargy were developed in his hospital course. He was not alert. Bacterial cultures from his blood, urine, sputum, and throat swab revealed no signs of any bacterial infections, so bacterial infection was excluded. Also brain CT scan and MRI revealed no hemorrhage or mass lesion. Peripheral blood smear revealed low platelet count with increased schistocytes and fragmented red blood cells. Bone marrow study was

**Table 1:** Patient's paraclinical tests results.

Test	Value	Defenition
Hb	9	g/dl
WBC	13800	mm <sup>3</sup>
platelet	70000	mm <sup>3</sup>
Retic count		
D-Deimer	400	In Conventional Units: ≤ 250 ng/mL D-dimer units (DDU) In SI Units: ≤ 0.50 mcg/mL fibrinogen equivalent units (FEU)
PT	12	minutes
PTT	32	minutes
fibrinogen	300	mg/dl
LDH	3996	mg/dl
T.Bil	3.5	mg/dl
D.Bil	2.5	mg/dl
BUN	12	mg/dl
Creatinine	0.4	mg/dl
FDP(fibrin degradation product)	35	micrograms per milliliter (mcg/mL) Normal Values: The result is normally less than 10 mcg/mL
Direct Coombs	Negative	
Indirect Coombs	Negative	
ANA	Normal	
Anti-SSA	Normal	
Anti-RNP	Normal	
C3	0.4	The normal ranges of C3 and C4 do not alter with age. C3 0.65 - 1.65 g/L
C4	0.32	C4 0.16 – 0.60 g/L
CH50	350	CH50 Values % of Reference values Interpretation: * <100(0-50%) Absent or low * 100-300(51to150) Normal * >300 (>150%) High
Anti-DNA	Normal	
Haptoglobin	70	Normal Values: 27-139 mg/dL
Cold agglutinin	Negative	
p-ANCA	Normal	
c-ANCA	Normal	
ESR	65	mm/hr
G6PD	Normal	
HBSAg	Negative	
Anti-HCV Ab	Negative	
Anti-HIV Ab	Negative	
EBV-VCA-IgM	Negative	
CMV-IgM	Negative	
Blood culture	Negative	

**Table abreviation:**

Hb:hemoglobin, WBC: white blood cell, Plt: platlet, PT: prothrobin time, PTT: partial prothrombin time, LDH: lactate dehydrogenase, T.BIL: total bilirubin, D. BIL: direct bilirubin, BUN: blood urea nitrogen, ANA: antinuclear antibody, Anti-SSA: Anti-SSA autoantibodies (also called anti-Ro, or the combination anti-SSA/Ro or anti Ro/SSA autoantibodies), Anti-RNP: anti- Ribonucleoprotein, p-ANCA, c-ANCA, ESR: erythrocyte sedimentation rate, G6PD:glucose 6 phosphate dehydrogenase, CMV: cytomegalovirus.

normal with mild erythroid hyperplasia. More work up was performed to rule out immune disorders and malignancies. A summary of the results of laboratory tests on admission is presented in table 1.

ADAMTS-13 autoantibody was more than 60 (normal value<40) so thrombotic thrombocytopenic purpura (TTP) as a final diagnosis was confirmed. Treatment for patient was started and plasmapheresis

was performed for 3 days after trial of prednisone (1 mg/kg/day). The patient became conscious and in follow up after 3 months normal laboratory tests including ADAMTS-13 autoantibody, LDH and platelet count were observed.

## Discussion

Diagnosis of TTP is complex when the renal presentation is absent and needs a rapid specific and sensitive test such as ADAMTS13 activity as well as ruling out secondary TTP<sup>6</sup>.

Measurement of ADAMTS-13 activity is effective for obtaining a definite diagnosis especially in atypical cases. The classic disease is observed in as few as 40% of TTP patients, and the clinical period of the syndrome is usually fast, therefore, an accurate diagnosis and swift treatment including plasma exchange is necessary<sup>7</sup>.

Renal dysfunction including proteinuria and hematuria is common; however, acute renal failure and oliguria are less common. It is a part of the diagnostic criteria for TTP<sup>8</sup>.

Predisposing factors are cancer, pregnancy, bone marrow transplantation, cytotoxic medications, and HIV-1 infection.

The mechanism of secondary TTP is poorly understood, as ADAMTS-13 activity is generally not as

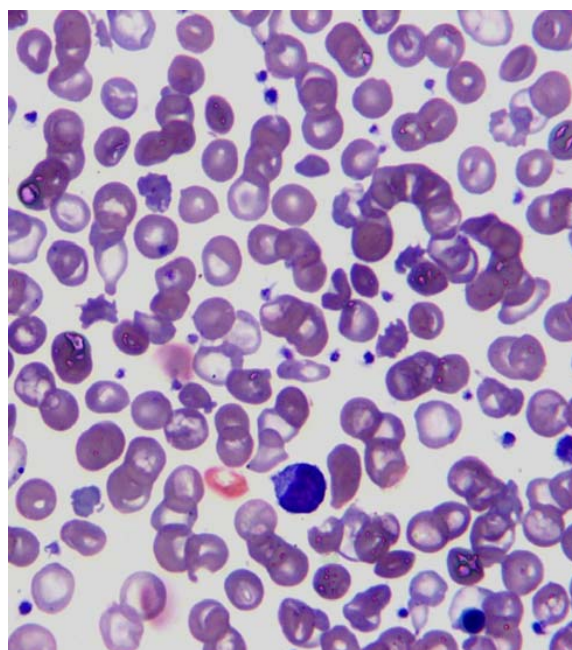
depressed as what is observed in idiopathic TTP, and inhibitors cannot be detected<sup>9</sup>.

Similar to our patient, Shortt et al. in 2013 reported a 53-year-old woman presented with fever, headache, focal neurologic signs, and microangiopathic hemolysis without renal dysfunction or diarrhea<sup>10</sup>. The ADAMTS-13 activity was undetectable, with a level of ADAMTS-13 autoantibodies of 3.2 Bethesda Units (BU). She was treated with plasmapheresis and prednisolone (1 mg/kg)<sup>10</sup> similar to our patient.

The mortality rate is approximately 95% for untreated patients, but the prognosis is reasonably favorable (80-90% survival) for patients with idiopathic TTP diagnosed and treated early with plasmapheresis<sup>11</sup>. Measurement of ADAMTS-13 activity was life saving both in our patient and in the patient reported by Shortt et al. Except this case we did not find any other similar case in medical search engines such as google scholar, pubmed and embase.

## Conclusion

The kidney is commonly affected in thrombotic thrombocytopenic purpura. Nevertheless, due to differences in its diagnostic criteria, the frequency and severity of renal dysfunction in TTP remains controversial. Among patients with acquired TTP



**Figure1:** Patient's peripheral blood smear: many Schistocytes, Wright-Giemsa stain, oil immersion.

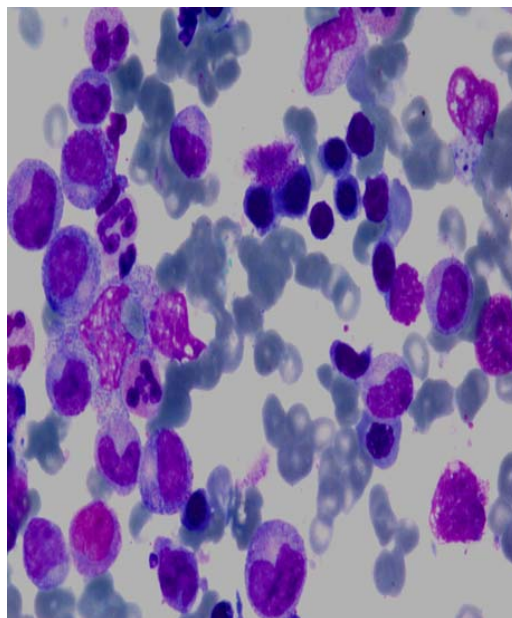
resulted from inhibitory antibodies of ADAMTS-13, renal dysfunction is usually mild; including oliguria, fluid overload, hypertension, and the need for dialysis support is infrequent. In the absence of these complications, the diagnosis of TTP is not at the top of the list of differential diagnosis; therefore checking the ADAMTS-13 can be helpful.

## Acknowledgments

This study was supported by Shiraz University of Medical Sciences. We thank Shirin Parand at the Hematology Research Center for helping with manuscript preparation.

## References

1. Moake J. Thrombotic thrombocytopenia purpura (TTP) and other thrombotic microangiopathies. *Best Pract Res Clin Haematol.* 2009;22(4):567-76.
2. Ohashi N, Yonemura K, Sugiura T, Isozaki T, Togawa A, Fujigaki Y, et al. Withdrawal of interferon-alpha results in prompt resolution of thrombocytopenia and hemolysis but not renal failure in hemolytic uremic syndrome caused by interferon-alpha. *Am J Kidney Dis.* 2003;41(3):E10.
3. Gomes AM, Ventura A, Almeida C, Correia M, Tavares V, Mota M, et al. Hemolytic uremic syndrome as a primary manifestation of acute human immunodeficiency virus infection. *Clin Nephrol.* 2009;71(5):563-6.
4. Miller DP, Kaye JA, Shea K, Ziyadeh N, Cali C, Black C, et al. Incidence of thrombotic thrombocytopenic purpura/hemolytic uremic syndrome. *Epidemiology.* 2004;15(2):208-15.
5. Ono T, Mimuro J, Madoiwa S, Soejima K, Kashiwakura Y, Ishiwata A, et al. Severe secondary deficiency of von Willebrand factor-cleaving protease (ADAMTS13) in patients with sepsis-induced disseminated intravascular coagulation: its correlation with development of renal failure. *Blood.* 2006;107(2):528-34.
6. Rieger M, Ferrari S, Kremer Hovinga JA, Konetschny C, Herzog A, Koller L, et al. Relation between ADAMTS13 activity and ADAMTS13 antigen levels in healthy donors and patients with thrombotic microangiopathies (TMA). *Thromb Haemost.* 2006;95(2):212-20.
7. Hulstein JJ, Rison CN, Kappers-Klunne MC, Hene RJ, Franx A, de Groot PG, et al. Activity loss of Von Willebrand factor cleaving protein (ADAMTS-13) is diagnostic for primary and pregnancy-related thrombotic thrombocytopenic purpura. *Ned Tijdschr Geneesk.* 2004;148(40):1972-6. Article in Dutch.
8. Haycock GB. Management of acute and chronic



**Figure2:** Patient's bone marrow aspiration: mild erythroid hyperplasia, Wright-Giemsa, oil immersion.

- renal failure in the newborn. *Semin Neonatol.* 2003;8(4):325-34.
9. Zheng XL, Kaufman RM, Goodnough LT, Sadler JE. Effect of plasma exchange on plasma ADAMTS13 metalloprotease activity, inhibitor level, and clinical outcome in patients with idiopathic and nonidiopathic thrombotic thrombocytopenic purpura. *Blood.* 2004;103(11):4043-9.
  10. Shortt J, Oh DH, Opat SS. ADAMTS13 antibody depletion by bortezomib in thrombotic thrombocytopenic purpura. *N Engl J Med.* 2013;368(1):90-2.
  11. Mori Y, Wada H, Tamaki S, Minami N, Shiku H, Ihara T, et al. Outcome of thrombotic thrombocytopenic purpura and hemolytic uremic syndrome in Japan. *Clin Appl Thromb Hemost.* 1999;5(2):110-2.