

# Rosai-Dorfman Disease: A Case Report and Literature Review

Shamsian BS<sup>1\*</sup>, Arabi N<sup>1</sup>, Kazemi Aghdam<sup>2</sup>, Rouzrokh M<sup>3</sup>, Ghojehvand N<sup>4</sup>, Azma R<sup>4</sup>, Kaji Yazdi M<sup>1</sup>, Alavi S<sup>1</sup>, Arzanian MT<sup>1</sup>

1. Pediatric Congenital Hematological Disorders Research Center. Mofid children's hospital, Shahid Beheshti University of Medical Sciences, Tehran, Iran.

2. Department of pediatric pathology, Mofid children's hospital. Shahid Beheshti University of Medical Sciences, Tehran, Iran.

3. Department of pediatric surgery, Mofid children's hospital. Shahid Beheshti University of Medical Sciences, Tehran, Iran.

4. Department of pediatric radiology. Mofid children's hospital. Shahid Beheshti University of Medical Sciences, Tehran, Iran.

\*Corresponding Author: Shamsian BS, Email: shahinshamsian@gmail.com

Submitted: 07-10-2013, Accepted: 29-04-2014

## Abstract

Rosai-Dorfman disease or sinus histiocytosis with massive lymphadenopathy is a rare disorder that typically manifests as lymphadenopathy and systemic symptoms whose etiology remains poorly elucidated. The diagnosis is based on immunohistochemistry. Its treatment is poorly defined but the prognosis is usually favorable.

Here we report a 14 year old boy who presented with massive bilateral cervical lymphadenopathy. Histopathological examination demonstrated lymphophagocytosis (emperipolesis) consistent with a diagnosis of Rosai-Dorfman disease. The clinical and histological aspects of the disease are discussed as a rare cause of lymphadenopathy.

**Key Words:** Rosai-Dorfman disease, emperipolesis, case, Iran.

## Introduction

Rosai-Dorfman disease, also referred to as sinus histiocytosis with massive lymphadenopathy, is a rare non neoplastic proliferative disorder of the cells of macrophage-histiocyte family which was first described by Destombes in 1965<sup>1,2</sup>. It was recognized as a distinct clinicopathologic entity by Rosai and Dorfman in 1969<sup>1-4</sup> and in 1990 they published the largest series of 423 patients<sup>5</sup>. The registry now contains 600 cases<sup>5</sup>.

This disease can occur at all ages, but mostly happens during the first decade of life with a male predominance<sup>1-4</sup>. Here we report a 14 year old boy who presented with massive bilateral cervical lymphadenopathy.

## Report of the Case

A 14 year old boy presented in our hospital hematology clinic with bilateral multiple cervical lymphadenopathy since 1 months ago. There was a history of low grade fever, but

no sweating, weight loss, pain and respiratory tract infections were reported. There was no family history of tuberculosis. Clinical examination showed multiple, enlarged, bilateral, cervical lymph nodes ranging in size from 3X4 cm on the left side to 4X5cm on the right side (Figure 1). They were non-tender, firm and mobile. Laboratory evaluations showed WBC: 14800/mm<sup>3</sup>, Hb: 13gr/dl, MCV: 86 Fl, Platelet: 301000/mm<sup>3</sup>, PMN:86%, L: %7, Mono: % 5,

E: 2%, ESR: 45mm/h; Biochemistry: normal, Uric acid: 4.2mg/dl, LDH: 283 lu/ml, Ferritin: 80 ng/ml, Liver function tests: normal. The results of Serologic tests were as follow Hbs Ag: negative, HbsAb: 15( >10 positive), Anti HCV: negative, Anti HIV: negative, titer of EBV IgG: 59 (normal: Up to 20), EBV IgM:0.2 (<0.9: Negative), titer of Toxoplasmosis IgG: 0.5 and IgM: 0.3 (both in normal range). Immunoglobulins level: IgG: 1318 mg/dl (normal range: 700-1400), IgM: 83 mg/dl

(normal range 40-150), IgA: 193 mg/dl (normal range: 44-395). CXR: normal, abdominal sonography: normal, including liver size; 105mm and spleen size 84mm. Bone marrow aspiration and biopsy: normal. Flow cytometry: normal. Bone survey: normal, cervical CT scan revealed bilateral enlargement of lymph nodes in all neck chains (sub mandibular, supraclavicular, posterior triangle), but chest and abdominal CT scans were normal. Cardiac echocardiography was normal with ejection fraction of 60%. After evaluation, left cervical lymph nodes' biopsy was performed. Histopathology report was Rosai-Dorfman disease with specific finding of emperipolesis (Figure 2). Immunohistochemistry results were positive for S-100 Pr as well as CD68 and negative for CD1a. We started the treatment with prednisone 2 mg/kg/ day. His response to treatment was excellent. Now he is on follow up.

## Discussion

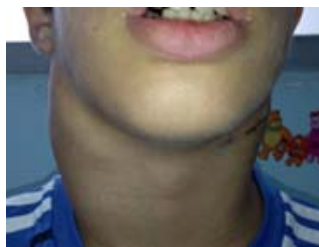Lymph nodes are the organs most frequently involved in Rosai-Dorfman disease. More than 90% of patients with Rosai-Dorfman disease present with massive bilateral mobile and non tender cervical lymphadenopathy<sup>1-6</sup>. Axillary, inguinal or mediastinal lymph nodes can be involved in 30 to 40% of cases<sup>1-4</sup>. Extranodal involvement is observed in only 43% of cases with a predilection for the ear, nose and throat especially the upper aerodigestive tract, salivary glands, orbit, skin and nasal and paranasal sinus mucosa<sup>7,8</sup>.

Kharrat et al. reported a case of multifocal Rosai-Dorfman disease<sup>7</sup>. Sodhi et al. reported a case of Rosai-Dorfman disease with unusual presentation of diffuse and massive retroperitoneal

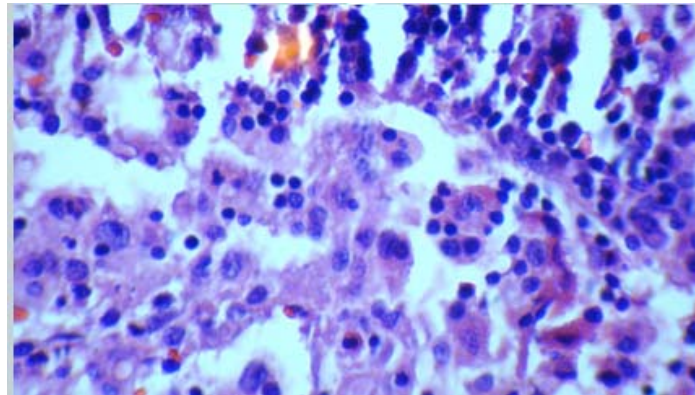
lymphadenopathy<sup>8</sup>. Renal involvement is rarely described and is generally asymptomatic or may present with fever or renal failure<sup>7</sup>. Bone lesions may be observed in 8% of cases with lytic lesions affecting the marrow of long bones, skull, vertebrae, ribs, patella and facial bones<sup>7</sup>. Ophthalmic manifestations are rare and seen in 9% to 11% of cases<sup>1,4</sup>. The most frequent ophthalmic manifestation is an orbital soft-tissue mass with proptosis<sup>5</sup>. The laboratory work-up sometimes reveals a raised erythrocyte sedimentation rate, auto-immune hemolytic anemia, hypergammaglobulinaemia and leukocytosis. Our patient had normal immunoglobulins level<sup>1,7,8</sup>. Azoulay et al. in 2004 reported that almost 13% of patients have an associated immune disorder, such as autoantibodies against red blood cells and joint diseases<sup>5</sup>. Imaging only allows a precise assessment of the lesions without suggesting the diagnosis due to the nonspecific radiological appearance<sup>7</sup>. Our patient presented with just cervical lymph adenopathy and occasional low grade fever.

Several theories have been proposed as the cause of the disease, including viral, essentially involving the Epstein Barr virus and Human Herpesvirus 6 (HHV-6), and immunological disorders due to the presence of disorders of humoral immunity and decreased cell mediated immunity. Mehraein et al.<sup>9</sup> have recently published 4 cases of Rosai-Dorfman disease in which a parvovirus B19 was isolated from cervical lymph nodes, supporting the hypothesis of a viral etiology. In contrast, a genetic etiology was proposed by Sertac and Rossbach due to the existence of familial cases of Rosai-Dorfman disease<sup>7</sup>.

The characteristic cytomorphology of this entity is the presence of large histiocytes with abundant



**Figure 1:** Massive bilateral cervical lymphadenopathy in patient.



**Figure 2:** Smear showing histiocytes with engulfed intact lymphocytes.

cytoplasm having variable number of intact lymphocytes within it; a phenomenon referred to as lymphophagocytosis or emperipolesis. The background typically shows lymphocytes, plasma cells and occasional neutrophils<sup>1</sup>. Besides cytomorphology, the histiocytes on immunostaining show positivity for S100 protein, CD14, CD33 and CD68 in cytological smears<sup>1</sup>. Extranodal involvement is seen in up to 40% of cases which show similar morphological features to their nodal counterparts although fewer histiocytes with emperipolesis are encountered<sup>1</sup>. Our patient had histopathology and immunohistochemistry reports compatible with these findings.

Rosai-Dorfman disease raises a problem of differential diagnosis with Hodgkin's and non-Hodgkin's malignant lymphoma, leukemia, metastases and Wegener's granulomatosis as well as sarcoidosis<sup>7</sup>. Pathological differential diagnosis of Rosai-Dorfman disease include reactive sinus hyperplasia (in which cells lack emperipolesis and are S100 negative), Langerhans cell histiocytosis (positive for both S100 and CD1a), Hodgkin's disease, metastatic carcinoma, malignant melanoma and lymphoma<sup>6</sup>. It is important to note, however, that the occurrence of emperipolesis per se should not be considered diagnostic for Rosai-Dorfman disease; instead, diagnosis requires correlation of the appropriate clinical presentations with an adequately preserved and properly prepared FNA sample of consistent cytomorphologic features. In addition, numerous other diseases either demonstrate emperipolesis or represent cytomorphologic mimics, including lymphoma,

malignancy, hemophagocytic syndrome, infection, Langerhans cell histiocytosis and various other reactive processes<sup>10-12</sup>.

Treatment has not yet been clearly defined<sup>7</sup>. Complete remission frequently occurs over several months or years, either spontaneously or with the administration of steroid treatment, as in our case. However, systemic involvement rarely has a fatal outcome<sup>5</sup>. Corticosteroid therapy allows for transient improvement of the disease<sup>6</sup>. Radiotherapy is reserved for active, life-threatening forms of the disease refractory to corticosteroids and surgery and can be proposed for compressive and extensive lesions. Sodhi et al.<sup>8</sup> have reported that the disease typically pursues an indolent clinical course. In approximately 50% of patients, the disease resolves without appreciable sequela, one third have residual asymptomatic adenopathy and 17% have persistent symptomatology after 5 to 10 years<sup>8</sup>.

## Conclusion

Massive cervical lymphadenopathy is the hallmark of Rosai-Dorfman disease. Head and neck region is the preferred site for the extranodal form of the disease. The diagnosis of Rosai-Dorfman disease is made on the basis of clinical suspicion, confirmed by cytology and supported by histopathology. Clinicians and pathologists should always consider Rosai-Dorfman disease when making a differential diagnosis for cervical lymphadenopathy.

## References

1. Kushwaha R, Ahluwalia C, Sipayya V. Diagnosis of sinus histiocytosis with massive lymphadenopathy (Rosai-Dorfman Disease) by fine needle aspiration cytology. *J Cytol.* 2009;26(2):83-5.
2. Destombes P. Adenitis with lipid excess, in children or young adults, seen in the Antilles and in Mali. (4 cases). *Bull Soc Pathol Exot Filiales.* 1965;58(6):1169-75. [Article in French]
3. Rosai J, Dorfman RF. Sinus histiocytosis with massive lymphadenopathy. A newly recognized benign clinicopathological entity. *Arch Pathol.* 1969;87(1):63-70.
4. Ju J, Kwon YS, Jo KJ, Chae DR, Lim JH, Ban HJ, et al. Sinus histiocytosis with massive lymphadenopathy: a case report with pleural effusion and cervical lymphadenopathy. *J Korean Med Sci.* 2009;24(4):760-2.
5. Azoulay R, Brisse H, Fréneaux P, Ferey S, Kalifa G, Adamsbaum C. Lacrimal location of sinus histiocytosis (Rosai-Dorfman-Destombes disease). *AJNR Am J Neuroradiol.* 2004;25(3):498-500.
6. Sharma S, Bhardwaj S, Hans D. Rosai-Dorfman Disease. *JK Science.* 2010;12(4):194-6.
7. Kharrat S, Sahtout S, Oukhai M, Mekni E, Trabelsi E, Haouet S, et al. Multifocal Rosai-Dorfman disease: a case report. *Fr ORL.* 2008;94:395-8.
8. Sodhi KS, Suri S, Nijhawan R, Kang M, Gautam V. Rosai-Dorfman disease: unusual cause of diffuse and massive retroperitoneal lymphadenopathy. *Br J Radiol.* 2005;78(933):845-7.
9. Mehraein Y, Wagner M, Remberger K, Füzesi L, Middel P, Kaptur S, et al. Parvovirus B19 detected in Rosai-Dorfman disease in nodal and extranodal manifestations. *J Clin Pathol.* 2006;59(12):1320-6.
10. Shi Y, Griffin AC, Zhang PJ, Palmer JN, Gupta P. Sinus histiocytosis with massive lymphadenopathy (Rosai-Dorfman Disease): A case report and review of 49 cases with fine needle aspiration cytology. *Cytojournal.* 2011;8:3. doi: 10.4103/1742-6413.76731.
11. Mehrotra S, Ather S, Gupta P, Mehrotra B. Rosai Dorfman disease: a clinico-pathological presentation. *J Assoc Physicians India.* 2007;55:587-9.
12. Ju J, Kwon YS, Jo KJ, Chae DR, Lim JH, Ban HJ, et al. Sinus histiocytosis with massive lymphadenopathy: a case report with pleural effusion and cervical lymphadenopathy. *J Korean Med Sci.* 2009;24(4):760-2.