

Askin Tumor Presenting as Superior Vena Cava Syndrome

Nazari S¹, Malek F^{1*}, Madani F¹, Hamoud M¹

1. Pediatric Congenital Hematologic Disorders Research Center, Mofid Children's Hospital, Shahid Beheshti University of Medical Sciences, Tehran, Iran

***Corresponding Author:** Malek F, **Email:** fmalek7721@gmail.com

Submitted: 10-03-2014, Accepted: 19-06-2015

Keywords: Askin tumor, primitive neuroectoderma tumor, superior vena cava syndrome, children

Introduction

primitive neuroectodermal tumor (PNET) of the chest wall (also known as Askin tumor) is a malignant tumor arising from the migrating cells of the neural crest which belongs to Ewing sarcoma family tumors (ESFT)¹⁻³. Askin tumor with a high incidence of local recurrence and distant

metastasis generally presents with symptoms of respiratory distress and painful mass in the chest wall²⁻⁴.

Presentation of Askin tumor with superior vena cava (SVC) syndrome should be considered as an extremely rare manifestation and oncologic

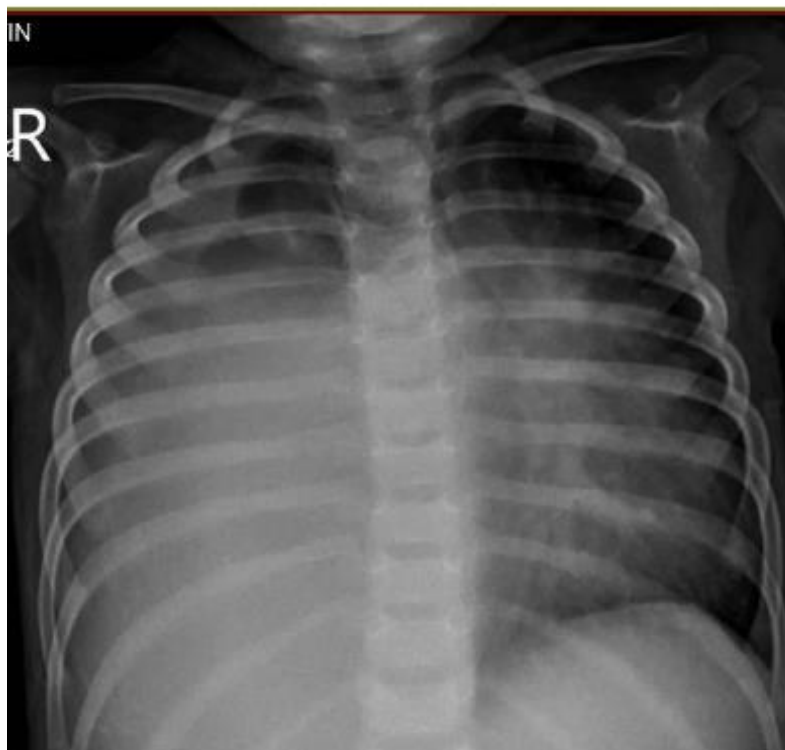


Figure 1: Chest radiography showing a homogeneous opacity in the right hemithorax

emergency which could have a fatal outcome with complete blockage. To the best of our knowledge, this is the first case of Askin tumor in chest wall presenting with SVC syndrome in children.

A 2-year-old girl was admitted in our ward

Histologically, PNETs are characterized by a sheet of small round blue cells that react positively to glycoprotein CD99. Homer–Wright pseudorosettes are a characteristic histological finding in PNET³⁻⁶.

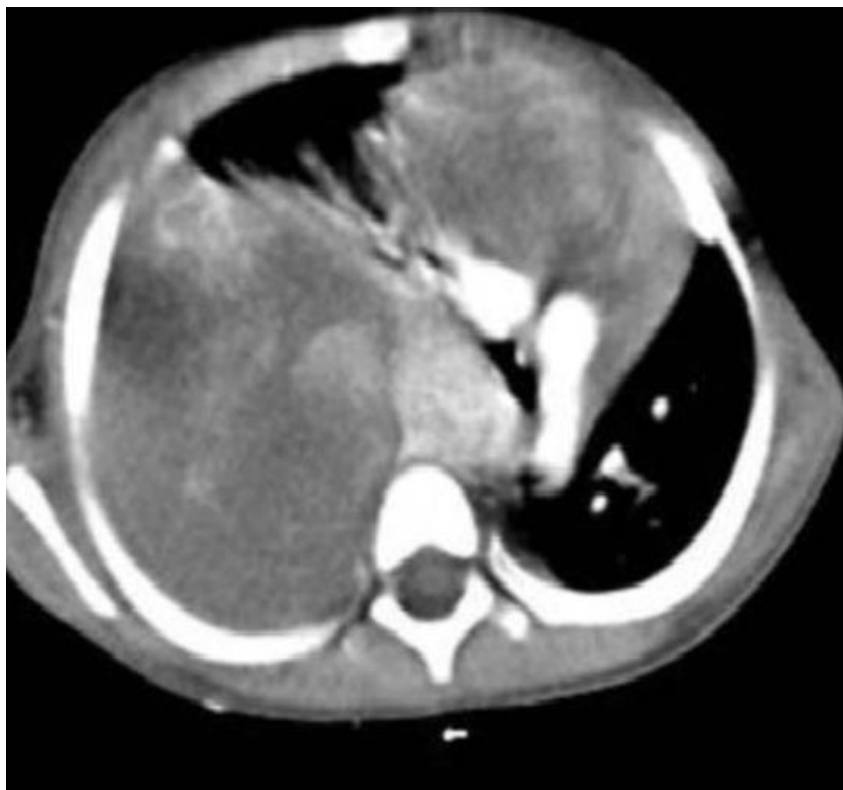

Figure 2: Contrast-enhanced computed tomography of the chest showing right upper mediastinal mass which was compressing the SVC and collateral vessels

due to progressive respiratory distress and marked facial edema. Chest radiography showed a homogeneous opacity in the right hemithorax (figure 1).

Contrast-enhanced computed tomography of the chest revealed right upper mediastinal mass which was compressing the SVC and collateral vessels (figure 2). Thorough radiologic evaluation detected no metastasis. Mediastinal biopsy on the basis of morphologic characteristics and immunohistochemistry was compatible with the diagnosis of PNET. Therefore, the patient was scheduled to receive combination chemotherapy followed by surgical resection.

Review of literature shows only one case of pulmonary Ewing's sarcoma described in a child less than ten years of age who presented with SVC syndrome caused by the intrathoracic mass compressing the SVC³.

Gupta and colleagues have reported lymphoma as the most common cause of SVC syndrome⁶. Another study demonstrated all the cases of SVC syndrome had a malignant etiology, the most common of which was T-cell acute lymphoblastic leukemia followed by lymphoma⁷.

Our patient presented with SVC syndrome showing typical histological and immunohistochemistry features of Askin tumor.

Despite its rare incidence, SVC syndrome due to Askin tumor should be kept in mind as a differential diagnosis of SVC syndrome in which early detection and prompt treatment can be lifesaving.

References

1. Nag VK, Nandan D, Chatterjee A, Bhardwaj M. Primitive neuroectodermal tumor presenting with superior vena cava syndrome. *J Assoc Chest Physicians*. 2014;2:81-3. DOI:10.4103/2320-8775.135119.
2. Xue Dou, Hongjiang Yan, Renben Wang. Treatment of an Askin tumor: A case report and review of the literature. *Oncol Lett*. 2013;6(4): 985–989. DOI:10.3892/ol.2013.1488.
3. Shibani M, Swapndeeep Singh A, Umesh CG. Primary Pulmonary Ewing's Sarcoma in Children. *J Clin Diagn Res*. 2014; 8(8):5-6. DOI:10.7860/JCDR/2014/8681.4713.
4. Younus R, Khan A, Syed S. Giant Askin Tumor a diagnosis and therapeutic Challenge. *J Pak Med Assoc*. 2002;52(2):82-5.
5. Kara Gedik G, Sari O, Altinok T, Tavli L, Kaya B and Ozcan Kara P. Askin's tumor in an adult case report and findings on 18F-FDG PET/CT. *Case Rep Med*. 2009;517329. DOI:10.1155/2009/517329.
6. Benbrahim Z, Arifi S, Daoudi K, Serraj M, Amara B, Benjelloun MC, Mellas N. Askin's tumor: a case report and literature review. *World J Surg Oncol*. 2013;11:10. DOI:10.1186/1477-7819-11-10.
7. Aggarwal M, Lakhhar B, Aggarwal BK, Anugu R. Askin tumor: A malignant small cell tumor. *Indian J Pediatr*. 2000;67(11):853-855.