IJBC 2016; 8(4): 125-126

Iranian Journal of Blood & Cancer

Journal Home Page: www.ijbc.ir

PHOTO CLINIC

Kaposiform Hemangioendothelioma in a Newborn with Kasabach-Merritt Syndrome

Shahnaz Armin[1]*, Roxana Azma[2], Maryam Kazemi Aghdam[3]

[1]Pediatric Infections Research Center, Shahid Beheshti University of Medical Sciences, Tehran, Iran
[2]Pediatric Radiology Department, Shahid Beheshti University of Medical Sciences, Tehran, Iran
[3]Pediatric Pathology Research Center, Shahid Beheshti University of Medical Sciences, Tehran, Iran

ARTICLE INFO

Article History:
Received: 28.08.2016
Accepted: 15.10.2016

**Corresponding author:*
Shahnaz Armin, MD
Address: Mofid Children's Hospital, Dr Shariati Ave, Opposite Hosseinieh Ershad, Tehran, Iran
Email: armin_sh2000@yahoo.com

Please cite this article as: Armin S, Azma R, Kazemi Aghdam M. Kaposiform Hemangioendothelioma in a Newborn with Kasabach-Merritt Syndrome. IJBC 2016; 8(4): 125-126.

A 1-month-old infant was admitted to the infectious department due to a firm mass on his right thigh with a probable diagnosis of abscess. The parents claimed that it had appeared one week following injection of hepatitis vaccine at birth. physical examination was unremarkable but a tumoral mass with blue discoloration and mild erythema which was palpated almost on whole thigh of the infant. He was afebrile. Laboratory tests showed a moderate thrombocytopenia (ranging from 40,000-80,000/mm^3). Sepsis work-up study was negative and coagulation profile was within normal range. Considering the most common causes of neonatal thrombocytopenia, "neonatal alloimmune thrombocytopenia" and "idiopathic thrombocytopenic purpura" (ITP) were ruled out. Maternal platelets were normal and history of ITP was negative. Imaging studies were suggested for the infant to rule out the possibility of hemangioma, as a probable cause of thrombocytopenia, causing "kasabach-merritt" syndrome.

Thigh-x-ray showed soft tissue edema without evidence of any abnormal collection. Ultrasound study showed a heterogeneous tumor with increased echogenicity of subcutaneous tissues along with swelling in quadriceps muscles of right thigh. Spectral arterial Doppler was biphasic on right lower extremity which could be due to an inflammatory process in quadriceps muscles. CT-angiography showed a hypervascular lesion measuring 37×22×81 mm in anterolateral muscular compartment of right thigh with multiple tortous arteries and popliteal feeders from superficial and deep femoral arteries (Figure 1A, B). Hypervascular lesions such as hemangioma and soft tissue "aneurysmal bone cyst" was suggested. A biopsy from the lesion was performed which pathology was compatible with "kaposiform hemangioendothelioma" (KHE).

KHE is a rare tumor of infancy and childhood. It often presents as an ill-defined, red to purple, indurated plaque and is often complicated by the Kasabach-Merritt phenomenon (KMP), a condition of severe thrombocytopenia and consumptive coagulopathy.[1] The management of these vascular tumors is very difficult and several multimodality and chemotherapeutic regimens have been described but with variable success and many side effects. There are multiple treatments suggested including corticosteroids, propranolol and vincristine[2] to more complicated chemotherapeutic agents such as multiple courses of vincristine, cyclophosphamide, and actinomycin D (VAC).[3]

Our patient received oral prednisone and propranolol which after two weeks platelets returned to normal levels. However, despite decreasing in size of the tumor, the treatment is ongoing and we are planning to repeat the CT-Angiography after 3 months.

Conflict of Interest: None declared.

[Downloaded from ijbc.ir on 2026-11-29]

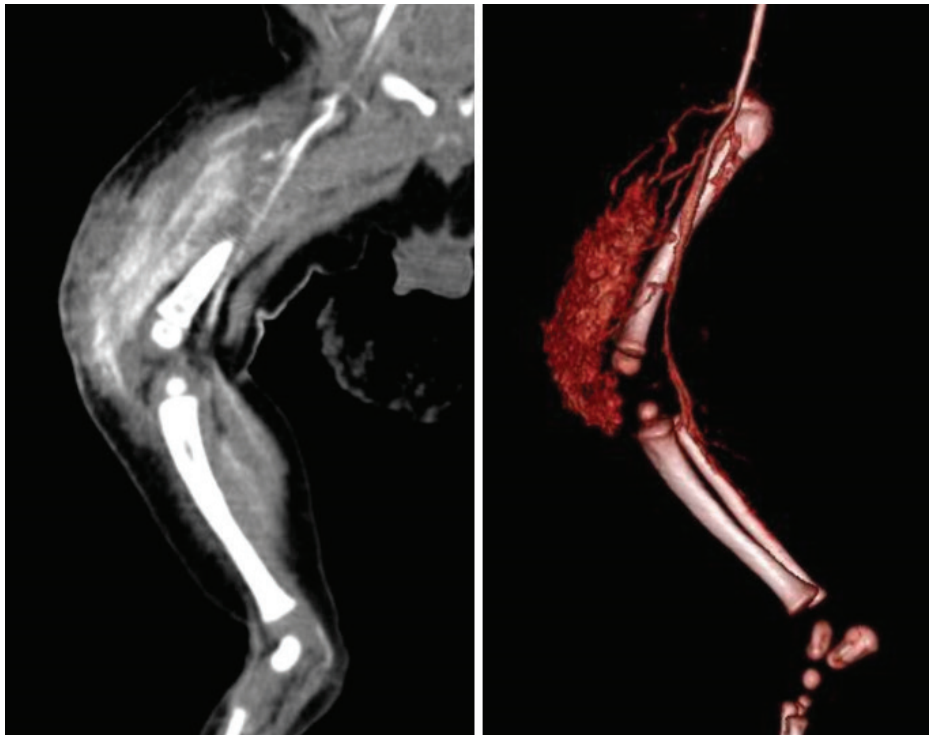

Figure 1: A) (MPR coronal plane CT angiography with hip in abduction position) and B) (3D Volume rendered CT Angiography) show a hypervascular mass lesion in anterior and lateral muscular compartment of middle and inferior part of thigh and knee joint. Multiple tortuous arterial feeders from superficial and deep femoral, as well as popliteal arteries feed the lesion

References

1. Tamai N, Hashii Y, Osuga K, Chihara T, Morii E, Aozasa K, et al. Kaposiform hemangioendothelioma arising in the deltoid muscle without the Kasabach–Merritt phenomenon. Skeletal Radiol. 2010; 39(10):1043-6. doi: 10.1007/s00256-010-0917-1. PubMed PMID: 20309545.
2. Hermans DJJ, van Beynum IM, van der Vijver RJ, Kool LJS, de Blaauw I, van der Vleuten CJM. Kaposiform hemangioendothelioma with Kasabach-Merritt syndrome: a new indication for propranolol treatment. J Pediatr Hematol Oncol. 2011; 33(4):e171-3. doi: 10.1097/MPH.0b013e3182152e4e. PubMed PMID: 21516018.
3. Hu B, Lachman R, Phillips J, Peng S-K, Sieger L. Kasabach-Merritt syndrome-associated kaposiform hemangioendothelioma successfully treated with cyclophosphamide, vincristine, and actinomycin D. J Pediatr Hematol Oncol. 1998; 20(6):567-9. PubMed PMID: 9856681.

[Downloaded from ijbc.ir on 2026-11-29]