



CASE REPORT

Hodgkin's Lymphoma Occurring Secondary to Autologous Stem Cell Transplantation in Plasma Cell Leukemia; A Case Report

Geetha Narayanan, T Manohar Anoop, Lakshmi Haridas, Lali V Soman

Department of Medical Oncology, Regional Cancer Centre, Trivandrum 695011, Kerala, India

ARTICLE INFO

Article History:

Received: 01.12.2016

Accepted: 29.01.2017

Keywords:

Hodgkin's lymphoma
Plasma cell leukemia
Second malignancy
Stem cell transplantation

*Corresponding author:

Geetha Narayanan, MD, DM,
Address: Department of Medical
Oncology, Regional Cancer Centre
Trivandrum 695011, India
Tel: +91 944 7500920
Email: geenarayanan@yahoo.com

ABSTRACT

Survival of patients with multiple myeloma has improved substantially because of availability of new therapies including autotransplants, immunomodulating drugs and proteasome-inhibitors. Second primary cancers have emerged as an important determinant of morbidity and mortality among cancer survivors. Even though there is an increased risk of new cancers of the lymphoreticular and haematopoietic system, it is very rare for Hodgkin's lymphoma to occur as a second malignancy following autologous peripheral blood stem cell transplantation (APBSCT) for myeloma. We report a case of a female with plasma cell leukemia treated with autologous peripheral blood stem cell transplantation and lenalidamide maintenance. She developed cervical lymphadenopathy 4.5 years after the APBSCT, biopsy confirmed the diagnosis of classical Hodgkin's lymphoma, nodular sclerosis type. Since she developed allergic reaction to ABVD, she was given 6 cycles of COPP chemotherapy and is in complete remission now.

Please cite this article as: Narayanan G, Anoop TM, Haridas L, Soman LV. Hodgkin's Lymphoma Occurring Secondary to Autologous Stem Cell Transplantation in Plasma Cell Leukemia; A Case Report. IJBC 2017; 9(1): 24-26.

Introduction

Secondary cancers have emerged as an important determinant of morbidity and mortality among cancer survivors recently. Survival of patients with multiple myeloma (MM) has improved substantially due to access of new therapies including stem cell transplantation, immunomodulating drugs and proteasome inhibitors. Several studies report an increased risk of new cancers especially of the lymphoreticular and haematopoietic system.¹⁻⁴ Most of these are acute myeloid leukemia, myelodysplastic syndrome and non hodgkin's lymphoma. It is very rare for Hodgkin's lymphoma to occur as a secondary malignancy following APBSCT for myeloma. We report a case of a female with plasma cell leukemia treated with APBSCT, developing classical Hodgkin's lymphoma 4.5 years later.

Case Report

A 39-year-old woman presented with history of fatigue

and recurrent fever. Physical examination was remarkable for pallor, cervical and axillary lymphadenopathy. A peripheral blood smear showed 63% atypical plasma cells, serum protein was 12 g/dL, with s.globulin of 8.8 g/dl. A bone marrow examination showed 70% plasmacytoid cells which on flowcytometry demonstrated positivity for CD19, CD20, CD23 and CD138. A diagnosis of plasma cell leukemia was made. Her serum immunoglobulin G was 8085 mg/dl and β_2 microglobulin was 6.15 mg/L. She did not have any evidence of bone involvement. She was staged according to "International staging system" (ISS) to stage 3 and was started on bortezomib and dexamethasone. However, bortezomib was stopped after 2 cycles due to severe peripheral neuropathy and changed to VAD chemotherapy for 6 cycles. She achieved complete remission and was assigned to go through ASCT with high dose melphalan as the conditioning regimen. This was followed by maintenance lenalidamide for one year after which she was on regular follow up.

She presented 4.5 years after the transplant with fever and left cervical lymphadenopathy. Excisional lymph node biopsy showed a pleomorphic infiltrate of large mononuclear, binucleated or occasional multinucleated cells replacing the parenchyma, suggestive of Hodgkin's cells; Reed-Sternberg and lacunar cells (figure 1). On immunohistochemistry, these cells were CD20+(downregulated), CD30+, PAX5+, and occasional cells were CD15+. A diagnosis of classical Hodgkin's lymphoma, nodular sclerosis subtype was made. Computed tomogram showed bilateral cervical, pretracheal, paraaortic and celiac lymph nodes. She was staged as stage III B HL. A thorough assessment for multiple myeloma was negative in the patient. The EBV-DNA (PCR) was negative. She was started on ABVD (adriamycin, bleomycin, vinblastin, dacarbazine) protocol; however, due to severe allergic reaction the protocol was changed to COPP (cyclophosphamide, vincristine, procarbazine and prednisolone). She has completed 6 cycles of chemotherapy and currently is in complete remission. Patient has given consent to publish her case.

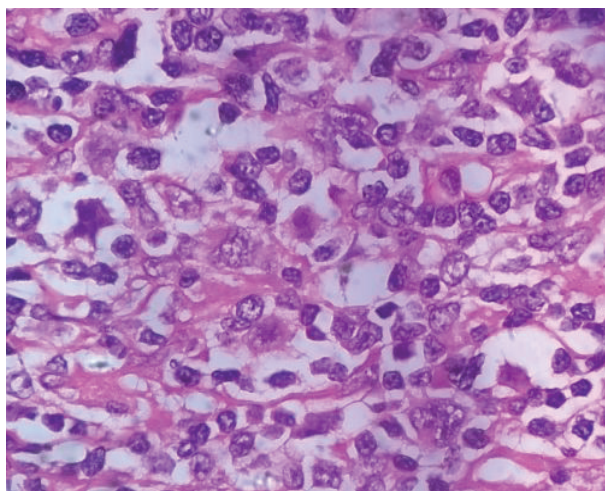


Figure 1: Section from lymph node showing Hodgkin's and Reed-Sternberg cells. (haematoxylin and eosin, magnification 100×)

Discussion

The issue of developing second malignancies has emerged as a clinical challenge among cancer survivors following successful chemotherapy for malignant disorders. According to the NCI SEER database, cancer survivors have a 14% increased risk of developing a second malignancy when compared to the general population.⁵ High dose chemotherapy followed by APBSCT is considered the standard of care for patients with MM since the Intergroupe Francophone du Myeloma trial demonstrated improved survival for such treated patients compared to conventional treatment. This in conjunction with induction and maintenance therapy with newer agents such as lenalidamide and bortezomib has further improved the survival in MM, to the extent that the 10-year survival in young patients with myeloma has reached to 50%.⁶

A recent meta-analysis reported a high risk for new

hematological malignancies in patients who have received lenalidamide and melphalan.¹ In a SEER based study, the authors reported an age adjusted incidence of MM with second primary cancers to be 2.2 per 1 million. There was an increased incidence of lymphatic and hematologic malignancies and a lower risk of solid organ cancer.³ The standard incidence ratio of Hodgkin's lymphoma developing in patients with multiple myeloma was 1.17.⁴

In another study on second malignancies following APBSCT in MM, the overall cumulative incidence was 5.3% at 5 years and 11.2 % at 10 years, there was one case of non Hodgkin's lymphoma and no Hodgkin's lymphoma.⁷ In another study on new cancers following autologous transplants in MM, there were 2 cases of Hodgkin's lymphoma occurring at 3-5 years post transplant.² In this study increasing age, male gender and obesity were associated with an increased risk of new cancers. Our patient was also treated with APBSCT with melphalan and maintenance lenalidamide which might have contributed to the development of second primary Hodgkin's lymphoma.

The factors that are attributed to development of second primary malignancies include: the primary site, histology, age at diagnosis and kind of chemotherapeutic agents given for the primary malignancy, as well as environmental and genetic factors. Similarly, in MM, the development of second malignancy may be treatment-related, myeloma-related, or due to environmental and host-related factors.

The outcome following the treatment of second malignancies in MM tend to be poor. MM patients with second cancer has 2.3-fold higher risk of death compared to MM patients without a second cancer, with a median survival of 1.1 years after diagnosis of second cancer.⁸

Conflict of Interest: None declared.

References

1. Palumbo A, Bringhen S, Kumar SK, Lupporelli G, Usmani S, Waage A, et al. Second primary malignancies with lenalidomide therapy for newly diagnosed myeloma: a meta-analysis of individual patient data. *Lancet Oncol.* 2014;15(3):333–42. doi: 10.1016/S1470-2045(13)70609-0. PubMed PMID: 24525202.
2. Mahindra A, Raval G, Mehta P, Brazauskas R, Zhang M, Zhong X, et al. New cancers after autotransplants for multiple myeloma. *Biol Blood Marrow Transplant.* 2015; 21(4):738-45. doi: 10.1016/j.bbmt.2014.12.028. PubMed PMID: 25555448.
3. Chakraborty S, Hauke RJ, Bonthu N, Tarantolo SR. Increased incidence of a second lymphoproliferative malignancy in patients with multiple myeloma- a SEER based study. *Anticancer Res.* 2012; 32(10):4507-15. PubMed PMID: 23060579.
4. Razavi P, Rand KA, Cozen W, Chanan-Khan A, Usmani S, Ailawadhi S. Patterns of second primary malignancy risk in multiple myeloma patients before and after the introduction of novel therapeutics. *Blood Cancer J.* 2013; 3(6): e121. doi: 10.1038/bcj.2013.19.

- PubMed Central PMCID: PMC3698537.
5. Curtis RE, Freedman DM, Ron E, Ries LAG, Hacker DG, Edwards BK, et al. (eds). *New Malignancies Among Cancer Survivors: SEER Cancer Registries, 1973-2000*. Bethesda, MD: National Cancer Institute; 2006
 6. Kumar SK, Rajkumar SV, Dispenzieri A, Lacy MQ, Hayman SR, Buadi FK, et al. Improved survival in multiple myeloma and the impact of novel therapies. *Blood*. 2008; 111(5):2516–20. doi: 10.1182/blood-2007-10-116129. PubMed PMID: 17975015.
 7. Krishnan AY, Mei M, Sun C, Thomas SH, Teh JB, Kang T, et al. Second primary malignancies after autologous hematopoietic cell transplantation for multiple myeloma. *Biol Blood Marrow Transplant*. 2013; 19(2): 260–65. doi: 10.1016/j.bbmt.2012.09.023. PubMed PMID: 23073267.
 8. Jonsdottir G, Lund SH, Bjorkholm M, Turesson I, Wahlin A, Mailankody S, et al. Survival in Multiple myeloma patients who develop second malignancies: A population based cohort study. *Haematologica*. 2016; 101(4):e145-8. doi: 10.3324/haematol.2015.134049.