



PHOTO CLINIC

Solitary Plasmacytoma of the Humerus

Geetha Narayanan*, Rakul Nambiar, Bhavya S Kumar

Department of Medical Oncology, Regional Cancer Centre, Trivandrum 695011, Kerala, India

ARTICLE INFO

Article History:

Received: 12.01.2017

Accepted: 01.03.2017

*Corresponding author:

Geetha Narayanan, MD, DM;

Address: Professor and Head,
Department of Medical Oncology,
Regional Cancer Centre, Trivandrum
695011, India

Tel: +91 944 7500920

Email: geenarayanan@yahoo.com

Please cite this article as: Narayanan G, Nambiar R, Kumar BS. Solitary Plasmacytoma of the Humerus. IJBC 2017; 9(3): 99-100.

A 43-year-old man presented with pain in right arm since one year. A radiograph of the right arm showed an extensive osteolytic lesion involving the diaphysis of the humerus (figure 1). A biopsy and nailing was done. Histopathological examination showed sheets of plasma cells with few immature forms (figure 2). On immunohistochemistry, the tumor cells were CD138 positive with lambda light chain restriction, indicative of plasmacytoma. His hematology and serum chemistries were normal. His quantitative serum immunoglobulins and free kappa lambda were normal. Skeletal survey and bone marrow were normal. He received radiation 40 Gy to the humerus and is currently on follow up.

Solitary plasmacytoma of bone (SPB) is a localized tumor in the bone composed of a single clone of plasma cells in the absence of features of multiple myeloma such as anemia, hypercalcemia, renal insufficiency, or multiple lytic bone lesions. It constitutes about 5% of all plasma cell disorders.¹ The median age at diagnosis is 55 to 65 years and they present with skeletal pain or pathological fracture. SPB occurs more commonly in bones of the axial skeleton such as vertebra and skull.² Involvement of the appendicular skeleton is less frequent and humerus is a rare site for SPB. Diagnosis is confirmed by biopsy showing monoclonal plasma cell infiltration from a single site.

The treatment for SPB is local radiation therapy at a dose of 40-50 Gy. Surgery may be required for patients with structural instability of the bone, or rapidly progressive cord compression. The 10-year overall survival was 73% and local relapse free survival was 94%.³ Overt multiple

myeloma develops in 65-84% of patients in 10 years in spite of radiation therapy and the median time to progression is 2-3 years.^{3,4}

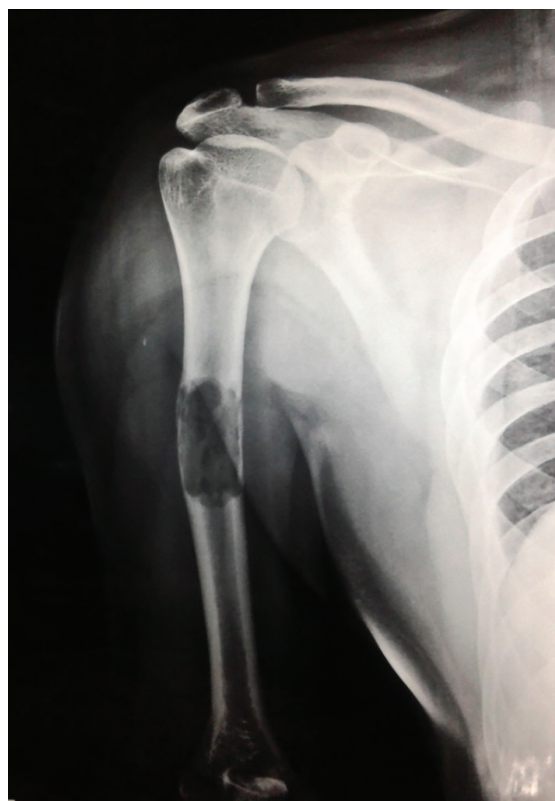

Figure 1: Radiograph of the humerus showing an extensive osteolytic lesion of the right humerus

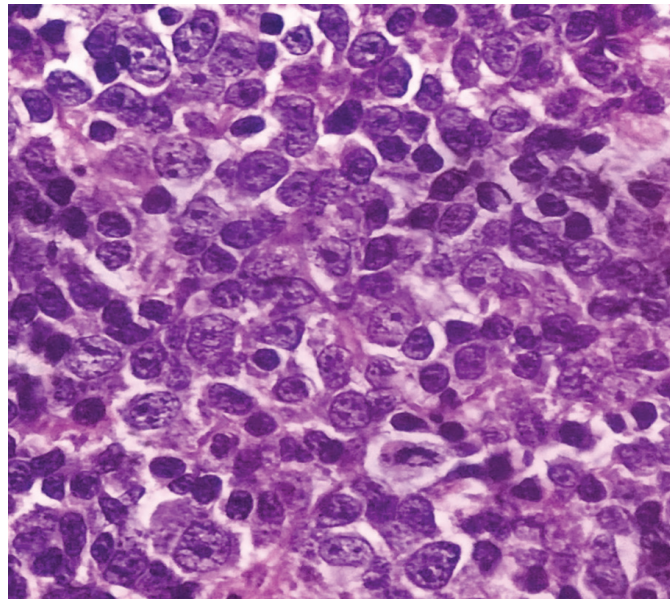


Figure 2: H&E x100 – Section showing sheets of mature plasma cells and few immature forms

Conflict of Interest: None declared.

References

1. Does GM, Landgren O, McGlynn KA, Curtis RE, Linet MS, Devesa SS. Plasmacytoma of bone, extramedullary plasmacytoma and multiple myeloma: incidence and survival in United States, 1992-2004. *B Br J Haematol.* 2009; 144(1):86-94. doi: 10.1111/j.1365-2141.2008.07421.x. PubMed PMID: 19016727. PubMed Central PMCID: PMC2610331.
2. Dimopoulos MA, Haniilos G. Solitary bone plasmacytoma and extramedullary plasmacytoma. *Curr Treat Options Oncol.* 2002; 3: 255–9. doi: 10.1007/s11864-002-0015-2.
3. Kilciksiz S, Celik OK, Agaoglu FY, Haydaroglu A. A review of solitary plasmacytoma of bone and extramedullary plasmacytoma. *Sci World J.* 2012; 2012. doi: 10.1100/2012/895765.
4. Kilciksiz S, Celik OK, Pak Y, Demiral AN, Pehlivan M, Orhan O, et al. Clinical and prognostic features of plasmacytomas: a multicenter study of Turkish Oncology Group—Sarcoma Working Party. *Am J Hematol.* 2008; 83(9):702-7. doi: 10.1002/ajh.21211. PubMed PMID: 18543343.