

PHOTO CLINIC

Recurrent Cytomegalovirus Retinitis in a Patient with Leukemia on Maintenance Chemotherapy

Samin Alavi*, Kourosh Goudarzipour

Pediatric Congenital Hematologic Disorders Research Center, Shahid Beheshti University of Medical Sciences, Tehran, Iran

ARTICLE INFO

Article History:

Received: 27.12.2016

Accepted: 02.02.2017

*Corresponding author:

Samin Alavi, MD;

Address: Pediatric Congenital

Hematologic Disorders Research

Center, Shahid Beheshti University of

Medical Sciences, Tehran, Iran

Email: saminalavi@hotmail.com

Please cite this article as: Alavi S, Goudarzipour K. Recurrent Cytomegalovirus Retinitis in a Patient with Leukemia on Maintenance Chemotherapy. IJBC 2017; 9(1): 29-30.

A 14-year-old boy, known case of acute lymphoblastic leukemia (ALL) on maintenance treatment presented with visual loss in lower half of visual field. Laboratory tests showed pancytopenia. ALL Relapse was ruled out by bone marrow aspiration. An ophthalmologic consultation was done and a diagnosis of "CMV retinitis" was made. CMV-PCR was positive with 3,000,000 copies/ml. CT-scan of chest and abdomen was unremarkable and fungal infection assessments were negative. He was admitted and treatment with intravenous gancyclovir 10 mg/kg/day along with intravitreal injection of gancyclovir was started for the patient. He received a course of 4-week

treatment which was discontinued thereafter.

Nine months later, he referred with fever and pancytopenia while on oral maintenance chemotherapy. Due to prolongation of fever and unexplained cytopenia, a thorough work-up was performed which yielded a plasma CMV-PCR of 3,500,000 copies/ml. Ophthalmologic examination established relapse of "retinitis" (figure 1). Another course of intravenous and intravitreal injection of gancyclovir initiated. He was assigned to receive a prolonged course of maintenance with oral valgancyclovir until attaining negative PCR in order to prevent CMV reactivation.

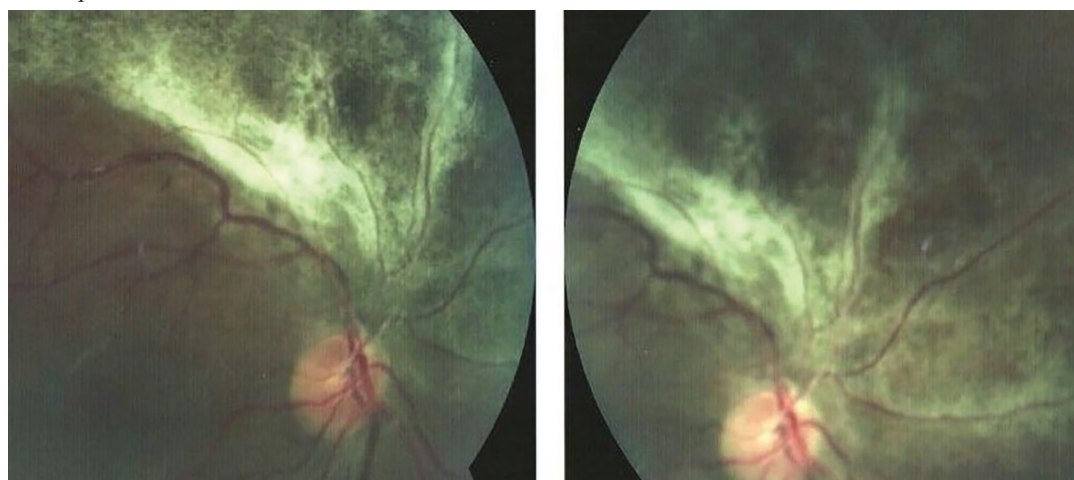


Figure 1: Retinitis in the midperiphery with a "brush fire" pattern

CMV infection is a major cause of morbidity and mortality in immunocompromised patients, particularly in transplant recipients.¹ There are major organ systems which could be involved by CMV and should be considered as “active CMV disease” in immunocompromised patients. They include respiratory, gastrointestinal, and central nervous systems and retina.² In pediatric patients with ALL in the setting of nontransplant, CMV disease is very rare with a few reports in the literature.³ CMV viremia has been reported in 13.6% of patients with lymphoid malignancies who did not receive any stem cell transplantation.⁴ In the nontransplant cases, incidence of CMV retinitis is reported about 3.5% in children with ALL.⁵ Preemptive anti-CMV therapy (routine active screening and treating patients with progressively increasing viral titers) is the recommended strategy in the transplant settings; however, such an strategy is not yet suggested in childhood ALL patients on chemotherapy.³

As CD4+ T-cell lymphopenia is a major risk factor for reactivation of latent CMV infection and developing active disease, routine control for exacerbation of viremia by PCR is recommended by authors in these high-risk patients in setting of nontransplant, specifically in those with a history of previous active disease for which have been treated before. Hence; in case of increasing high copy numbers, preemptive therapy could be suggested and in patients with associated signs and symptoms such as fever and unexplained cytopenia, definite treatment

is indicated.

Conflict of Interest: None declared.

References

1. Singh N, Dummer JS, Kusne S, Breinig MK, Armstrong JA, Makowka L, et al. Infections with cytomegalovirus and other herpesviruses in 121 liver transplant recipients: transmission by donated organ and the effect of OKT3 antibodies. *Journal of Infectious Diseases*. 1988;158(1):124-31.
2. Bhat V, Joshi A, Sarode R, Chavan P. Cytomegalovirus infection in the bone marrow transplant patient. *World journal of transplantation*. 2015;5(4):287.
3. Rahbarimanesh A, Ehsani M, Karahroudi M, Rashidi A, Aghajani M, Meysami A, et al. Cytomegalovirus disease in children with acute lymphoblastic leukemia in the nontransplant setting: case series and review of the literature. *Journal of pediatric hematology/oncology*. 2015;37(6):429-32.
4. Han XY. Epidemiologic analysis of reactivated cytomegalovirus antigenemia in patients with cancer. *Journal of clinical microbiology*. 2007;45(4):1126-32.
5. Samia L, Hamam R, Dbaiibo G, Saab R, El-Solh H, Abboud M, et al. Cytomegalovirus retinitis in children and young adults with acute lymphoblastic leukemia in Lebanon. *Leukemia & lymphoma*. 2014;55(8):1918-21.