



LETTER TO EDITOR

Multiple Myeloma with HBs Antigenemia Presented with Hoarseness and Systemic Amyloidosis

Nasim Valizadeh^{1,2}, Fatemeh Tajic Rostami³, Bahareh Javani⁴

¹Assistant Professor of Hematology and Medical Oncology, Tehran University of Medical Sciences, Tehran, Iran

²Assistant Professor of Hematology and Medical Oncology, Iran University of Medical Sciences, Tehran, Iran

³Assistant Professor of Internal medicine, Iran University of Medical Sciences, Tehran, Iran

⁴Fellowship of Echocardiography, Firouz Abadi Hospital, Shahre Rey, Iran

ARTICLE INFO

Article History:

Received: 12.08.2017

Accepted: 01.10.2017

*Corresponding author:

Nasim Valizadeh,
Assistant professor of Hematology
and medical Oncology, Islamic Azad
University, Tehran Medical Branch,
Amir-al Momenin Hospital,
Tehran, Iran
Tel: +98-912-5474755
Email: nsedaha0@gmail.com

Please cite this article as: Valizadeh N, Tajic Rostami F, Javani B. Multiple Myeloma with HBs Antigenemia Presented with Hoarseness and Systemic Amyloidosis. IJBC 2017; 10(1): 31-32.

Dear Editor

Isolated laryngeal amyloidosis is a rare cause of hoarseness. There are few reports regarding isolated laryngeal amyloidosis.^{1, 2} Literature review shows a potential role for hepatitis B virus (HBV) infection in occurrence of multiple myeloma.³

A 66-year-old man presented with progressive hoarseness and dysphonia for the last 3 years. He had a history of bilateral carpal tunnel syndrome for which he had underwent surgery. Due to macroglossia,

rhinomegaly and proteinuria, biopsy of the skin and oral mucosa was performed which was reported as amyloidosis. Laryngoscopy revealed severe inflammation with bilateral atrophy and stiffness of true vocal cords and hyperfunction of false vocal cord (Figure 1).

ECG findings showed left bundle branch block and atrial fibrillation with rapid ventricular response. Echocardiography revealed mild left ventricular hypertrophy, mild pericardial effusion and decreased tissue velocities. Serum protein electrophoresis was

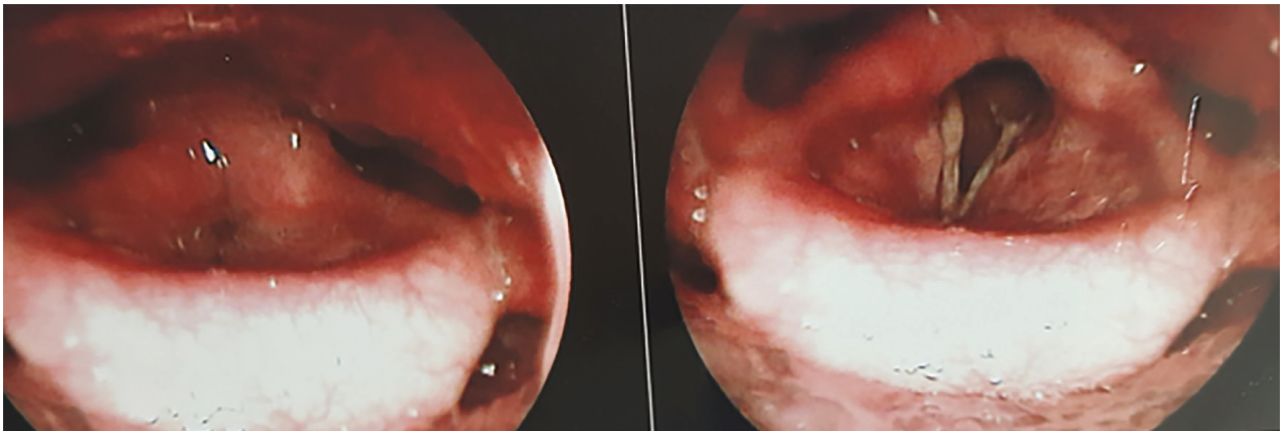


Figure 1: severe inflammation with bilateral atrophy and stiffness of true vocal cords.

normal. CBC showed mild normocytic anemia. ESR was markedly elevated. Bone marrow aspiration and biopsy revealed more than 60% plasma cells compatible with multiple myeloma. During the serologic survey for hepatitis screening, he showed hepatitis B surface antigen positivity, so that he received Tenofovir because of hepatitis B surface antigenemia before starting chemotherapy to prevent viral reactivation.

Amyloidosis of the larynx is a rare benign cause of hoarseness and dysphonia in the context of multiple myeloma. Its diagnosis may be delayed in patients with longstanding hoarseness. Treatment of choice is endoscopic CO₂ laser excision. The prognosis of localized laryngeal amyloidosis is better than systemic AL amyloidosis.¹

HBV infection may be associated with an increased risk of multiple myeloma.^{3,4} HBV reactivation was reported in patients with multiple myeloma after chemotherapy with Bortezomib,⁵⁻⁸ and in a case of primary amyloidosis after melphalan and dexamethasone combination therapy.⁹

We recommend screening for hepatitis B surface antigenemia in all patients with plasma cell dyscrasia including multiple myeloma and amyloidosis. Chemoprophylaxis for viral reactivation with antiviral agents such as lamivudine or tenofovir should be considered in seropositive patients before starting chemotherapy. In similar cases with plasma cell dyscrasia and HBs antigenemia, aggressive therapy is not required, but prophylaxis of viral reactivation with tenofovir before prescribing chemotherapy and further evaluation and follow-up to detect evolution into the systemic disease is suggested.

Conflict of Interest: None declared.

References

- Vignes S, Brasnu D, Hénégat C, Tiev KP, Gèneveau T, Cabane J. [Laryngeal amyloidosis: a rare cause of hoarseness]. *Rev Med Interne*. 2000; 21(12):1121-5. PubMed PMID: 11191679.
- Behnoud F, Baghbanian N. Isolated laryngeal amyloidosis. *Iran J Otorhinolaryngol*. 2013; 25(70): 49–52. PubMed PMID: 24303419. PubMed Central PMCID: PMC3846235.
- Dalia S, Dunker K, Sokol L, Mhaskar R. Hepatitis B seropositivity and risk of developing multiple myeloma or Hodgkin lymphoma: A meta-analysis of observational studies. *Leuk Res*. 2015; 39(12):1325-33. doi: 10.1016/j.leukres.2015.09.008. PubMed PMID: 26394533.
- Li Y, Bai O, Liu C, Du Z, Wang X, Wang G, Li W. Association between hepatitis B virus infection and risk of multiple myeloma: a systematic review and meta-analysis. *Intern Med J*. 2016; 46(3):307-14. doi: 10.1111/imj.12981. PubMed PMID: 26662071.
- Yoshida T, Kusumoto S, Inagaki A, Mori F, Ito A, Ri M, et al. Reactivation of hepatitis B virus in HBsAg-negative patients with multiple myeloma: Two case reports. *Int J Hematol*. 2010; 91(5):844–9. doi: 10.1007/s12185-010-0592-y. PubMed PMID: 20473594.
- Rosiñol L, Montoto S, Cibeira MT, Bladé J. Bortezomib-induced severe hepatitis in multiple myeloma: A case report. *Arch Intern Med*. 2005; 165(4):464–5. doi: 10.1001/archinte.165.4.464. PubMed PMID: 15738379.
- Beysel S, Yegin ZA, Yagci M. Bortezomib-associated late hepatitis B reactivation in a case of multiple myeloma. *Turk J Gastroenterol*. 2010; 21(2):197–8. PubMed PMID: 20872342.
- Lu J, Chen WM, Geng CY, Durie BG, Huang XJ. Efficacy and safety of bortezomib in multiple myeloma patients with hepatitis B: A multicenter retrospective study. *Chin Med J (Engl)*. 2016; 129(3):274-8. doi: 10.4103/0366-6999.174508. PubMed PMID: 26831227. PubMed Central PMCID: PMC4799569.
- Moon WR, Moon DS, Kim J, Yoon YM, Choi BS, Chung CH, et al. Reactivation of hepatitis B (reverse seroconversion) after melphalan/dexamethasone therapy for primary amyloidosis: a case report. *J Med Case Rep*. 2015;9:122. doi: 10.1186/s13256-015-0610-z. PubMed PMID: 26031455.