

CASE REPORT

Adrenocortical Carcinoma Mimicking Pheochromocytoma: A case Report and Review of Literature

Mazaher Ramezani¹, Mahdokht Azizi², Masoud Sadeghi^{3,2*}

¹Molecular Pathology Research Center, Imam Reza Hospital, Kermanshah University of Medical Sciences, Kermanshah, Iran

²Students Research Committee, Kermanshah University of Medical Sciences, Kermanshah, Iran

³Medical Biology Research Center, Kermanshah University of Medical Sciences, Kermanshah, Iran

ARTICLE INFO

Article History:

Received: 06.02.2018

Accepted: 11.04.2018

Keywords:

Adrenocortical carcinoma

Pheochromocytoma

Hypertension

Adrenal gland tumors

Immunohistochemistry

*Corresponding author:

Masoud Sadeghi,
Medical Biology Research Center,
Kermanshah University of Medical
Sciences, Kermanshah, Iran

Email: sadeghi_mbrc@yahoo.com

ORCID: 0000-0002-3586-3012

ABSTRACT

Adrenocortical carcinoma (ACC) is an uncommon malignancy originating from cortex of adrenal gland. The most common pitfall in diagnosis of ACC is to distinguish it from pheochromocytoma. Here we report a 62-year-old hypertensive man with presentation of dyspnea. The laboratory data showed an increase in urine cortisol and renin with a mild increase in aldosterone, but decrease in adrenocorticotrophic hormone. Computerized tomography (CT) scanning revealed heterogeneous mass with enhancement in the adrenal region. The patient underwent surgery with an empirical diagnosis of pheochromocytoma, whereas ACC with high mitotic rate of about 50 mitoses/50 high-power field with vascular invasion was reported on histopathology. Immunohistochemistry was positive for Vimentin, Inhibin- α , Melan-A, and Synaptophysin. Ki-67 was positive in 25% of tumor cells. The results confirmed the diagnosis. ACC should be considered in differential diagnosis of adrenal masses especially in cases of hypertension and Cushing syndrome.

Please cite this article as: Ramezani M, Azizi M, Sadeghi M. Adrenocortical Carcinoma Mimicking Pheochromocytoma: A case Report and Review of Literature. IJBC 2018; 10(3): 92-95.

Introduction

Adrenocortical carcinoma (ACC) is a rare cancer with an incidence of 0.5-2 cases per million. This tumor has unfavorable prognosis and poor response to treatment with a high recurrence rate.¹⁻⁷ Reports of higher incidences of 4 to 12 per million are also noted in the literature.⁷ In histologically suspected cases of ACC, ruling out of metastatic soft tissue tumors and pheochromocytoma is necessary.^{6,8} The most common pitfall in histopathology of ACC is distinguishing it from pheochromocytoma.⁸ Sometimes pathologic differentiation of ACC from pheochromocytoma would be challenging.³ Herein, we report a case of ACC with the clinical impression of pheochromocytoma before surgery that histopathology and immunohistochemistry confirmed the diagnosis.

Case Report

A 62-year-old man was admitted to internal medicine department in March 2017 due to dyspnea at rest for one month. The patient complained of facial and generalized edema of 3-4 months duration with dyspnea, fatigue, and nervousness. In past medical history, the patient was hypertensive for which was taking Prazosin and Losartan. History of diabetes mellitus, cardiac, renal, or thyroid disease was negative. The patient was a heavy smoker who had withdrawn it 4 months before. On physical examination; blood pressure: 150/100 mmHg, pulse rate: 80/min, respiratory rate: 16/min and Temperature: 37°C. The patient had plethoric face with heavy perspiration. Except for generalized edema, physical examination was unremarkable. Laboratory data showed an increase in urine cortisol (24 hours) and renin with a mild increase in

aldosterone but decrease in adrenocorticotrophic hormone (Table 1 and 2). Computerized tomography (CT) scanning revealed heterogeneous mass with enhancement in the adrenal region suggestive for lesions like adenoma. He was admitted to the surgery department and underwent surgery with an empiric diagnosis of pheochromocytoma. The specimen consisted of irregular light brown-yellow fragile tissue fragments measuring 4×4×3 cm with red-yellow cut surface. It was sent to pathology department for frozen and permanent section diagnosis. The frozen section diagnosis was compatible with adrenal cortical neoplasm with 10% necrosis of surface area. The margins could not be evaluated due to fragmentation. The pathologist finally reported the tumor as adrenal cortical carcinoma with the high mitotic rate of about 50 mitoses/50 high-power field (Figure 1). Infiltrative border and necrosis in 30% of the surface area and vascular invasion was evident on pathologic examination. IHC was recommended for confirmation of the diagnosis. IHC was reported as positive for Vimentin, Inhibin- α (Figure 2), Melan-A (Figure 3), and Synaptophysin. CK and Chromogranin (Figure 4) were negative. Ki-67 was positive in 25% of tumor cells. The results were all in favor of adrenal cortical carcinoma.

Discussion

We reported a 62-year-old hypertensive man with Cushing syndrome who was presented with dyspnea. Although clinical diagnosis of pheochromocytoma was suggested, histopathology and IHC was compatible with the diagnosis of ACC.

ACC may occur at any age slightly more common in women (male/female: 1/1.1).⁷ Mean age at diagnosis is about 44.4 years with primary tumor size of 12.2±5.2 cm in adults. Most of them are non-functioning (69%).

Tumor size, Ki-67 index, stage, resection status, surgical intervention, and hormonal secretion including isolated hyperandrogenism are significantly associated with overall survival.^{2, 4, 9} Miura et al.⁵ reported the 3-year cause-specific survival rate of 56% for ACCs. We confirmed our diagnosis by using IHC technique. Positivity of Inhibin, Melan-A, and Synaptophysin was

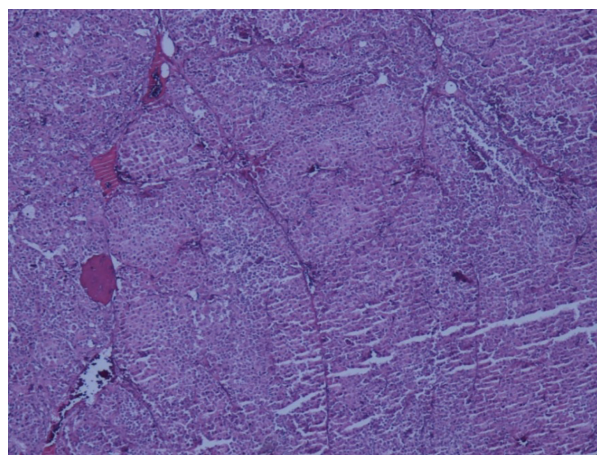


Figure 1: Adrenal cortical carcinoma, Hematoxylin-Eosin staining (x40 magnification)

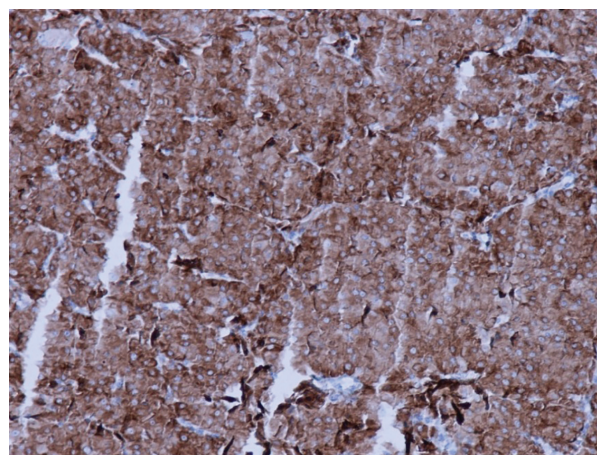


Figure 2: Inhibin- α positivity, Immunohistochemistry staining (x100 magnification)

all in favor of ACC. We also used staining for Ki-67; a marker which is useful in differentiation of ACC from benign tumors.¹⁰ There is a report that more than 50% of ACC cases lacked Ki-67.⁸ Prognostic significance of Ki-67 immunostaining should be kept in mind by pathologists.⁸ The most common presenting symptom of adrenocortical tumors in children is Cushing syndrome.¹¹ Veron Esquivel et al.¹² reported a case of ACC as a rare

Table 1: Lab data of the patient 45 days before surgery

	Value	Reference range
Aldosterone	400.1 pg/ml	Early morning supine: 20-180, Upright: 30-400
Renin (Upright)	577.1 μ IU/dl	4.4-46.1
Urine Metanephrine (24 hr)	98.1 μ g	25-312
Adrenocorticotrophic hormone	2.54 pg/ml	7.2-63.3
Urine Normetanephrine (24 hr)	229 μ g/dl	up to 600
Urine Cortisol (24 hr)	884 μ g	50-190
Urine volume	1900 mL	600-1800

Table 2: Lab data about 10 days after surgery

	Value	Reference range
Adrenocorticotrophic hormone	1.33 pg/ml	7.2-63.3
Free Urine Cortisol (24 hr)	227 μ g	12.8-82.5
Urine volume(24 hr)	800 ml	500-1600
Urine Creatinin (24 hr)	680 mg/kg body weight	Men: 20-26

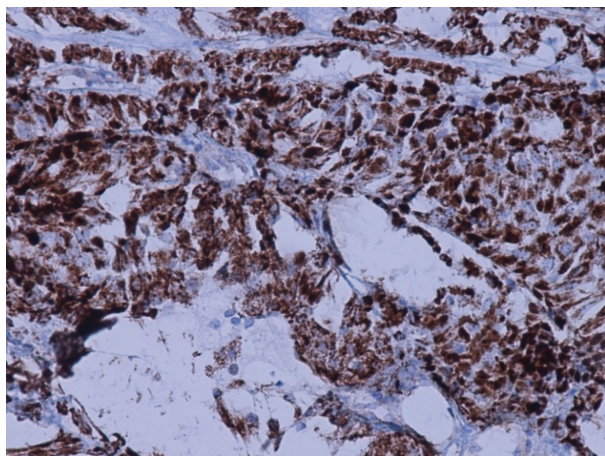


Figure 3: Melan-A positivity, Immunohistochemistry staining (x200 magnification)

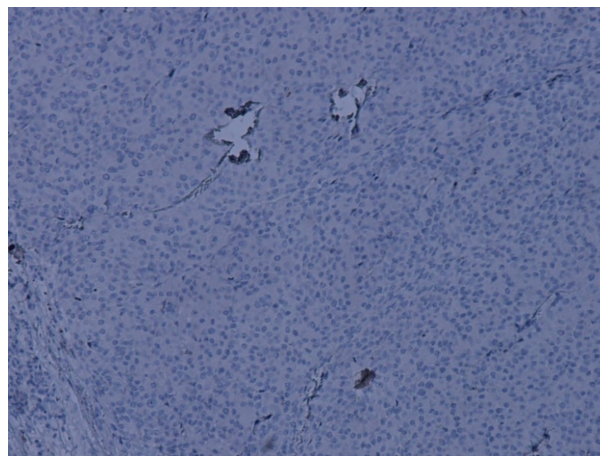


Figure 4: Chromogranin negativity, Immunohistochemistry staining (x100 magnification)

cause of secondary hypertension in a 39-year-old woman. Admission was due to hypertension, severe hypokalemia and metabolic alkalosis. The patient had a plethoric moon face, centripetal obesity and bilateral lower extremity edema. Laboratory testing demonstrated a rise in the levels of aldosterone, renin, cortisol, testosterone, and androstenedione. After surgery of right adrenal gland mass and hepatic lesion, the pathologist diagnosed ACC with liver metastasis. Hyperaldosteronism is a cause of secondary hypertension and is usually associated with benign lesions. ACC is a rare, aldosterone secreting tumor in which hypertension usually improves after surgical resection.

In functional adrenal tumors, hormone production may cause hypokalemia, hypertension, palpitation, nervousness or panic attacks, perspiration, diabetes mellitus, cushing syndrome, changes in body weight, abdominal skin striae and abnormal hair growth.⁷ Diagnosis of ACC requires physical examination, blood and urine tests in functional tumors and imaging techniques. The treatment depends on the stage and includes surgery, chemotherapy and targeted therapy. Radiation therapy may also be used as adjuvant therapy. Adrenal incidentaloma is an asymptomatic adrenal mass which is found incidentally on imaging of abdomen for causes not related to adrenal disease. Mostly, they are nonfunctional adrenocortical adenomas; but rarely, ACC, pheochromocytoma, hormone-producing adenoma, or metastasis could be found as incidentalloma.⁷ The authors previously reported a 67-year-old woman with hypertension and cushingoid features that finally was found to have a large ACC.¹³ It seems that according to the findings of these two reports in cases of hypertension and Cushing syndrome, ACC should be strongly considered in differential diagnosis of such presentations.

It is known that Wilm's tumor, renal cell carcinoma, ACC, and hepatocellular carcinoma have high rate of associated tumor thrombosis. The presence of tumor thrombosis deteriorates the prognosis and could have impacts on initial management and treatment decisions. Tumor thrombosis in ACC is reported in about 25% of the patients.¹⁴ Systemic chemotherapy is the treatment of choice in tumor thrombosis.¹⁴ Recently, Perrino et

al.¹⁵ demonstrated that GATA3 (Trans-acting T-cell-specific transcription factor) immunohistochemical marker can be used for the differentiation between ACC and Pheochromocytoma in a panel, which negativity is in favor of ACC. The main differential diagnoses of ACC include: adrenocortical adenoma, myelolipoma, metastatic lesions of adrenal, pheochromocytoma, adrenal cyst, ganglioneuroma or other rare tumors of the adrenal gland such as sarcoma or lymphoma.¹⁶

Conclusion

ACC mimics pheochromocytoma in terms of clinical manifestations. It should be considered in differential diagnosis of adrenal masses especially in cases of hypertension and Cushing syndrome. Immunohistochemistry positive for Inhibin- α , Melan-A, Synaptophysin and Ki-67 is useful for the confirmation of the diagnosis of ACC.

Acknowledgment

Mrs. Sholeh Akradi contributed in providing data of the patient. Her contribution is greatly appreciated. The authors would like to thank Clinical Research Development Center of Imam Reza Hospital for Consulting Services.

Conflict of Interest: None declared.

References

1. Şişman P, Şahin AB, Peynirci H, Cander S, Öz Gül O, Ertürk E, et al. Adrenocortical carcinoma: Single center experience. *Turk J Urol.* 2017; 43(4):462-9. doi:10.5152/tud.2017.81598. PubMed PMID: 29201509. PubMed Central PMCID: PMC5687209.
2. Choi YM, Kwon H, Jeon MJ, Sung TY, Hong SJ, Kim TY, et al. Clinicopathological features associated with the prognosis of patients with adrenal cortical carcinoma: usefulness of the Ki-67 index. *Medicine (Baltimore).* 2016; 95(21):e3736. doi:10.1097/MD.0000000000003736. PubMed PMID: 27227935.
3. Gogoi G, Baruah MP, Borah P, Borgohain M. Adrenocortical carcinoma: an extremely uncommon entity and the role of Immunohistochemistry in its

- diagnosis. *Indian J Endocrinol Metab.* 2012; 16 (Suppl 2):S373-S375. doi:10.4103/2230-8210.104098. PubMed PMID: 23565434.
4. Scollo C, Russo M, Trovato MA, Sambataro D, Giuffrida D, Manusia M, et al. Prognostic Factors for Adrenocortical Carcinoma Outcomes. *Front Endocrinol (Lausanne).* 2016;7:99. doi:10.3389/fendo.2016.00099. PubMed PMID: 27504106.
 5. Miura N, Ide T, Uda T, Noda T, Asai S, Nishimura K, et al. [Clinicopathologic characteristics and prognosis of patients with adrenocortical carcinoma]. *Nihon Hinyokika Gakkai Zasshi.* 2014; 105(3):79-84. PubMed PMID: 25158548.
 6. Erickson LA. Challenges in surgical pathology of adrenocortical tumours. *Histopathology.* 2018; 72(1):82–96. doi: 10.1111/his.13255. PubMed PMID: 29239032.
 7. Kranjčević K. [ADRENOCORTICAL CARCINOMA]. *Acta Med Croatica.* 2016; 70(4-5):315-8. PubMed PMID: 29087170.
 8. Duregon E, Volante M, Bollito E, Goia M, Buttigliero C, Zaggia B, et al. Pitfalls in the diagnosis of adrenocortical tumors: a lesson from 300 consultation cases. *Hum Pathol.* 2015; 46(12):1799-807. doi: 10.1016/j.humpath.2015.08.012. PubMed PMID: 26472162.
 9. Sabaretnam M, Mishra A, Agarwal G, Agarwal A, Verma AK, Mishra SK. Adrenocortical carcinoma in children and adults: Two decades experience in a single institution. *Indian J Cancer.* 2016; 53(2):317-21. doi: 10.4103/0019-509X.197737. PubMed PMID: 28071637.
 10. Dalino Ciaramella P, Vertemati M, Petrella D, Bonacina E, Grossrubatscher E, Duregon E, et al. Analysis of histological and immunohistochemical patterns of benign and malignant adrenocortical tumors by computerized morphometry. *Pathol Res Pract.* 2017; 213(7):815-23. doi: 10.1016/j.prp.2017.03.004. PubMed PMID: 28554744.
 11. Lin X, Wu D, Chen C, Zheng N. Clinical characteristics of adrenal tumors in children: a retrospective review of a 15-year single-center experience. *Int Urol Nephrol.* 2017; 49(3):381-5. doi: 10.1007/s11255-016-1480-z. PubMed PMID: 27988912.
 12. Veron Esquivel D, Batiz F, Farias Vega A, Carrillo Gonzalez PA. Adrenocortical carcinoma, an unusual cause of secondary hypertension. *BMJ Case Rep.* 2016; 2016. pii: bcr2016217918. doi: 10.1136/bcr-2016-217918. PubMed PMID: 27927710.
 13. Ramezani M, Kavousi F, Amirian F, Sadeghi M. Adult adrenocortical carcinoma mass with extension into the inferior vena cava and cushingoid features: a rare case with the review of literature. *Basic & Clinical Cancer Research.* 2017; 9(1):40-5.
 14. Quencer KB, Friedman T, Sheth R, Oklu R. Tumor thrombus: incidence, imaging, prognosis and treatment. *Cardiovasc Diagn Ther.* 2017; 7(Suppl 3):S165-S77. doi: 10.21037/cdt.2017.09.16. PubMed PMID: 29399520.
 15. Perrino CM, Ho A, Dall CP, Zynger DL. Utility of GATA3 in the differential diagnosis of pheochromocytoma. *Histopathology.* 2017; 71(3):475-9. doi: 10.1111/his.13229. PubMed PMID: 28374498.
 16. Else T, Kim AC, Sabolch A, Raymond VM, Kandathil A, Caoili EM, et al. Adrenocortical Carcinoma. *Endocr Rev.* 2014; 35(2):282-326. doi: 10.1210/er.2013-1029. PubMed PMID: 24423978.