

ORIGINAL ARTICLE

Efficacy of Rituximab in the Treatment of Plasma Exchange Refractory Thrombotic Thrombocytopenic Purpura

Alireza Sadeghi¹, Farzaneh Ashrafi¹, Arman Sourani^{2*}

¹Department of Hematology-Oncology, School of medicine, Isfahan University of Medical Sciences, Isfahan, Iran

²Student Research Committee, School of medicine, Isfahan University of Medical sciences, Isfahan, Iran

ARTICLE INFO

Article History:

Received: 07.02.2018

Accepted: 13.05.2018

Keywords:

Rituximab
Thrombotic thrombocytopenic purpura
Plasma exchange
Refractory

*Corresponding author:

Arman Sourani,
General Practitioner, Student Research Committee, School of medicine, Alzahra Teaching Hospital, Isfahan University of Medical Sciences, Zip code: 81368-33691, Isfahan, Iran
Tel: +98 913 4136606
Fax: +98 31 36625258
Email: armansourani@yahoo.com

ABSTRACT

Background: Rituximab can induce a durable remission in plasma exchange refractory thrombotic thrombocytopenic purpura (TTP). Timing of Rituximab infusion in combination with plasma exchange (PE) and long term follow-up for probable side effects of such treatment is still lacking.

Methods: This study was conducted among 10 patients with plasma exchange refractory TTP. According to the study designation, first PE was performed within 36-48 hours after first dose of rituximab.

Results: Eight of ten (80%) patients received 1 course of rituximab. Two of ten (20%) patients received another course of rituximab due to relapse. Response rate (RR) to rituximab in combination with plasma exchange, was 90%. Overall Survival of the patients was 90% and 1 and 5-year relapse free survival rate (RFS) was 90% and 83%, respectively. One of the patients expired due to Systemic Lupus Erythematosus flare up.

Conclusion: According to this study, treatment of refractory TTP with rituximab in combination with PE could be effective.

Iranian Registry of Clinical Trials: IRCT2017012232125N1

Please cite this article as: Sadeghi AR, Ashrafi F, Sourani A. Efficacy of Rituximab in the Treatment of Plasma Exchange Refractory Thrombotic Thrombocytopenic Purpura. IJBC 2018; 10(3): 87-91.

Introduction

Thrombotic thrombocytopenic purpura (TTP) is defined as a pentad including microangiopathic hemolytic anemia, thrombocytopenia, renal failure, neurological deterioration and fever which each of them may present simultaneously or succeeding while the disease progresses.¹ Today, corticosteroids and plasma exchange are first line treatments in most of the patients with TTP.^{2,3} Plasma exchange has reduced mortality rate of the patients with TTP from almost 90% to 10-20% in first episode of TTP.⁴ According to a report by American Society of Hematology (ASH), 6-month survival of patients treated with plasma exchange and plasma infusion has been demonstrated to be 73% and 63%, respectively.⁴ It is remarkable that in 30-60% of patients, TTP does not remit adequately with conventional therapies or relapses within

a few months with severe clinical manifestations.⁵⁻⁷

Splenectomy may end the destructive process of opsonized platelets with VWF-ultra large multimers in the spleen. It has been shown that splenectomy can be effective in a specific group of the patients.⁸ Results of the splenectomy in treatment of TTP ranges from long term complete remission to immediate post-operative death;⁸⁻¹⁰ however, most of the patients were remained among refractory or relapsing groups.^{9,11} Robust criteria to select proper patients for splenectomy are still lacking. In a review of the literature, the majority of the candidates for splenectomy were selected from refractory or relapsing cases with stable general condition.^{8,9} Selection of such cases mostly is based on clinician point of view and medical condition of the patients.^{9,12} On the other hand, overwhelming post splenectomy infection (OPSI) cannot

be ignored.¹³ Clinical scenario of OPSI varies from a mild Flu-like syndrome to rapidly progressing fatal sepsis.¹⁴
¹⁵ Most pathogens associated with asplenic patients are encapsulated organisms, but any pathogen organism can cause the infection.

Rituximab, an anti-CD20 chimeric monoclonal antibody has been proposed for treatment of refractory TTP patients.^{16, 17} The suggested mechanism of action is normalizing the level of ADAMTS13 by inhibition of autoantibodies against ADAMTS13.^{17, 18} Rituximab, similar to other immunoglobulins is distributed throughout the interstitium, lymphatic tissues, spleen and bone marrow which are not affected by plasma exchange. On the other hand, Rituximab has several mechanisms of action that is not restricted to its presence in the plasma.¹⁹
²⁰ In some studies, efficacy of rituximab has been evaluated as an end-point in treatment of refractory TTP.^{2, 5, 6, 18, 21} Numerous studies have discussed that plasma exchange can remove Rituximab off the peripheral blood circulation, therefore could reduce efficacy of rituximab, especially with intervals less than 3 days.^{22, 23}

Kelesidis and colleagues declared that rituximab can increase the incidence and severity of infections. Clinical picture of infections in rituximab-treated patients has a wide spectrum from simple skin infections to severe sepsis.²⁴ Theoretically, when rituximab and splenectomy are both administered, the possible infections carry a higher mortality rate.

There are several issues regarding administration of rituximab which need to be addressed such as necessity of continuation of plasma exchange along with rituximab, timing between rituximab infusion and plasma exchange as well as dose adjustment of rituximab in cases undergoing plasma exchange.⁴

In this paper, we describe 10 cases of refractory TTP who successfully responded to treatment with rituximab and simultaneous plasma exchange.

Materials and Methods

This study was conducted in Alzahra Hospital, Isfahan, Iran during 2009-2015. It was registered in Iranain clinical trial data center with ID number “IRCT2017012232125N1” and approved by “Isfahan University of medical sciences” Ethics Committee with ID number of “391368.”

All TTP patients who were refractory to first line treatment were enrolled into the study. Informed consents were obtained and patients were free to leave the study on their own will.

Patients with the following conditions were excluded from the study: viral infections (e.g. HIV), disseminated

intravascular coagulopathy, current pregnancy, autoimmune connective tissue disorders, malignancies, immunosuppression by any other cause, specific bacterial infections (e.g. Pneumococci) as well as patients who used certain drugs or chemicals (calcineurin inhibitors, mitomycin, cocaine and quinine).

This study was designed as to prescribe combination of rituximab (MabThera®) with simultaneous plasma exchange to achieve targeted responses, which was defined as Platelet count above 150000/ μ L for 2 consecutive days accompanied by normal or normalizing LDH and stable or improving neurological deficits. Table 1 Shows the definition of related scientific terms used in our study.²⁵

As first line treatment of TTP, patients were treated with corticosteroids and plasma exchange. Based on clinical presentation and laboratory tests, plasma exchange was recommended daily or every other day. Failure of plasma exchange was defined as no considerable change in clinical or laboratory status of the patients. Refractory TTP was defined as no treatment response by day 30 and/or no durable treatment response by day 60. Those who had not responded to first line treatment, were candidates to receive second line treatment. Rituximab was administered as weekly infusion of 375 mg/m² for a 4-week period. The patients received plasma exchange just before infusion of rituximab. The next session of plasma exchange was performed 36-48 hours after rituximab infusion. The ultimate number of plasma exchange sessions were based on clinical outcome and laboratory test results.

Clinical and laboratory results were closely observed daily for the first 4 weeks and then weekly for the next 12 weeks and thereafter, every 2-3 months for the next 3-4 year. At the end of the follow-up period; complete response, partial response, disease free survival, mortality, side effects and episodes of relapse were analyzed.

Results

10 patients with TTP who were refractory to corticosteroids and plasma exchange enrolled the study (Figure 1). Patients' data are provided in Tables 2 and 3. Five patients were male with mean age of 32.1 years. Mean number of plasma exchange sessions after starting rituximab was 4. Eight patients received one course of rituximab to achieve complete remission. Average period of remission was 38 months. In two patients, (patient 3 and 5), TTP relapsed after 8 and 36 months, respectively. Both of the relapsed cases received rituximab and plasma exchange sessions again. Patient 3 achieved complete

Table 1: Definitions of terms related to current article

Term	Definition
Treatment response	Platelet count above 150000/ μ L for 2 consecutive days accompanied by normal or normalizing LDH and stable or improving neurological deficits.
Durable response	Treatment response (as defined above) which is lasting at least 30 days after discontinuation of plasma exchange.
Exacerbation	Recurrent disease within 30 days after reaching treatment response.
Relapse	Recurrent disease within 30 days after reaching treatment response.
Refractory disease	No treatment response by day 30 and/or no durable treatment response by day 60

Table 2: Detailed laboratory data of the enrolled patients

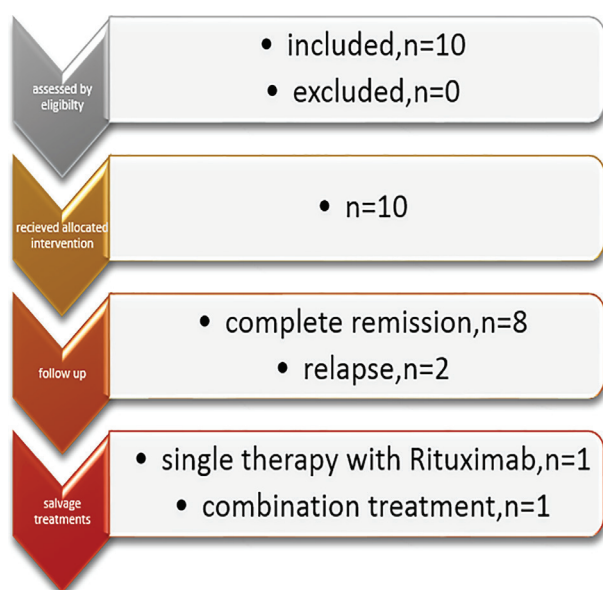
Patient number	Age	Sex	Hb	Plt	Ret%	LDH	Cr	Bill(T)	Bill(D)
1	44	F	8.4	45000	11	1480	0.5	6.3	0.6
2	35	F	9.2	9000	6.8	1338	1.1	7	1.1
3	38	M	10.2	7000	4.8	2860	1.1	7.3	0.7
4	34	M	9.6	22000	4.8	1650	0.6	1.3	0.2
5	40	F	6.6	19000	8.8	1900	1	4.3	0.3
6	26	M	6.9	30000	6	4414	1.3	3.6	1
7	28	M	6.8	6000	8	2400	1.1	2.6	0.7
8	25	F	10.5	15000	5.8	1150	0.5	0.8	0.2
9	24	F	9.2	21000	3.8	1040	0.6	2.7	0.3
10	27	M	8.3	10000	18.5	1470	0.7	5.7	0.5
Mean	32.1	N/A	8.5	15700	7.8	1970	0.75	4.16	0.56

Hb: Hemoglobin (mg/dL); Plt: Platelet count (count/ μ L); Ret%: Reticulocyte percent; LDH: Serum lactate dehydrogenase level (IU); Cr: Serum creatinine (mg/dL); Bill (T&D): Bilirubin total&direct, respectively (mg/dL)

Table 3: Admission, treatments and follow up data

Patient number	Clinical presentation	Primary Plasma exchanges	Interval Plasma exchanges	Rituximab Course(s)	Adjunctive therapies	Admission days	Complete Remission duration	Relapse(s)
1	LOC	7	4	1	-	21	30	-
2	Epistaxis Echymosis	7	3	1	-	15	52	-
3	Petechiae Fatigue	7	5	2	-	42	40	1
4	Hemisensory deficit Paresthesia	6	3	1	-	14	55	-
5	HELLP Petechiae, pupura Epistaxis	30	7	2	Splenectomy Vincristine cyclophosphamide	50	34	1
6	GIB & GTC	7	3	1	-	40	41	-
7	LOC & GTC	17	4	1	-	34	45	-
8	Postpartum hemorrhage	10	3	1	-	17	9	-
9	Petechiae & purpura	10	3	1	-	15	28	-
10	Petechiae	10	3	1	-	18	50	-
Mean value	N/A	11	4	1	N/A	26.6	37.5	N/A

LOC: Loss of consciousness; GIB: Gastrointestinal bleeding; GTC: Generalized tonic clonic seizure, HELLP: HELLP syndrome

**Figure 1:** The overview of study outcomes in 10 patients with TTP.

remission in two weeks. Patient 5 received vincristine and cyclophosphamide and underwent splenectomy to attain complete remission. In relapsed cases, duration of second complete remission was 40 and 32 months, respectively. In the follow-up period, no serious side effect associated with rituximab infusion was observed. Patient 5 was further diagnosed with Systemic Lupus Erythematosus (SLE), who died during flare up of the disease and overwhelming sepsis. 1 and 5-year relapse free survival rate was 90% and 50%, respectively.

Discussion

The necessity of verification of and timing of rituximab along with plasma exchange as second line treatment of TTP was examined in our study.

In this study, response rate of rituximab alone to induce clinical remission in acute refractory and/or relapsing TTP was 90% which was similar to other studies.⁴ Goyal et al. reported that in TTP patients treated with rituximab; 1, 3 and 5-year relapse free-survival rates were 92%, 75%, and 75%, respectively.²⁶

There are various side effects and pharmacological considerations in administration of rituximab including: infusion reactions, kidney injuries, infectious side effects, neurological deteriorations, cardiac events, long term neoplastic occurrence, gastrointestinal adverse effects and dermatologic reactions.²⁷ Most of the side effects are reported in lymphoma and rheumatoid arthritis cases and less frequently in TTP patients.^{24, 27} Due to possible serious and life-threatening side effects of rituximab, the necessity of close and long term surveillance of rituximab-treated patients is of paramount importance. Thus far, infectious complications of rituximab in TTP patients is not detected. In the current clinical trial, no serious side effect of rituximab infusion was observed.

Application of cytotoxic therapeutics, including cyclophosphamide and vincristine has been limited after introduction of rituximab. It would be rational to consider this treatment in subset of patients who are not responsive to rituximab and Plasma exchange.^{4, 28} In this study, treatment with vincristine and cyclophosphamide in patient 5 who further was diagnosed with SLE had no desirable response.

Follow up strategies ensued in current trial include: periodic targeted laboratory work-up (electrolytes, peripheral blood count) and physical examination (special emphasis on cardiovascular, kidney, GI tract, integumentary system and nervous system). This strategy makes the disease and its complications more predictable and controllable.

Funding Resources

This study was supported by Isfahan University of Medical Sciences.

Acknowledgement

The authors would like to thank the patients' families for their trust and cooperation.

Conflict of Interest: None declared.

References

- Blombery P, Scully M. Management of thrombotic thrombocytopenic purpura: current perspectives. *J Blood Med*. 2014;5:15-23. doi: 10.2147/JBM.S46458. PubMed PMID: 24523598; PubMed Central PMCID: PMC3921093.
- Rock GA. Management of thrombotic thrombocytopenic purpura. *Br J Haematol*. 2000;109(3):496-507. PubMed PMID: 10886194.
- Durand JM, Lefevre P, Kaplanski G, Telle H, Soubeyrand J. Vincristine for thrombotic thrombocytopenic purpura. *Lancet*. 1992;340(8825):977-8. PubMed PMID: 1357383.
- Sayani FA, Abrams CS. How I treat refractory thrombotic thrombocytopenic purpura. *Blood*. 2015;125(25):3860-7. doi: 10.1182/blood-2014-11-551580. PubMed PMID: 25784681; PubMed Central PMCID: PMC3921093.
- Shah N, Rutherford C, Matevosyan K, Shen YM, Sarode R. Role of ADAMTS13 in the management of thrombotic microangiopathies including thrombotic thrombocytopenic purpura (TTP). *Br J Haematol*. 2013;163(4):514-9. doi: 10.1111/bjh.12569. PubMed PMID: 24111495.
- Sadler JE, Moake JL, Miyata T, George JN. Recent advances in thrombotic thrombocytopenic purpura. *Hematology Am Soc Hematol Educ Program*. 2004;407-23. doi: 10.1182/asheducation-2004.1.407. PubMed PMID: 15561695.
- Ridolfi RL, Bell WR. Thrombotic thrombocytopenic purpura. Report of 25 cases and review of the literature. *Medicine (Baltimore)*. 1981;60(6):413-28. PubMed PMID: 7031412.
- Rutkow IM. Thrombotic thrombocytopenic purpura (TTP) and splenectomy: a current appraisal. *Ann Surg*. 1978;188(5):701-5. PubMed PMID: 568920; PubMed Central PMCID: PMC3921093.
- Dubois L, Gray DK. Case series: splenectomy: does it still play a role in the management of thrombotic thrombocytopenic purpura? *Can J Surg*. 2010;53(5):349-55. PubMed PMID: 20858382; PubMed Central PMCID: PMC2947115.
- Aqui NA, Stein SH, Konkle BA, Abrams CS, Strobl FJ. Role of splenectomy in patients with refractory or relapsed thrombotic thrombocytopenic purpura. *J Clin Apher*. 2003;18(2):51-4. doi: 10.1002/jca.10053. PubMed PMID: 12874815.
- Outschoorn UM, Ferber A. Outcomes in the treatment of thrombotic thrombocytopenic purpura with splenectomy: a retrospective cohort study. *Am J Hematol*. 2006;81(12):895-900. doi: 10.1002/ajh.20678. PubMed PMID: 16888787.
- Kappers-Klunne MC, Wijermans P, Fijnheer R, Croockewit AJ, van der Holt B, de Wolf JT, et al. Splenectomy for the treatment of thrombotic thrombocytopenic purpura. *Br J Haematol*. 2005;130(5):768-76. doi: 10.1111/j.1365-2141.2005.05681.x. PubMed PMID: 16115135.
- Waghorn DJ. Overwhelming infection in asplenic patients: current best practice preventive measures are not being followed. *J Clin Pathol*. 2001;54(3):214-8. PubMed PMID: 11253134; PubMed Central PMCID: PMC3921093.
- Sinwar PD. Overwhelming post splenectomy infection syndrome – Review study. *International Journal of Surgery*. 2014;12(12):1314-6. doi: 10.1016/j.ijss.2014.11.005.
- Okabayashi T, Hanazaki K. Overwhelming postsplenectomy infection syndrome in adults - a clinically preventable disease. *World J Gastroenterol*. 2008;14(2):176-9. PubMed PMID: 18186551; PubMed Central PMCID: PMC3921093.
- Gutterman LA, Kloster B, Tsai HM. Rituximab therapy for refractory thrombotic thrombocytopenic purpura. *Blood Cells Mol Dis*. 2002;28(3):385-91. PubMed PMID: 12367582.
- Tsai HM, Shulman K. Rituximab induces remission of cerebral ischemia caused by thrombotic thrombocytopenic purpura. *Eur J Haematol*. 2003;70(3):183-5. PubMed PMID: 12605663.

18. Fakhouri F, Vernant JP, Veyradier A, Wolf M, Kaplanski G, Binaut R, et al. Efficiency of curative and prophylactic treatment with rituximab in ADAMTS13-deficient thrombotic thrombocytopenic purpura: a study of 11 cases. *Blood*. 2005;106(6):1932-7. doi: 10.1182/blood-2005-03-0848. PubMed PMID: 15933059.
19. Weiner GJ. Rituximab: mechanism of action. *Semin Hematol*. 2010;47(2):115-23. doi: 10.1053/j.seminhematol.2010.01.011. PubMed PMID: 20350658; PubMed Central PMCID: PMC2848172.
20. Pescovitz MD. Rituximab, an anti-cd20 monoclonal antibody: history and mechanism of action. *Am J Transplant*. 2006;6(5 Pt 1):859-66. doi: 10.1111/j.1600-6143.2006.01288.x. PubMed PMID: 16611321.
21. Sadler JE. Von Willebrand factor, ADAMTS13, and thrombotic thrombocytopenic purpura. *Blood*. 2008;112(1):11-8. doi: 10.1182/blood-2008-02-078170. PubMed PMID: 18574040; PubMed Central PMCID: PMC2435681.
22. Azzopardi N, Francois M, Laurent E, Paintaud G, Birmele B. Influence of plasma exchange on rituximab pharmacokinetics. *Br J Clin Pharmacol*. 2013;76(3):486-8. doi: 10.1111/bcp.12167. PubMed PMID: 23713740; PubMed Central PMCID: PMC3769676.
23. Puisset F, White-Koning M, Kamar N, Huart A, Haberer F, Blasco H, et al. Population pharmacokinetics of rituximab with or without plasmapheresis in kidney patients with antibody-mediated disease. *Br J Clin Pharmacol*. 2013;76(5):734-40. doi: 10.1111/bcp.12098. PubMed PMID: 23432476; PubMed Central PMCID: PMC3853532.
24. Kelesidis T, Daikos G, Boumpas D, Tsiodras S. Does rituximab increase the incidence of infectious complications? A narrative review. *International Journal of Infectious Diseases*. 2011;15(1):e2-e16. doi: 10.1016/j.ijid.2010.03.025.
25. Sarode R, Bandarenko N, Brecher ME, Kiss JE, Marques MB, Szczepiorkowski ZM, et al. Thrombotic thrombocytopenic purpura: 2012 American Society for Apheresis (ASFA) consensus conference on classification, diagnosis, management, and future research. *Journal of Clinical Apheresis*. 2014;29(3):148-67. doi: 10.1002/jca.21302.
26. Goyal J, Adamski J, Lima JL, Marques MB. Relapses of thrombotic thrombocytopenic purpura after treatment with rituximab. *J Clin Apher*. 2013;28(6):390-4. doi: 10.1002/jca.21289. PubMed PMID: 23857472.
27. Kasi PM, Tawbi HA, Oddis CV, Kulkarni HS. Clinical review: Serious adverse events associated with the use of rituximab - a critical care perspective. *Crit Care*. 2012;16(4):231. doi: 10.1186/cc11304. PubMed PMID: 22967460; PubMed Central PMCID: PMC3580676.
28. Ferrara F, Annunziata M, Pollio F, Palmieri S, Copia C, Mele G, et al. Vincristine as treatment for recurrent episodes of thrombotic thrombocytopenic purpura. *Ann Hematol*. 2002;81(1):7-10. doi: 10.1007/s00277-001-0395-6. PubMed PMID: 11807628.