IJBC 2018; 10(4): 133-135

Iranian Journal of Blood & Cancer

Journal Home Page: www.ijbc.ir



Case Report

Can Macrothrombocytopenia Mislead the Treatment of Idiopathic Thrombocytopenia Purpura?

Mohammad Ghorbani[1], Hamid Reza Niazkar[2*], Mohammad Mehdi Ejtehadi[3], Reza Mahmoudi[4], Abbasali Abbasnezhad[5]

[1]Department of Hematology and Blood Banking, Gonabad University of Medical Sciences, Gonabad, Iran
[2]Medical Student, Student Research Committee, Gonabad University of Medical Sciences, Gonabad, Iran
[3]Laboratory technical manager, Shahid Hasheminejad Hospital, Mashhad University of Medical Sciences, Mashhad, Iran
[4]Internist specialist, Department of Internal Medicine, Faculty of Medicine, Gonabad University of Medical Sciences, Gonabad, Iran
[5]Department of Physiology, Faculty of Medicine, Gonabad University of Medical Sciences, Gonabad, Iran

ARTICLE INFO

Article History:
Received: 12.08.2018
Accepted: 28.10.2018

Keywords:
Idiopathic thrombocytopenic purpura
Giant platelet
Macrothrombocytopenia
Factitious thrombocytopenia

**Corresponding author:*
Hamid Reza Niazkar,
Medical Student, Student Research Committee, Gonabad University of Medical Sciences, Zip Code: 96917-93718, Gonabad, Iran
Email: hrn185@hotmail.com;
ORCID: 0000-0002-6143-9979

ABSTRACT

Idiopathic thrombocytopenia purpura (ITP) is an autoimmune disorder characterized by isolated thrombocytopenia and mucocutaneous bleeding. The former has a primary role in the diagnosis and treatment of ITP. One of the leading causes of miscounted platelets in patients who suffer from ITP is giant platelets which may indicate factitiously a severe false thrombocytopenia. Here, a case of macrothrombocytopenia is presented in an ITP patient. Giant platelets of this patient not only resulted in miscounting platelets but also falsely increased reading of RBC counts. By counting platelets through peripheral blood smear and hemocytometer, the patient was saved from an unnecessary splenectomy.

Please cite this article as: Ghorbani M, Niazkar HR, Ejtehadi MM, Mahmoudi R, Abbasnezhad AA. Can Macrothrombocytopenia Mislead the Treatment of Idiopathic Thrombocytopenia Purpura?. IJBC 2018; 10(4): 133-135.

Introduction

ITP is an autoimmune disorder characterized by low platelet count and mucocutaneous bleeding.[1] The diagnosis of ITP relies on isolated thrombocytopenia, lack of other hematological abnormalities, normal physical examination except mucocutaneous bleeding consistent with thrombocytopenia and exclusion of other causes of thrombocytopenia.[2] The estimated incidence of ITP is 100 cases per 1 million per year while around half of these cases occur in children. In adults, the course of ITP is generally chronic and the onset is often insidious where women are approximately affected twice as men are.[3] The platelet count is determining in treatment of ITP.[4] One of the major causes of false thrombocytopenia is giant platelets.[5] Here, a case of macrothrombocytopenia in an ITP patient is presented.

Case Report

A 22-year-old woman was admitted with a previous diagnosis of ITP. She had been taking prednisone 1 mg/kg/day for four weeks for persistent symptomatic, severe thrombocytopenia (platelet <10,000/microliter). After four weeks of treatment, she received methylprednisolone (30 mg/kg intravenously) for 3 days. Since the patient did not respond appropriately to these therapies, she received intravenous immunoglobulin and anti-D (IVIG 1g/kg for two days and Anti-D 75 mg/kg given once). Due to failure of platelet response, she was considered as a candidate for splenectomy. Hematological workup before the surgery showed thrombocytopenia along with erythrocytosis with

[Downloaded from ijbc.ir on 2026-11-28]

hypochromic microcytic red blood cells. The peripheral blood slide of the patient showed many giant platelets (Figure 1). After evaluating the platelet count through peripheral blood slide and hemocytometer, true platelet counts were found to be higher, so that splenectomy was not indicated anymore. We also checked serum iron, TIBC, serum ferritin and hemoglobin electrophoresis which all were within normal range. We shall declare that informed consents was obtained from the patient for the publication of their information and imaging.

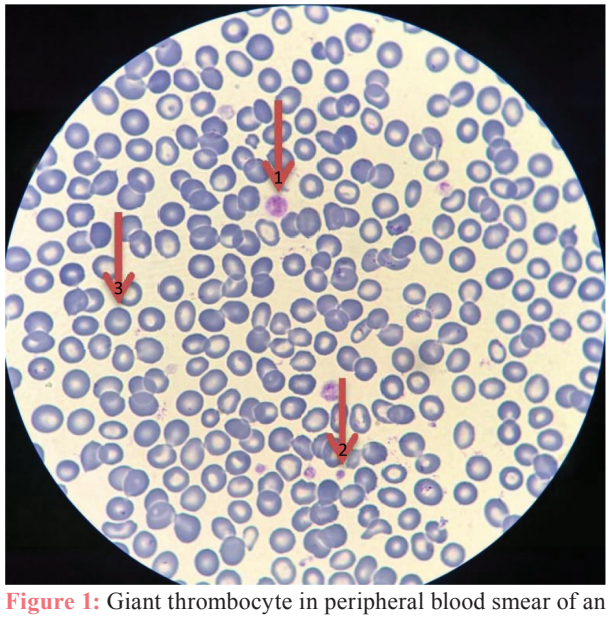

Figure 1: Giant thrombocyte in peripheral blood smear of an ITP patient
(Arrow 1 indicates Giant thrombocyte , aroow 2 indicates normal thrombocyte and arrow 3 indicates normocytic normochromic RBC)

Discussion

RBC or white blood cell microparticles and macrothrombocytes can cause false results in hematology cell counting devices.[5] "Giant platelet" also known as "macrothrombocyte", is a term used to describe platelets that are abnormally large, i.e., as large as a normal RBC.[6] Giant platelets are observed in conditions of rapid turnover such as ITP and represent increased platelet production.[4] Thrombocytopenia accompanied by giant platelets are called "macrothrombocytopenia". Large platelets are particularly common in patients with ITP due to destructive mechanisms and associated regenerative release of giant immature forms.[7] Macrothrombocytopenia may be underdiagnosed because of its similar presentation to ITP. In both conditions, thrombocytopenia with large to giant platelets is observed.[8]

Since platelets and RBCs are counted simultaneously in cell counter devices, platelets may be counted as RBCs in conditions associated with large or giant Platelets. If giant platelets have a volume exceeding the upper limit of the analytical range, they will be counted as RBCs instead of platelets. As a result, a high RBC count would be recorded accompanying with decreased MCV and MCH with or whitout anemia.[9] This condition is similar to those with thalassemia syndromes; thus patients may be subjected to unneccessry expensive laboratory tests such as hemoglobin electrophoresis or molecular tests specially for diagnosing alpha thalassemia.

Microscopic examination of peripheral blood slides can reveal giant platelets; hence the diagnosis may be missed if the peripheral blood slide is not examined carefully.

Macrothrombocytopenia can be seen in other conditions such as May-Hegglin anomaly or Bernard-Soulier syndrome.[9] Giant platelets in these conditions may cause inaccurate platelet counting which result in wrong intervention. The presence of macrothrombocytopenia in patients with May-Hegglin anomaly and Bernard-Soulier may result in misdiagnosis of chronic ITP. According to Noris et al, four out of 15 patients with May-Hegglin anomaly had been misdiagnosed as severe ITP and had received prednisone for a long time. Moreover, three of them had already undergone splenectomy without any improvement in platelet counts or bleeding tendency.[9]

The presence of giant platelets in peripheral blood of ITP patients might underestimate the true platelet count that can mislead the treatment plan of the patients. In addition, giant platelets could be counted as RBCs, so will mimic hypochromic microcytic RBCs.

Conclusion

In thrombocytopenic patients, platelets counts should be confirmed by examining peripheral blood smear and conditions such as giant platelets and other causes of pseudothrombocytopenia should be taken into account. Inaccurate platelet counting due to the presence of giant platelets may raise the suspicion of a resistant ITP.

Conflict of Interest: None declared.

References

1. Won YW, Moon W, Yun YS, Oh HS, Choi JH, Lee YY, et al., Clinical aspects of pregnancy and delivery in patients with chronic idiopathic thrombocytopenic purpura (ITP). Korean J Intern Med. 2005. 20(2): 129-34. doi: 10.3904/kjim.2005.20.2.129. PubMed PMID: 16134767. PubMed Central PMCID: PMC3891381.
2. Sobota AE, Neufeld EJ. Recognition and management of immune thrombocytopenic purpura and autoimmune hemolytic anemia in the emergency department. Clin Pediatr Emerg Med. 2011. 12(3): 245-52. doi: 10.1016/j.cpem.2011.07.004
3. Cines DB, Blanchette VS. Immune thrombocytopenic purpura. N Engl J Med. 2002. 346(13): 995-1008. doi: 10.1056/NEJMra010501. PubMed PMID: 11919310.
4. Diquattro M, Gagliano F, Calabrò GM, Tommasi M, Scott CS, Mancuso G, et al. Relationships between platelet counts, platelet volumes and reticulated platelets in patients with ITP: evidence for significant platelet count inaccuracies with conventional instrument methods. Int J Lab Hematol. 2009;31(2):199-206. doi: 10.1111/j.1751-553X.2007.01025.x. PubMed PMID: 18190589.
5. Harrison P, Briggs C, Machin S. Advances in platelet counting. Hematology, 2001. 5(6): 421-7. doi: 10.1080/10245332.2001.11746538. PubMed PMID:

[Downloaded from ijbc.ir on 2026-11-28]

27419344.
6. Sahud MA. Platelet disorders: a review of disturbances in adhesion, aggregation, and release reaction. Calif Med. 1972;116(1):21-31. PubMed PMID: 4257630. PubMed Central PMCID: PMC1518141.
7. Zandecki M, Genevieve F, Gerard J, Godon A. Spurious counts and spurious results on haematology analysers: a review. Part I: platelets. Int J Lab Hematol. 2007. 29(1): 4-20. doi: 10.1111/j.1365-2257.2006.00870.x. PubMed PMID: 17224004.
8. Kakkar N, John MJ, Mathew A. Macrothrombocytopenia in north India: role of automated platelet data in the detection of an under diagnosed entity. Indian J Hematol Blood Transfus. 2015; 31(1):61-7. doi: 10.1007/s12288-014-0367-3. PubMed PMID: 25548447. PubMed Central PMCID: PMC4275526.
9. Noris P, Spedini P, Belletti S, Magrini U, Balduini CL. Thrombocytopenia, giant platelets, and leukocyte inclusion bodies (May-Hegglin anomaly): clinical and laboratory findings. Am J Med. 1998;104(4):355-60. doi: 10.1016/S0002-9343(98)00062-X. PubMed PMID: 9576409.

[Downloaded from ijbc.ir on 2026-11-28]