IJBC 2018; 10(4): 130-132

Iranian Journal of Blood & Cancer

Journal Home Page: www.ijbc.ir



CASE REPORT

Chylous pleural effusion: A rare presentation of Non-Hodgkin-Lymphoma

M T. Sugeeth[1], MD, DNB, DM; Geetha Narayanan[2], MD, DNB, DM; Lali V. Soman[3], MBBS

[1]Senior Resident, Department of Medical Oncology, Regional Cancer Centre, Trivandrum 695011, India
[2]Professor & Head, Department of Medical Oncology, Regional Cancer Centre, Trivandrum 695011, India
[3]Resident Medical Officer, Regional Cancer Centre, Trivandrum 695011, India

ARTICLE INFO

Article History:
Received: 03.08.2018
Accepted: 12.10.2018

Keywords:
Chylous pleural effusion
Non Hodgkin lymphoma
First presentation
Flowcytometry

**Corresponding author:*
Geetha Narayanan, MD, DNB, DM
Professor & Head, Department of Medical Oncology
Regional Cancer Centre, Trivandrum 695011, India.
Tel: +91 944 7500920
Fax: +91 471 2443498
Email: geenarayanan@yahoo.com

ABSTRACT

Chylous pleural effusion is characterized by milky-appearing fluid with elevated triglyceride content and presence of chylomicrons in the pleural space. Even though patients with lymphoma sometimes present with malignant pleural effusion, chylous effusion is rarely encountered as a presenting feature in such patients. We present a 47-year-old woman diagnosed as follicular lymphoma who presented with chylothorax. Complete response to combination chemotherapy with rituximab, cyclophosphamide, doxorubicin, vincristine and prednisolone was achieved. The patient is asymptomatic, in remission at 18 months of follow up.

Please cite this article as: Sugeeth MT, Narayanan G, Soman LV. Chylous pleural effusion: A rare presentation of Non-Hodgkin- Lymphoma. IJBC 2018; 10(4): 130-132.

Introduction

The presence of chyle in the pleural space is defined as chylothorax. Chylothorax is a rare cause of a pleural effusion and progressive respiratory failure. Malignancy is reported as the leading cause of non-traumatic chylothorax. Non Hodgkin's lymphoma (NHL), chronic lymphocytic leukemia, and metastatic cancers are common malignancies associated with chylothorax.[1] While effusions in general are common in lymphoma, chylous effusions are rare. We report a 47-year-old woman with follicular lymphoma whose initial presentation was chylous pleural effusion.

Case Report

A 47-year-old woman presented with cough, gradually worsening dyspnea on exertion and pedal edema of 4 months duration. She also gave a history of loss of appetite and had lost more than 8 kilograms over the last 4 months. There was no history of fever or any gastrointestinal symptoms. On physical examination, her general condition was poor. She had generalized pitting edema over her both lower extremities. Abdominal examination showed a nodular mass filling the hypogastric and umbilical regions. Initial imaging was performed in which chest X-ray showed massive left sided pleural effusion (Figure 1). Computed tomography scan showed multiple enlarged cervical, axillary, para aortic and mesenteric lymph nodes. Initial laboratory tests including CBC and LDH were within normal range. Echocardiography showed normal cardiac function with

[Downloaded from ijbc.ir on 2026-11-28]

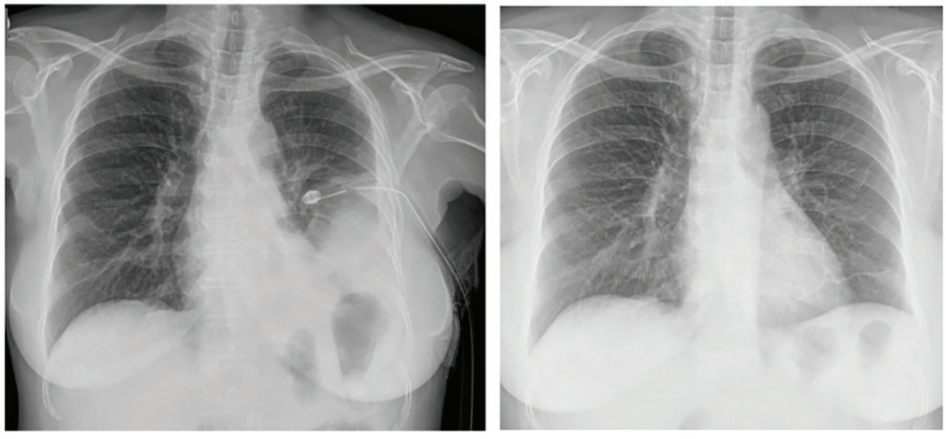

a b

Figure 1: A) Chest X-ray showing left sided pleural effusion with intercostal draining tube in the left lower zone. B) Chest X-ray showing resolution of pleural effusion after first cycle of chemotherapy.

ejection fraction of 67%. Peripheral blood smear was suggestive of a lymphoproliferative disorder with 40% atypical lymphocytes. On flowcytometry, these atypical lymphocytes were positive for CD10, CD19, CD20, CD23, CD 45 and lambda antigen and negative for CD34 and CD5 in favour of B cell clonality. Bone marrow study was also suggestive of lymphoproliferative disorder. Para aortic lymph node biopsy was suggestive of CD 20+ B cell lymphoma. She was diagnosed as follicular lymphoma in leukemic phase. Pleural fluid was typically chylous with a triglyceride level of 256 mg/dl and cholesterol 50 mg/dl. Pleural fluid total WBC count was 5600/mm, 87% constituted by lymphocytes. Pleural fluid had a protein content of 2gm/dl and pleural fluid LDH was 464 IU/L. Analysis of pleural effusion was positive for malignant cells. She was staged as ann arbor stage IVB and had an International Prognostic Index score of 2/5.[2] She received combination chemotherapy with Rituximab, Cyclophosphamide, Doxorubicin, Vincristine and Prednisolone (R-CHOP) for six cycles and achieved complete remission. Intercostal draining tube was removed after first cycle chemotherapy. She continues to be in complete remission after 18 months.

Discussion

Serous effusions are common among patients with malignant lymphoma. The most common site of effusion is pleural, seen in 20–30% of the cases followed by pericardium and peritoneum.[3] The presence of milky-appearing lymph fluid or chyle in the pleural space defines chylothorax and it may be the first manifestation in patients with non-Hodgkin lymphoma.[4] More than 50% of the cases of chylothorax are associated with malignancy, among which, the majority are due to lymphoma.[5] Bilateral presentation of chylothorax is reported to be very rare. The mechanisms by which chylothorax is associated with lymphomas could be explained by neoplastic pleural infiltration and obstruction of lymphatic duct by enlarged lymph nodes at the mediastinal level.

Patients with chylothorax suffer from malnutrition and immunodeficiency due to loss of fat and lymphocytes into the pleural space.[6] The finding of a pleural fluid with triglyceride >1.24 mmol/l (110 mg/dl) and cholesterol <5.18 mmol/l (200 mg/dl) is diagnostic of chylothorax.[7]

A 78-year-old woman with chylous peritoneal and pleural effusion secondary to follicular lymphoma is reported who was treated with rituximab based on flowcytometric analysis of the pleural fluid and attained complete remission.[8] An 18-year-old girl with NHL and chylous pleural effusion and ascites has also reported.[9] Chylous effusion usually resolves with treatment of the underlying lymphoma. Conservative measures like dietary changes with protein-rich, low-lipid foods can reduce chyle flow. Medium chain triglycerides are preferably consumed since they are directly absorbed and transported as free chain fatty acids and glycerol in the portal vein. In refractory cases, surgical procedure in order to ligate the thoracic duct or generate a pleuroperitoneal shunt is scheduled.[10]

Conclusion

Chylothorax is a rare cause of pleural effusion that results from thoracic duct damage with chyle leakage from the lymphatic system into the pleural space. Malignancy is the leading cause of non-traumatic chylothorax. While effusions in general are common in lymphoma, chylous effusions are rare with no strict guidelines concerning its treatment. Chylous pleural effusions secondary to lymphoma usually resolve with combination chemotherapy for NHL.

Conflict of Interest: None declared.

References

1. Doerr CH, Allen MS, Nichols FC, Ryu JH. Etiology of chylothorax in 203 patients. Mayo Clin Proc. 2005; 80(7):867-70. doi: 10.4065/80.7.867. PubMed PMID: 16007891.
2. van de Schans SA, Steyerberg EW, Nijziel MR, Creemers GJ, Janssen-Heijnen ML, van Spronsen DJ.. Validation, revision and extension of the Follicular Lymphoma International Prognostic Index (FLIPI) in a population-based setting. Annals of Oncology. 2009; 20(10):1697–702. doi:10.1093/annonc/mdp053. PubMed PMID: 19549712.
3. Das DK. Serous effusions in malignant lymphomas:

[Downloaded from ijbc.ir on 2026-11-28]

a review. Diagn Cytopathol. 2006; 34(5):335–47. doi: 10.1002/dc.20432. PubMed PMID: 16604559.
4. Anton E. Chylothorax in hematologic malignancies. Chest. 2005; 127(5): 1866-7. PubMed PMID: 15888876.
5. Cheson BD. Staging and evaluation of the patient with lymphoma. Hematol Oncol Clin North Am. 2008; 22(5): 825-37. doi: 10.1016/j.hoc.2008.07.015. PubMed PMID: 18954739.
6. Janjetovic S, Janning M, Daukeva L, Bokemeyer C, and Fiedler W. Chylothorax in a patient with hodgkin's lymphoma: a case report and review of the literature. Tumori. 2013; 99(3):96–99. doi: 10.1700/1334.14813. PubMed PMID: 24158090.
7. Staats BA, Ellefson RD, Budahn LL, Dines DE, Prakash UB, Offord K. The lipoprotein profile of chylous and nonchylous pleural effusions. Mayo Clin Proc. 1980; 55(11):700-4. PubMed PMID: 7442324.
8. Etonyeaku AC, Akinsanya OO, Ariyibi O, and Aiyeyemi JJ. Chylothorax from bilateral primary Burkitt's lymphoma of the ovaries: a case report. Case Rep Obstet Gynecol. 2012; 2012:635121. doi: 10.1155/2012/635121. PubMed PMID: 22852103. PubMed Central PMCID: PMC3407614.
9. Jagosky M, Taylor B, and Taylor SP. A Case of chyloperitoneum secondary to follicular lymphoma and a review of prognostic implications. se Rep Hematol. 2016;2016:4625819. doi: 10.1155/2016/4625819. PubMed PMID: 27429812. PubMed Central PMCID: PMC4939180.
10. Evans J, Clark MF, Mincher L, and Varney VA. Chylous effusions complicating lymphoma: a serious event with octreotide as a treatment option. Hematol Oncol. 2003; 21(2):77-81. PubMed PMID: 12802812. doi: 10.1002/hon.710.

[Downloaded from ijbc.ir on 2026-11-28]