

## PHOTO CLINIC

# Pancreatic Metastasis of Alveolar Rhabdomyosarcoma Presenting as Acute Pancreatitis

Parastou Molai Tavana, Samin Alavi\*

Pediatric Congenital Hematologic Disorders Research Center, Shahid Beheshti University of Medical Sciences, Tehran, Iran

## ARTICLE INFO

### Article History:

Received: 02.02.2018

Accepted: 25.03.2018

### \*Corresponding author:

Samin Alavi, MD;

Address: Pediatric Congenital Hematologic Disorders Research Center, Shahid Beheshti University of Medical Sciences, Tehran, Iran

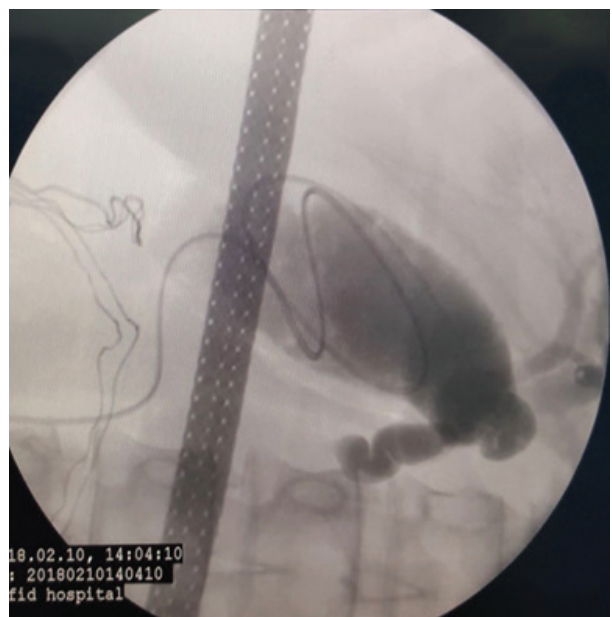
Email: [saminalavi@hotmail.com](mailto:saminalavi@hotmail.com)

Please cite this article as: Molai Tavana P, Alavi S. Pancreatic Metastasis of Alveolar Rhabdomyosarcoma Presenting as Acute Pancreatitis. IJBC 2018; 10(2): 66-67.

A 14-year-old girl, known case of rhabdomyosarcoma (RMS) of head and neck (zygomatic region accompanied by cervical lymphadenopathies) was admitted with severe epigastric unrelenting pain. She was receiving chemotherapy for intermediate-risk RMS with standard VAC (vincristine, dactinomycin, and cyclophosphamide alternating with vincristine, topotecan, and cyclophosphamide (VAC/VTC) for the last eight months. On admission, she was mildly icteric and afebrile. Ultrasound examination at that time showed minimally dilated intra and extra hepatic and common bile ducts. Head and neck of the pancreas had increased size with anteroposterior diameter of about 26.4 mm and minimal free fluid was observed anterior to the pancreas. She was diagnosed with “acute pancreatitis” due to associated signs and symptoms and increased levels of amylase and lipase to more than three times.

Due to the persistence of increased pancreatic enzyme levels, magnetic resonance cholangiopancreatography was performed for the patient which revealed diffuse enlargement of the pancreas with heterogeneous signal intensity suggestive of diffuse pancreatitis or infiltrative process along with obstruction at the distal end of the common bile duct (Figure 1).

The patient underwent laparotomy which a tumoral mass in the head of the pancreas was detected. Cholecystectomy and pancreatic biopsy was achieved



**Figure 1:** Diffuse enlargement of the pancreas with heterogeneous signal intensity suggestive of diffuse pancreatitis or infiltrative process along with obstruction at the distal end of the common bile duct

for the patient. Histopathology was reported as metastatic alveolar RMS.

RMS represents the most common soft tissue sarcoma in

children, with an incidence of 4.3 new cases per million children and adolescents younger than 20 years. Alveolar RMS is associated with an aggressive course and a poor outcome. Metastatic disease is thought to involve most commonly the lungs, bone, bone marrow and lymph nodes.<sup>1</sup> RMSs have a propensity to involve unusual sites such as the breast, testes and subcutaneous tissues.<sup>2</sup> previous autopsy studies reported an incidence of pancreatic metastases in 67% of patients who died from metastatic alveolar RMS.<sup>2</sup> A series of eight cases of metastatic involvement of the pancreas in patients with alveolar RMS out of 71 cases has been reported from three major pediatric oncology centers in a period of eleven years. The duration between the diagnosis of the primary tumor and that of pancreatic metastases in patients with recurrent disease varied from 8 months to 6 years.<sup>1</sup> An 18-year-old boy with a history of right orbital alveolar RMS has also been reported who developed an episode of pancreatitis similar to our case. His CT-scan demonstrated acute pancreatitis with no mass lesion. Two months later, he developed abdominal pain and an MRI indicated a 6.4 cm mass in the body and tail of the pancreas. Endoscopic ultrasound guided FNA in that case confirmed the diagnosis of alveolar RMS metastatic to the pancreas.<sup>3</sup>

In a study from Utah University, records of the departments of Pathology of Utah School of Medicine and David Geffen School of Medicine were searched in an 8-year period for all samples biopsied from pancreatic masses through endoscopic ultrasound guided FNA. All cases with a diagnosis of metastatic disease were reviewed. A total of 17 metastasis to the pancreas were detected representing 0.73% of all cases. Among Primaries, there was one case of alveolar RMS.<sup>4</sup>

Acute pancreatitis (AP) is a rare manifestation of pancreatic cancer (PC). The relationship between pancreatitis and PC remains is not well defined. In a study

from China, 47 patients with PC who presented with AP has been reported.<sup>5</sup>

Our case was the first case of a teenage girl with head and neck alveolar RMS with pancreatic metastasis who was presented as acute pancreatitis. We suggest that in patients with RMS; in follow-up, pancreas and associated symptoms should be taken seriously in account.

**Conflict of Interest:** None declared.

## References

1. Jha P, Frolich AM, McCarville B, Navarro OM, Babyn P, Goldsby R, et al. Unusual association of alveolar rhabdomyosarcoma with pancreatic metastasis: emerging role of PET-CT in tumor staging. *Pediatr Radiol.* 2010;40(8):1380-6. doi: 10.1007/s00247-010-1572-3. PubMed PMID: 20180103; PubMed Central PMCID: PMC2895865.
2. Enzinger FM, Shiraki M. Alveolar rhabdomyosarcoma. An analysis of 110 cases. *Cancer.* 1969;24(1):18-31. PubMed PMID: 5790286.
3. Vanwoerkom RC, Bentz J, Chen L, Adler DG. EUS diagnosis of a primary pancreatic metastasis of alveolar rhabdomyosarcoma. *JOP.* 2009;10(6):683-5. PubMed PMID: 19890194.
4. Layfield LJ, Hirschowitz SL, Adler DG. Metastatic disease to the pancreas documented by endoscopic ultrasound guided fine-needle aspiration: a seven-year experience. *Diagn Cytopathol.* 2012;40(3):228-33. doi: 10.1002/dc.21564. PubMed PMID: 22334524.
5. Li S, Tian B. Acute pancreatitis in patients with pancreatic cancer: Timing of surgery and survival duration. *Medicine (Baltimore).* 2017;96(3):e5908. doi: 10.1097/MD.0000000000005908. PubMed PMID: 28099352; PubMed Central PMCID: PMC5279097.