IJBC 2018; 10(4): 136-137

Iranian Journal of Blood & Cancer

Journal Home Page: www.ijbc.ir

Photo Clinic

Mediterranean Stomatocytosis/macrothrombocytopenia in A 9-Year-Old Girl

Hossein Karami[1], Mohammad Naderisorki[1*], Nayersadat Tahami[2]

[1]Thalassemia Research Center, Department of Pediatrics Hematology and Oncology, Faculty of Medicine, Mazandaran University of Medical Sciences, Sari, Iran
[2]Department of Pediatrics, Faculty of Medicine, Mazandaran University of Medical Sciences, Sari, Iran

ARTICLE INFO

Article History:
Received: 16.02.2018
Accepted: 22.04.2018

**Corresponding author:*
Mohammad Naderisorki, Thalassemia Research Center, Department of Pediatrics Hematology and Oncology, Faculty of Medicine, Mazandaran University of Medical Sciences, P. O. Box: 48158-38477, Sari, Iran
Mobile: +989166042132
Tel/Fax: +98 11 33342331
Email: dr.naderisorki@gmail.com
ORCID: 0000-0001-8638-4057

Please cite this article as: Karami H, Naderisorki M, Tahami N. Mediterranean Stomatocytosis/macrothrombocytopenia in A 9-Year-Old Girl. IJBC 2018; 10(4): 136-137.

A 9-year-old girl was admitted with petechiae and mild pallor after an episode of upper respiratory tract infection. Physical examination detected aortic systolic murmur in addition to mild splenomegaly. Laboratory data showed Hb 8.9 g/dL, MCV 87 fl, MCH 27 pg, MCHC 31.7 g/dL, reticulocyte 4.3 %, platelet count 32 x10^9/L and MPV 21 fl. Peripheral blood smear from the patient was significant for stomatocytosis along with macrothrombocytopenia (Figure 1). The optical platelet count was employed which reported as 125×10^9/L. Bleeding time was also checked which was more than 10 minutes.

Stomatocytes are seen in small numbers in normal persons.[1] In conditions such as hereditary stomatocytosis, Rh null disease, acute alcoholism, marathon running and exposure upon some drugs (phenothiazine, vincristine), stomatocytosis is the predominant morphology of the RBCs.[2, 3]

According to the ethnicity of the patient and associated signs, "Mediterranean stomatocytosis" was suggested for the patient. As a result, lipid profile was checked which showed increased level of cholesterol.

Mediterranean stomatocytosis/macrothrombocytopenia is a unique form of stomatocytosis which presents with hemolytic anemia, macrothrombocytopenia and bleeding tendency.[4] Bleeding tendency and poor response to ristocetin in platelet aggregation studies is observed in Mediterranean stomatocytosis.[5] Macrothrombocytopenia, stomatocytosis and high cholesterol levels are manifestations of Phytosterolemia (sitosterolemia). This rare hereditary metabolic condition is caused by homozygous or compound heterozygous mutations in either ABCG5 or ABCG8 gene.[6] Unfortunately, we did not have the facilities to do the genetic studies for the patient. We advised the parents to avoid diets high in

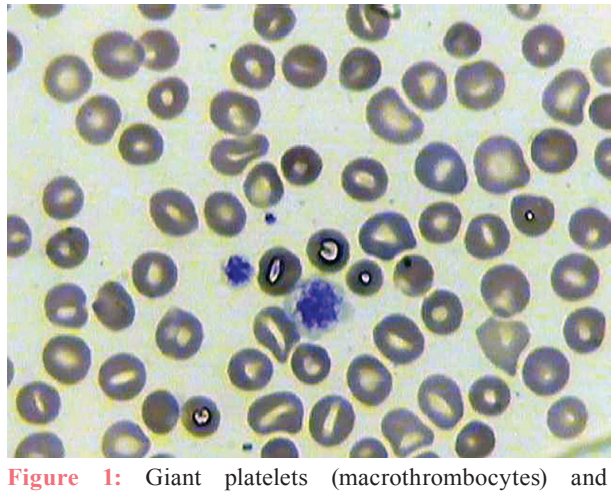

Figure 1: Giant platelets (macrothrombocytes) and stomatocytosis in peripheral blood smear.

[Downloaded from ijbc.ir on 2026-11-28]

vegetable oils, such as olive oil which could aggravate the hemolytic anemia.[5]

Conflict of Interest: None declared.

References

1. Wislöff F, Boman D. Acquired stomatocytosis in alcoholic liver disease. Scand J Haematol. 1979; 23(1):43–50. PubMed PMID: 493871.
2. Miller DR, Rickles FR, Lichtman MA, La Celle PL, Bates J, Weed RI. A new variant of hereditary hemolytic anemia with stomatocytosis and erythrocyte cation abnormality. Blood. 1971; 38(2):184-204. PubMed PMID: 5559828.
3. Ohsaka A, Kano Y, Sakamoto S, Kanzaki A, Hashimoto M, Yawata Y, et al. A transient hemolytic reaction and stomatocytosis following Vinca alkaloid administration. Nihon Ketsueki Gakkai Zasshi. 1989; 52(1):7-17. PubMed PMID: 2741652.
4. Walensky LD, Narla M, Lux SE. Disorders of the red blood cell membrane. In: Handin R, Lux S, Stossel T (eds). Blood: principles and practice of hematology. Philadelphia, PA: Lippincott Williams & Wilkins; 2003. pp.1709-858.
5. Rees DC, Iolascon A, Carella M, O'marcaigh AS, Kendra JR, Jowitt SN, et al. Stomatocytic haemolysis and macrothrombocytopenia (Mediterranean stomatocytosis/macrothrombocytopenia) is the haematological presentation of phytosterolaemia. Br J Haematol. 2005; 130(2):297-309.. doi: 10.1111/j.1365-2141.2005.05599.x. PubMed PMID: 16029460.
6. Berge KE, Tian H, Graf GA, Yu L, Grishin NV, Schultz J, et al. Accumulation of dietary cholesterol in sitosterolemia caused by mutations in adjacent ABC transporters. Science. 2000; 290(5497):1771-5.

[Downloaded from ijbc.ir on 2026-11-28]