



## CASE REPORT

# Maxillofacial Malignancy in Pregnancy; Report of Two Cases

Majid Sanatkhan<sup>1</sup>, Javid Rasekhi<sup>2</sup>, Zohreh Dalirsani<sup>1\*</sup>, Narges Ghazi<sup>3</sup>

<sup>1</sup>Associate Professor of Oral and Maxillofacial Medicine, Oral and Maxillofacial Diseases Research Center, Mashhad University of Medical Sciences, Mashhad, Iran

<sup>2</sup>Assistant professor of oral and maxillofacial medicine, Bojnurd School of Dentistry, North Khorasan University of Medical Sciences, Bojnurd, Iran

<sup>3</sup>Assistant Professor of Oral and Maxillofacial Pathology, Oral and Maxillofacial Diseases Research Center, Mashhad University of Medical Sciences, Mashhad, Iran

## ARTICLE INFO

### Article History:

Received: 23.09.2019

Accepted: 20.11.2019

### Keywords:

Pregnancy

Maxillofacial neoplasms

Malignancy

Osteosarcoma

Squamous cell carcinoma

### \*Corresponding author:

Zohreh Dalirsani,

Department of Oral Medicine,

Mashhad Faculty of Dentistry, Vakil

abad Street, Mashhad, Khorasan

Razavi, Postal code: 91779-48959,

Mashhad, Iran

Tel: +98-9155002857

Fax: +98-51-38829500

Email: [zdalirsani@gmail.com](mailto:zdalirsani@gmail.com)

## ABSTRACT

Pregnancy is a physiological period in a woman's life. It is well known that some pathological changes have been reported to be more common in pregnancy than other stages of the life. It seems that primary tumors have a tendency to progress more rapidly in pregnancy due to hormonal alterations or increased expression of some growth factors. The exact relationship between pregnancy and malignancy has not been established. There are different kinds of malignancies occurring during pregnancy. In this manuscript, we report malignant tumors of the jaws in two pregnant patients. Histopathological diagnosis was compatible with chondroblastic variant of osteosarcoma and squamous cell carcinoma, respectively.

The clinical practitioners and dentists must be able to differentiate between the inflammatory and neoplastic conditions, especially during pregnancy to avoid unnecessary treatments which could lead to harmful effects on pregnant woman or her fetus.

Please cite this article as: Sanatkhan M, Rasekhi J, Dalirsani Z, Ghazi N. Maxillofacial Malignancy in Pregnancy; Report of Two Cases. IJBC 2019; 11(4): 143-147.

## Introduction

Pregnancy-associated cancers (PAC) are expected to occur in about 1 in 1000 pregnancies.<sup>1</sup> PACs are defined as cancers diagnosed during pregnancy or during 1-2 years after delivery.<sup>2</sup> PAC has a low incidence; however, recently this rare association is likely to become more common due to delays in pregnancy, especially in developing countries.<sup>3,4</sup> To the best of our knowledge, the studies have not revealed any direct relationship between pregnancy and development of cancer.

The malignancies most commonly diagnosed in the pregnant women are breast, hematological and dermatological malignancies.<sup>3</sup> Although oral cancer is not common in the pregnant women, changes in the epidemiology of oral and maxillofacial cancers, as well as, an increase in the number of women to delay childbearing

to an older age, could suggest that the risk is increasing.<sup>4</sup> Here we report two pregnant women diagnosed with malignancies of the jaws, each with a different pathology.

## Case Presentations

### Case 1

A 20-year-old woman in the third month of pregnancy was referred with complaint of a painful slowly-growing swelling of the right posterior mandible for the last two months. She was initially visited by a dentist and had received antibiotics for possible dental abscess, but neither pain nor swelling was improved. Then, she was referred to the department of oral and maxillofacial medicine, Mashhad Dental School. On physical examination, a lobular swelling measuring approximately 2×3 cm on the lingual aspect of the alveolar ridge on the right side of the mandible

adjacent to the first and second molars was found. The lesion was extended to the depth of the lingual vestibule to the premolar region and also posteriorly to the retromolar area, where it turned around the second molar (figure 1A). The third molar was also impacted. It seemed that the lesion had pushed the second molar buccally. The consistency of the lesion was bony hard in all areas except for the distal part in the retromolar area, where it was felt to be quite firm. The surface of the lesion was smooth and intact with normal color. There was not any other pathological lesion in other parts of the mouth. Based on the clinical findings, a provisional diagnosis of intraosseous malignancy such as osteosarcoma was established.

A panoramic X-ray with precautions regarding the pregnancy was performed which showed a radiolucent lesion involving the posterior body of the mandible extending from the distal of the second premolar to the region of the impacted third molar. There was a band-like widening of periodontal ligament space in the mesial and distal roots of the lower right first molar. An interdental radiolucency with ill-defined borders between the first and second molars destroying the crest of the alveolar bone was also noticeable. The impacted third molar tooth pushing into the ramus of the mandible; a large follicular space was also visible (figure 1B).

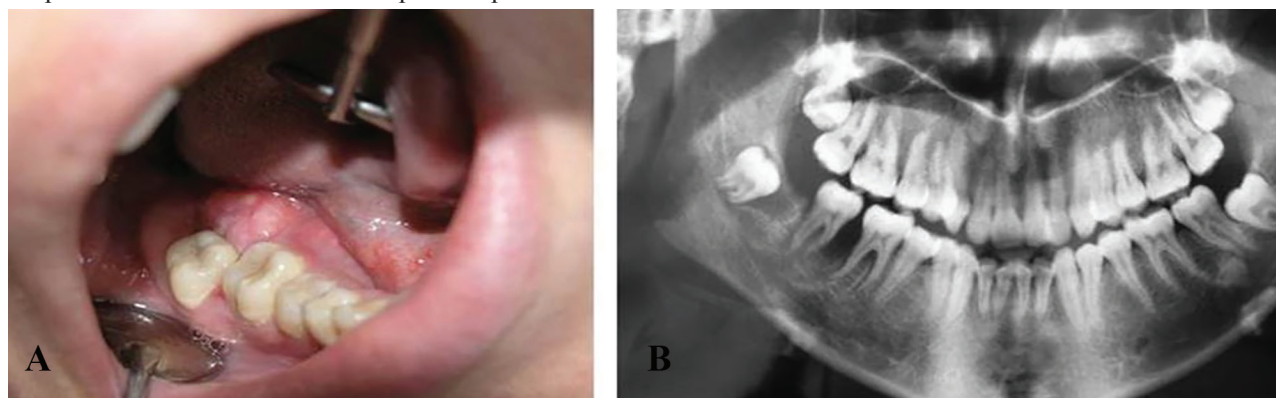
Histopathological examination following the incisional biopsy showed a highly cellular neoplasm of spindle-shaped cells with marked cellular pleomorphism and

hyperchromatic nuclei along with typical mitotic figures. Areas of osteoid matrix and immature bone were also identified. In addition, large areas of neoplastic cartilage with varying degrees of cellularity were present. Pleomorphic round to oval cells with dispersed chromatin enclosed in lacunae were seen in haphazardly arranged sheets. The histopathological features were suggestive of chondroblastic variant of osteosarcoma (figure 2A, 2B). Surgical resection was scheduled for the patient. Due to lack of acquisition of safe margins of 2 cm, a second surgery was proceeded, which was successful. A solitary enlarged lymph node in the submandibular region was also removed. The patient was referred to an oncologist for further treatment. The pregnancy was suggested to be terminated. The patient completed the course of the treatment and was free of tumor until this report.

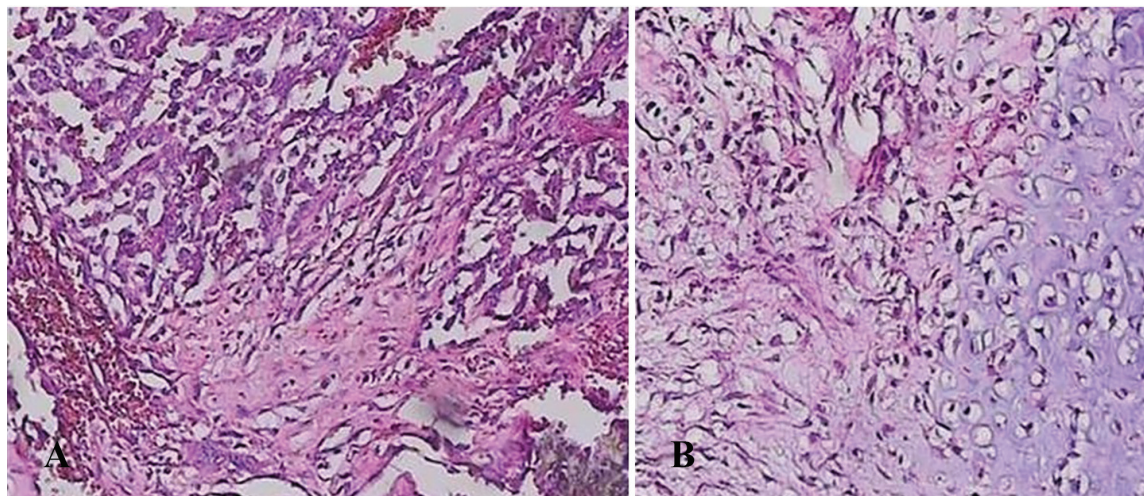
### Case 2

A 24-year-old woman in the fourth month of pregnancy was referred for a painful swelling of right upper jaw since 3 months ago, right-sided otalgia and spontaneous episodes of epistaxis. She had received penicillin G, once daily for 3 days and oral antibiotics for ten days. Due to persistence of the swelling, she was referred to the department of oral and maxillofacial medicine, Mashhad Dental School.

Physical examination was remarkable for a swelling in the buccal and palatal aspect of right posterior maxilla from the lateral incisor to the second molar tooth.

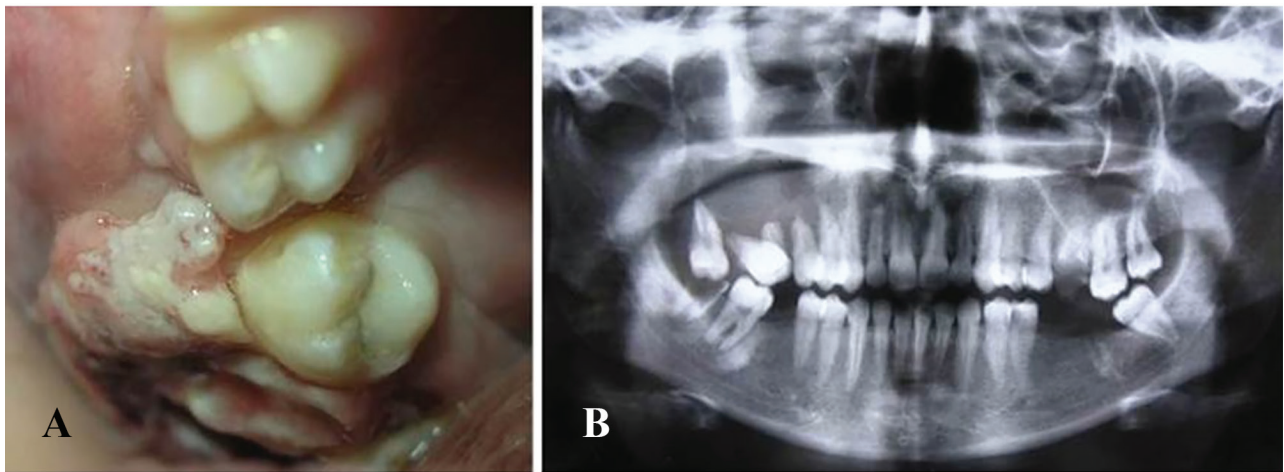


**Figure 1:** A) A lobular swelling measuring approximately 2×3 cm on the lingual aspect of alveolar ridge on the right side of mandible adjacent to the first and second molars. B) The impacted third molar with a large follicular space pushing into the ramus of the mandible by its follicle.

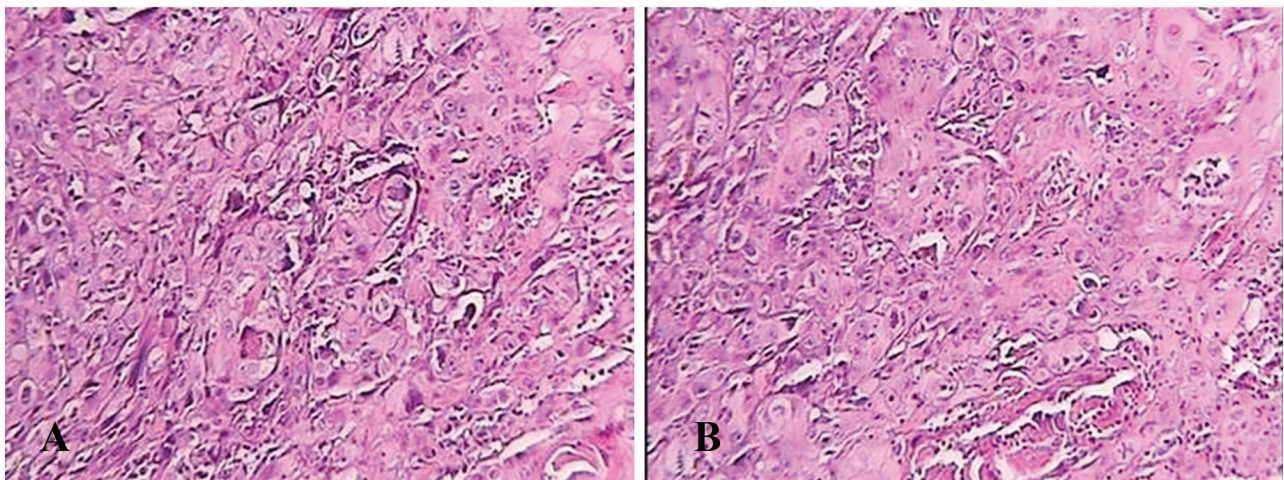


**Figure 2:** A, B) A highly cellular neoplasm with spindle-shaped cells, hyperchromatic nuclei and marked cellular atypism.





**Figure 3:** A) A swelling in the buccal and palatal aspect of right posterior maxilla from the lateral incisor to the second molar. The surface of the lesion was smooth in the most areas but keratotic and granular in some regions. B) ill-defined borders involving the right upper region of the maxilla extending from the canine tooth to the tuberosity of maxilla. A view of “hanging in air” could be observed. The premolars and the second molar showed root resorption.



**Figure 4:** A, B) A malignant neoplasm of stratified squamous epithelial cells as sheets and islands of cells, invading the connective tissue. Formation of keratin pearls was not prominent with diffuse mononuclear inflammatory infiltration in the fibrous connective tissue stroma.

The swelling was fixed to the underlying tissues and firm in consistency in the buccal region of the premolars. The surface of the lesion was smooth in the most areas but keratotic and granular in the some regions. The color of the lesion was red and purple in most areas (figure 3A). Small lymph nodes were palpated in the right submandibular area. A panoramic X-ray showed a radiolucent lesion with ill-defined borders involving the right upper region of the maxilla extending from the canine tooth to the tuberosity of maxilla. The teeth adjacent to the lesion seemed to have lost the bony support and a view of “hanging in air” could be observed. The premolars and the second molar showed root resorption (figure 3B). Histopathological examination of the lesion revealed a malignant neoplasm of stratified squamous epithelial cells as sheets and islands invading to the connective tissue. Marked hyperchromatism and extremely atypical mitoses were observed. Formation of keratin pearls was not a prominent histological feature. Diffuse mononuclear inflammatory infiltration was observed in the stroma of fibrous connective tissue (figure 4A, 4B). A diagnosis of oral squamous cell carcinoma (SCC) grade III was made. Regarding the extent of the

tumor and involvement of the right maxillary sinus, the patient was referred to an ENT specialist to perform the surgical procedure. The patient was lost to follow-up after referring to the oncologist. Informed consent was obtained from both patients to report the cases.

### Discussion

Cancer is the second cause of death of women in the reproductive age. Occurrence of cancer during pregnancy is a rare event<sup>2</sup>. In a case report, late recurrence of Ewing sarcoma in two pregnant women was reported, although immunohistochemistry did not detect any estrogen and progesterone receptors on tumor tissue.<sup>5</sup> In an international collaborative study, patients with invasive cancer during pregnancy between 1998 and 2008 were identified. Of 215 patients, five (2.3%) had a pregnancy, which terminated in abortion and miscarriage. The most frequently encountered cancers were breast cancer (46%), hematological malignancies (18%), and dermatological malignancies (10%).<sup>3</sup> A 10-year experience in Shahid Sadoughi Hospital, Yazd, Iran, showed 17 pregnant women with cancer, which included breast cancer in six,

acute myeloblastic leukemia in three, cervical cancer in three and five patients with ovarian cancer, chronic myelogenous leukemia, lymphoma, papillary carcinoma of thyroid and pseudopapillary carcinoma of the pancreas. The pregnant patients in that study had a mean age of 30.6 years.<sup>6</sup> A review of 10 years of experience from Kurdistan province, Iran showed that among 25 pregnant patients with any type of malignancy, 10 patients had gynecologic cancers and 15 had non-gynecologic cancer. The ovarian cancer was the most common malignancy and other cancers were breast cancer, Hodgkin's disease, glioblastoma, gastric cancer, Burkitt's lymphoma, malignant neuroblastoma, liposarcoma, astrocytoma and lung carcinoma.<sup>7</sup>

Our patients were affected by maxillofacial osteosarcoma and squamous cell carcinoma, which both are very rare tumors during pregnancy. A narrative review in the English literature has reported 137 cases of bone or soft tissue sarcomas throughout pregnancy between 1963-2014. Thirty-eight pregnant mothers were diagnosed with osteosarcoma, Ewing's sarcoma or chondrosarcoma.<sup>8</sup>

The first craniofacial osteosarcoma in pregnancy was reported in 1963 which was located in the superior part of the ramus of the mandible bone.<sup>9</sup> There are other reports of osteosarcoma and its management in pregnancy in the literature.<sup>10</sup>

Osteosarcoma is the most common primary malignant tumor of the bone. This tumor is predominantly originated in the long bones of the appendicular skeleton and less than 10% of osteosarcomas occur in the head and neck. It accounts for 1% of all head and neck malignancies. The most common site of involvement for craniofacial osteosarcoma is the jaws.<sup>11</sup>

Osteosarcoma of the jaw bones occurs about a decade later in the life comparing to those in long bones with the peak prevalence in the third and fourth decades of life. Osteosarcoma of jaw bones have some different properties such as longer survival rates; however, occasional metastases and local recurrences of these tumors are associated with high morbidity and mortality.<sup>12</sup> The 5-year survival rate is reported to be 10- 85% due to lower rate of metastasis.<sup>13</sup>

Swelling, pain and paresthesia are common signs and symptoms of craniofacial osteosarcoma. Surgical resection is the main therapeutic approach to treating osteosarcoma and can be adequate for many patients; however, some authors recommend the use of adjuvant chemotherapy as well.<sup>11</sup> There is also a report of a case of epithelioid osteosarcoma manifesting as a mass in the maxilla of a 22-year-old female, which was discovered in the eighth month of pregnancy.<sup>14</sup>

Histopathologically, osteosarcoma is categorized into three types of osteoblastic, fibroblastic, and chondroblastic; the latter is the least invasive type, with the least risk of metastasis. In addition, the most common type of osteosarcoma in jaw bones is chondroblastic osteosarcoma.<sup>15, 16</sup>

There are also reports of different kinds of carcinoma developing in the pregnancy. Two cases of SCC of tongue were found in the fourth and sixth month of gestation.<sup>4,17</sup>

Management of cancers during pregnancy is a medical challenge; however, even without treatment, serious threaten to the fetus is limited. In fact, some treatments can be harmful for the fetal growth process. Some pregnant women decide to terminate the pregnancy for beginning the treatment, whereas others defer treatment until delivery and some receive treatment along with pregnancy, some fetal demise may occur.<sup>18</sup> In a case of tongue carcinoma stage IV, which was found in the seventh month of pregnancy, chemotherapy was started before parturition. The treatment completed after cesarean section through concurrent radiotherapy and chemotherapy, neck dissection and hemiglossectomy.<sup>19</sup> Making decision about strategy of treatment is related to the type and prognosis of cancer and stage of the pregnancy.

## Conclusion

In conclusion, due to social and cultural factors, the age of childbearing in developing countries is increasing. Meanwhile, the incidence of oral and maxillofacial cancers in pregnant women is predicted to increase. Inflammatory signs of the maxillofacial tumors can be easily misdiagnosed as dental and periodontal infections, especially, in the pregnancy in which radiographic assessment is limited. It is very important for the dentists to be able to differentiate between the inflammatory and neoplastic conditions.

**Conflict of Interest:** None declared.

## References

1. Pavlidis NA. Coexistence of pregnancy and malignancy. *The oncologist* 2002;7(4):279-87.
2. Momen NC, Arendt LH, Ernst A, et al. Pregnancy-associated cancers and birth outcomes in children: a Danish and Swedish population-based register study. *BMJ open* 2018;8(12):e022946.
3. Van Calsteren K, Heyns L, De Smet F, et al. Cancer during pregnancy: an analysis of 215 patients emphasizing the obstetrical and the neonatal outcomes. *J Clin Oncol* 2010;28(4):683-9.
4. Murphy J, Berman DR, Edwards SP, et al. Squamous cell carcinoma of the tongue during pregnancy: a case report and review of the literature. *Journal of Oral and Maxillofacial Surgery* 2016;74(12):2557-66.
5. DuBois SG, Perez-Atayde AR, McLean TW, Grier HE. Late recurrence of ewing sarcoma during pregnancy: a report of 2 cases. *J Pediatr Hematol Oncol* 2008;30(9):716-8.
6. Karimi-Zarchi M, Ezabadi MG, Hekmatimoghaddam S, et al. Cancer in pregnancy: a 10-year experience in shahid sadoughi hospital, yazd, iran. *Int J Biomed Sci* 2013;9(3):168-73.
7. Eishi A, Rahimi E, Akhavan S, Shahgaibi S, Fariba F. Cancer during pregnancy: a review of 10 years of experience. *Pak J Biol Sci* 2012;15(7):341-6.
8. George Zarkavelis, Dimitrios Petrakis, George Fotopoulos, Sotirios Mitrou, and Nicholas Pavlidis. Bone and soft tissue sarcomas during pregnancy: A

- narrative review of the literature. *J Adv Res.* 2016; 7(4):581-7.
9. Lysyj A, Bergquist JR. Pregnancy complicated by sarcoma. Report of two cases. *Obstet Gynecol* 1963;21:506-9.
  10. Nepal P, Singh GK, Singh MP, et al. Osteosarcoma in pregnancy. *JNMA J Nepal Med Assoc* 2005;44(159):100-1
  11. Huh WW, Holsinger FC, Levy A, Palla FS, Anderson PM. Osteosarcoma of the jaw in children and young adults. *Head Neck* 2012;34(7):981-4.
  12. Chaudhary M, Chaudhary SD. Osteosarcoma of jaws. *J Oral Maxillofac Pathol* 2012;16(2):233-8.
  13. Sinha R, Chowdhury SR, Chattopadhyay P, Rajkumar K. Low-grade osteosarcoma of the mandible. *Journal of maxillofacial and oral surgery* 2010;9(2):186-90.
  14. D AL, AlSheddi M, Al-Sadhan R. Epithelioid Osteosarcoma of the Maxilla: A Case Report and Review of the Literature. *Int J Surg Pathol* 2015;23(6):495-9.
  15. Klein MJ, Siegal GP. Osteosarcoma anatomic and histologic variants. *American journal of clinical pathology* 2006;125(4):555-81.
  16. von Zeidler SLV, Sol M, Viera J.A.R, Oliveira M.G, De Podesta J.R.V, Careta R.S, et al. Histopathological features of the gnathic osteosarcoma: Case report. *Oral Surgery, Oral Medicine, Oral Pathology and Oral Radiology.* 2014;117(2):e163.
  17. Layton SA, Rintoul M, Avery BS. Oral carcinoma in pregnancy. *Br J Oral Maxillofac Surg* 1992;30(3):161-4.
  18. Pariyar J, Shrestha B, Rauniyar BP, et al. Cancer with pregnancy in a cancer hospital. *J Nepal Health Res Counc* 2012;10(22):224-8.
  19. Cheung EJ, Wagner H, Jr., Botti JJ, Fedok F, Goldenberg D. Advanced oral tongue cancer in a 22-year-old pregnant woman. *Ann Otol Rhinol Laryngol* 2009;118(1):21-6.