



## CASE REPORT

# Multiple Cerebral Juvenile Xanthogranuloma; a Case Report

Sima Fallah-Arzpeima<sup>1</sup>, Bahram Darbandi<sup>2</sup>, Afagh Hassanzadeh Rad<sup>3</sup>, Mohammad Haghani Dogahe<sup>4</sup>, Parham Niyasti<sup>4</sup>, Adel Baghersalimi<sup>5</sup>

<sup>1</sup>Assistant Professor of Radiology, Department of Radiology, School of Medicine, Alzahra Hospital, Poursina Hospital, Guilan University of Medical Sciences, Rasht, Iran

<sup>2</sup>Associated Professor of Pediatric Hematology and Oncology, Pediatric Diseases Research Center, Guilan University of Medical Sciences, Rasht, Iran

<sup>3</sup>PhD of Linguistics, Pediatric Diseases Research Center, Guilan University of Medical Sciences, Rasht, Iran

<sup>4</sup>Medical Student, Guilan University of Medical sciences, Rasht, Iran

<sup>5</sup>Assistant Professor of pediatric hematology and oncology, Pediatric Diseases Research Center, Guilan University of Medical Sciences, Rasht, Iran

## ARTICLE INFO

### Article History:

Received: 25.10.2019

Accepted: 06.01.2020

### Keywords:

Juvenile xanthogranuloma

Child

Magnetic resonance imaging

Radiotherapy

Follow-Up

### \*Corresponding author:

Adel Baghersalimi,  
17 Shahrivar Hospital, Siadati Street,  
Rasht, Iran

Tel: +98 13 33369002

Email: [bahersalimi498@yahoo.com](mailto:bahersalimi498@yahoo.com)

## ABSTRACT

Juvenile xanthogranuloma (JXG), is the most common form of non-Langerhans cell histiocytosis. It is a rare and usually benign, monoclonal proliferative disorder of histiocytic cells. The occurrence of multiple brain lesions is extremely rare. Due to the rarity of CNS disease, the preferred treatment and overall prognosis of these patients remain unclear. In this case report, authors present their experience about a patient with isolated multiple cerebral JXG which yields considerable outcomes. The patient was an eleven-year-old boy with anorexia and recurrent vomiting. Brain MRI demonstrated multiple lesions involving right lateral ventricle wall and periventricular white matter, the right side of splenium, mammillary body and tuber cinereum, fourth ventricle floor and roof, and cerebellar tonsil. After initial response to chemotherapy, the lesions recurred and radiotherapy was done. Consequent to good response after radiotherapy and despite the occurrence of a seizure attack, long term follow-up showed the marked resolution of the lesions and a good general status.

Please cite this article as: Fallah-Arzpeima S, Darbandi B, Hassanzadeh Rad A, Haghani Dogahe M, Parham Niyasti, Baghersalimi A. Multiple Cerebral Juvenile Xanthogranuloma; a Case Report. IJBC 2020; 12(1): 29-33.

## Introduction

Juvenile xanthogranuloma (JXG), which was introduced in 1905, is the most common form of non-Langerhans cell histiocytosis. It is a rare and usually benign, monoclonal proliferative disorder of histiocytic cells resembling dermal dendrocyte.<sup>1-6</sup> It is presumed that JXG develops after unknown stimuli that provoke a granulomatous histiocytic reaction. However, the true etiology of JXG is currently unknown.<sup>3</sup>

In most patients (67%), JXG is characterized by asymptomatic solitary yellow-brown papules or nodules found on the face and neck which are well-demarcated, firm, rubbery, or round usually varying from 0.5 to 2 cm in diameter.<sup>3, 7, 8</sup> Cutaneous lesions are usually asymptomatic and most lesions spontaneously involute. However, some cases present at non-cutaneous sites and can result in serious complications.<sup>3</sup> Moreover, in

5% of patients, there are multiple cutaneous lesions or involvement of visceral organs (systemic JXG) with or without skin lesions.<sup>2</sup> Systemic involvements include organs such as eyes, lung, liver, spleen and central nervous system (CNS).<sup>9</sup> Cutaneous JXG with systemic visceral and CNS involvement is rare (4% of cases) with significant mortality and morbidity.<sup>9</sup> A smaller subgroup of patients presents with isolated CNS disease with no systemic involvement.<sup>10</sup> In addition, the occurrence of multiple brain lesions is extremely rare.<sup>11</sup> This subgroup appears unique in terms of patient characteristics, treatment, and outcome. Due to the rarity of CNS disease, the preferred treatment and overall prognosis of these patients remain unclear.<sup>8, 10</sup> In this case report, authors present their experience about a patient with isolated multiple cerebral JXG which yields considerable outcomes.

### Case Presentation

An eleven-year-old boy with a chief complaint of anorexia and recurrent vomiting in the late two months was admitted to a tertiary care hospital. He weighed 18.5 Kg and noted 8-kilogram weight loss during that period. Vomiting was projectile, non-bloody, and progressive in severity and frequency and was not related to feeding or waking up from sleep. Written informed consent was obtained from the parents to report the case.

First diagnostic work-ups including hematological indices, biochemistries, electrolyte levels and imaging studies (chest X-ray and abdominal ultrasound) were normal. In the next step, upper gastrointestinal endoscopy and biopsy were performed. As minimal chronic gastritis was the only finding. After a partial recovery of symptoms, the patient's complaints were relapsed in conjunction with new-onset attacks of headache. Therefore, a Magnetic Resonance Imaging (MRI) of the brain with a contrast injection was performed after hospitalization in 17 Shahrivar children hospital on January 13th, 2016. MRI demonstrated multifocal signal abnormality involving right lateral ventricle wall and periventricular white matter, the right side of splenium, mammillary body and tuber cinereum, fourth ventricle floor and roof (fastigium) and cerebellar tonsil. Contrast injection showed remarkable and intense enhancement of the above-mentioned lesions (Figure 1). These findings suggested infiltrative processes such as primary brain malignancies or lymphoma. Further diagnostic work-ups including bone marrow study, cerebrospinal fluid (CSF) analysis and, whole-body scan by Technetium-99 (Tc99) were normal.

For defining the nature of the lesions, a stereotactic biopsy was taken. Pathology study on the sample showed a chronic infiltrative process mostly composed of lymphocytes and macrophages. Using immunohistochemistry (IHC) study, the specimen showed CD68, CD3, CD20, GFAP (Glial

Fibrillary Acidic Protein) and Synaptophysin positive cells while they were negative for S100 and CD1a. These findings were compatible with the diagnosis of multiple cerebral juvenile xanthogranulomata.

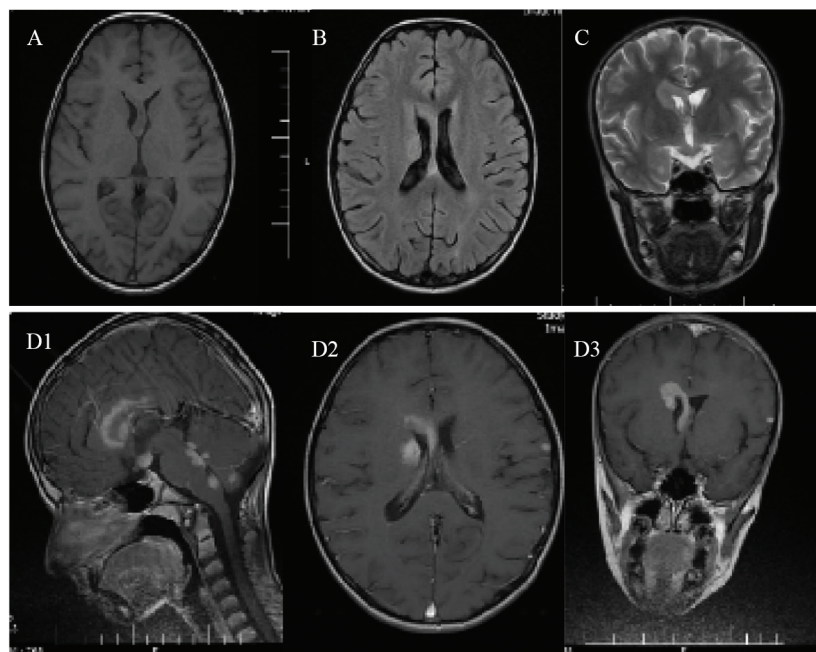
Regarding the number, size and, location of the lesions, treatment using the LCH-III protocol was started. Anorexia and vomiting disappeared and his overall health status was improved dramatically after six weeks of induction using prednisolone, vinblastine, and methotrexate. The patient's weight increased to 20 Kg and brain MRI showed a reduction in size and enhancement of brain lesions (Figure 2).

About 100 days after entering the continuation phase using 6-mercaptopurine, prednisolone, vinblastine, and methotrexate, the patient's symptoms relapsed and his weight decreased to 17 Kg. Brain MRI also showed an increase in size and enhancement of lesions (Figure 3).

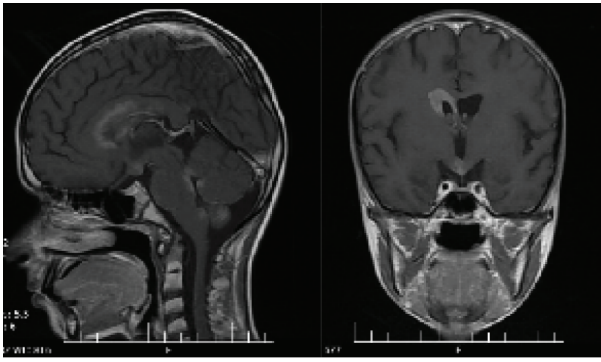
Therefore, the patient labeled as a relapsed case and treatment plan switched to chemotherapy protocol consisting of cladribine plus high dose Ara-C for 2 courses. But symptoms were persistent and brain MRI showed no significant change in the size of brain masses. At this stage, chemotherapy discontinued and cranial radiotherapy was employed. Using this approach, the patient's complaints and symptoms were improved dramatically and his weight increased to 21 Kg. Also, brain MRI showed a significant reduction in tumor size (Figure 4).

Regular follow-up to assess the patient's overall health status, weight measuring and performing a brain MRI was started after 3 months off-therapy until now (July 2019). Serial brain MRI showed no significant change in mass sizes and the patient's weight had an increasing trend from 21 Kg at the end of radiotherapy to 31 Kg in the last follow-up course.

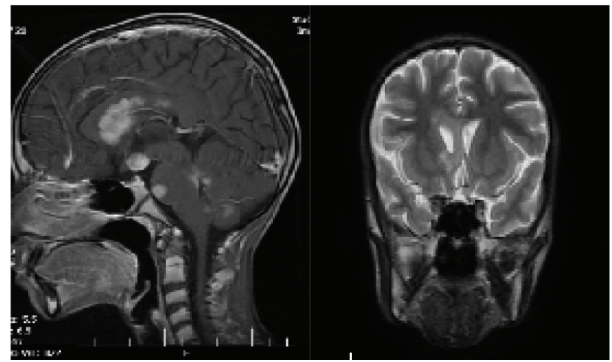
Thirty-five months after completion of treatment, the patient admitted again due to a generalized seizure new



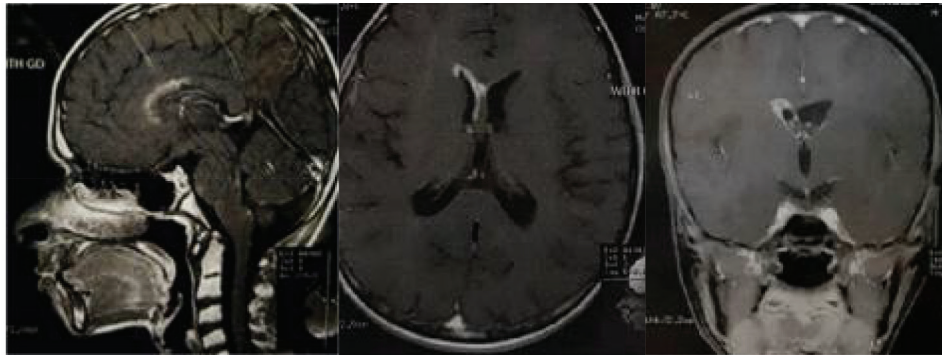
**Figure 1:** MRI images show multiple signal abnormalities ( Iso-signal on T1 weighted in figure A and high signal on flair T2 weighted in figure B and C ) involving Right ventricle wall and splenium , fourth ventricle floor and roof , and cerebellar tonsil with intense enhancement on post contrast images, respectively. (D1,D2 and D3)



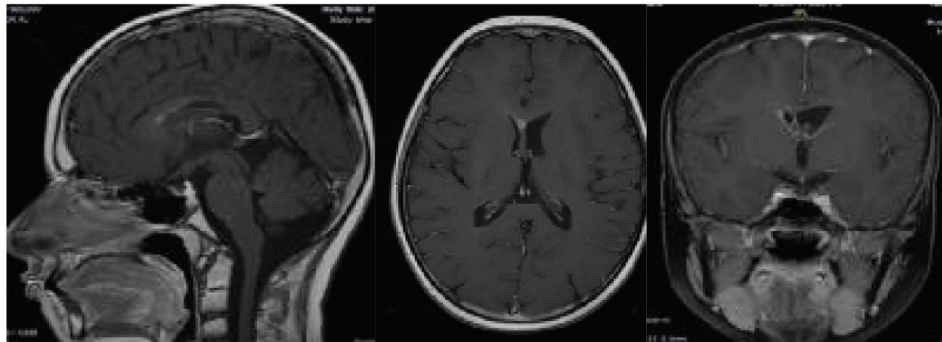
**Figure 2:** Post contrast images demonstrate reduction in size and enhancement of brain lesions



**Figure 3:** In MRI images relapsing of brain lesions are visible



**Figure 4:** Sagittal, axial, and coronal post contrast images respectively show the size and enhancement of lesions are decreased in comparison with previous brain MRI



**Figure 5:** Only linear and nodular enhancements along with right lateral ventricle wall are seen

brain MRI showed no significant change in the size of lesions. Due to the patient's overall good health status, not relevant imaging findings indicative of tumor relapse and normality of other work-ups; a decision was made to anticonvulsant usage, continue close follow-up, and no treatment for cerebral lesions per se.

The post-seizure follow-up of the patient up to six months revealed a good overall health status and increasing body weight to 39 kg, and a reduction in size and number of brain lesions were obvious in brain MRI (Figure 5).

## Discussion

It is extremely rare to diagnose a patient with isolated intracranial JXG without cutaneous or other organs involvement. So far, few cases have been reported it. While the imaging characteristics are nonspecific, MRI examination is the first option for localizing the lesions. MRI finding of most intracranial JXG lesions are iso-signal T1 weighted and high signal T2 mass with

homogenous enhancement. Their location and radiological characteristics mimic other primary intracranial tumors, such as meningioma, schwannoma, nerve sheath tumor, ependymoma, glioma, and Rosai-Dorfman disease, as well as granulomatous lesions. Thus, the gold standard for the diagnosis of JXG is histopathologic examination. Multiple intracranial lesions were more common than solitary lesions and a small subgroup of JXG with CNS involvement, but without systemic visceral or cutaneous disease has been reported.<sup>12-14</sup>

Although most cases of systemic JXG typically have a benign clinical course and does not require treatment, it can rarely lead to symptoms or even be fatal and may need any combination of surgery, chemotherapy, radiotherapy, and immunosuppression. In general adjuvant radiation and/or chemotherapy are often administered for the rare patients with symptomatic, unresectable, tumor regrowth or incompletely resected extracutaneous disease, but the response to these treatments is typically partial. In cases of tumor regrowth and patients with inaccessible lesions,



adjuvant therapy should probably be given earlier. These recommendations are based on a very small number of patients; first-line treatment other than surgery has not been established.<sup>3, 8, 9, 15</sup>

In this case, LCH III was used for treatment and indicated a primary significant response. Two previous case reports used LCH-based multiagent chemotherapy as well. The first case report used prednisolone, vinblastine, and methotrexate on a 42-month-old boy with disseminated papular skin lesions and multiple brain lesions. This regimen caused regression of skin and CNS lesions. However, 6 months after completion of chemotherapy, cutaneous but not CNS lesions relapsed.<sup>11</sup> The second one used additional cytarabine on a one-year-old girl with systemic JXG and a tumor at the left pontine angle with dysmorphic histiocytes in her spinal fluid for 12 months. By this treatment, symptoms ameliorated rapidly and during 1-year follow-up, she became normal.<sup>16</sup> Although, in this study clinicians encountered problems with the treatment because one hundred days after the initiation of continuation phase, symptoms relapsed and brain lesions' size increased.

In the current study, clinicians used 2 courses of Cladribine and high-dose Ara-C without a significant response. A clinical trial in 2016 studied outcomes of patients with refractory, risk-organ-positive Langerhans cell histiocytosis using mentioned protocol. After 2 courses, an overall response rate of 92% and an overall survival rate of 85% were reported.<sup>17</sup>

At this stage, cranial radiotherapy was initiated. The response was dramatic and a significant improvement in symptoms and tumor size was appreciated. Two case reports in 2007 and 2012 investigated cranial radiation outcomes in an 11-year-old and a 13-year-old patients, respectively, with refractory symptomatic intracranial and leptomeningeal JXG. After being refractory to commonly used chemotherapy regimen, cranial radiotherapy was initiated which led to resolution of the masses and marked improvement in neurological symptoms.<sup>18, 19</sup>

As intracranial lesions have a tendency to grow slowly;<sup>10</sup> clinicians followed their case every 3 months for 6 months and continued the process every 6 months until now with brain MRI. Totally eight follow-ups were performed for a total 3.5 years. Serial brain MRI showed no significant change in mass size and the patient's general condition do well and weight had an increasing trend just before the seventh follow up. As at that time, the patient experienced a seizure attack probably unrelated to brain lesions, a decision making to continue "no treatment strategy" for cerebral lesions per se seemed logical. Despite the occurrence of seizure, it is noteworthy that in the last follow up, clinicians detected a significant reduction in size and number of brain lesions and the patient maintained a good overall health status. As stated before by other investigators,<sup>6, 19</sup> clinicians believe that longer follow-ups could change the prognosis and the preferred management of these patients.

## Conclusion

JXG should be considered in the differential diagnosis

of any child presenting with CNS lesions. MRI is the modality of choice for localization of CNS lesions and provides precious information for further planning in diagnosis and management. Histopathology examination is mandatory for a definite diagnosis. It remains important to report patients with isolated CNS JXG to increase our cumulative experience with the treatment of this rare condition and to clarify management strategies.

**Conflict of Interest:** None declared.

## References

1. Mudambi K, Berquist W. "Blueberry Muffin" Rash and Neonatal Cholestatic Liver Failure. *Dig Dis Sci*. 2018;63(7):1747-50.doi: 10.1007/s10620-017-4810-9. PubMed PMID: 29071487.
2. Folster-Holst R. Severe systemic juvenile xanthogranuloma is an indication for systemic therapy. *Br J Dermatol*. 2017;176(2):302-4.doi: 10.1111/bjd.15297. PubMed PMID: 28244093.
3. Collie JS, Fillman EP. Xanthogranuloma, Juvenile (Nevoxanthoendothelioma, JXG). *StatPearls*. Treasure Island (FL): StatPearls Publishing LLC.; 2018.
4. Emile J-F, Ablu O, Fraitag S, Horne A, Haroche J, Donadieu J, et al. Revised classification of histiocytoses and neoplasms of the macrophage-dendritic cell lineages. *Blood*. 2016;127(22):2672-81.
5. Lee TK, Jung TY, Baek HJ, Kim SK, Lee KH, Yun SJ. Disseminated juvenile xanthogranuloma occurring after treatment of Langerhans cell histiocytosis: a case report. *Childs Nerv Syst*. 2018;34(4):765-70.doi: 10.1007/s00381-017-3675-8. PubMed PMID: 29209883.
6. Zahir ST, Sharahjin NS, Vahedian H, Akhavan A. Juvenile xanthogranuloma presenting as a large neck mass and ocular complications: a diagnostic and therapeutic dilemma. *BMJ Case Rep*. 2014;2014.doi: 10.1136/bcr-2013-202683. PubMed PMID: 24810447. PubMed Central PMCID: PMC3992604.
7. Irmola T, Laitinen MK, Parkkinen J, Engellau J, Neva MH. Solitary juvenile xanthogranuloma in the spine pretreated with neoadjuvant denosumab therapy followed by surgical resection in a 5-year-old child: case report and literature review. *Eur Spine J*. 2018.doi: 10.1007/s00586-018-5651-8. PubMed PMID: 29876657.
8. Hernandez-Martin A, Baselga E, Drolet BA, Esterly NB. Juvenile xanthogranuloma. *Journal of the American Academy of Dermatology*. 1997;36(3):355-67.doi: https://doi.org/10.1016/S0190-9622(97)80207-1.
9. Tamir I, Davir R, Fellig Y, Weintraub M, Constantini S, Spektor S. Solitary juvenile xanthogranuloma mimicking intracranial tumor in children. *J Clin Neurosci*. 2013;20(1):183-8.doi: 10.1016/j.jocn.2012.05.019. PubMed PMID: 22999559.
10. Lalitha P, Reddy MCB, Reddy KJ. Extensive Intracranial Juvenile Xanthogranulomas. *American Journal of Neuroradiology*. 2011;32(7):E132-E3.doi: 10.3174/ajnr.A2209.

11. Jain P, Naik G, Uppor S, Kamath D. Diode laser and fluoride varnish in the management of dentin hypersensitivity. *Indian Journal of Paediatric Dermatology*. 2016;17(1):71-4.doi: 10.4103/2229-5194.173226.
12. Janssen D, Harms D. Juvenile xanthogranuloma in childhood and adolescence: a clinicopathologic study of 129 patients from the kiel pediatric tumor registry. *The American journal of surgical pathology*. 2005;29(1):21-8.
13. Oliveira TE, Tarle RG, Mesquita LAF. Dermoscopy in the diagnosis of juvenile xanthogranuloma. *An Bras Dermatol*. 2018;93(1):138-40.doi: 10.1590/abd1806-4841.20186849. PubMed PMID: 29641718. PubMed Central PMCID: PMC5871383.
14. Pantalon A, Stefanache T, Danciu M, Zurac S, Chiselita D. Iris juvenile xanthogranuloma in an infant - spontaneous hyphema and secondary glaucoma. *Rom J Ophthalmol*. 2017;61(3):229-36. PubMed PMID: 29450403. PubMed Central PMCID: PMC5710043.
15. Stover DG, Alapati S, Regueira O, Turner C, Whitlock JA. Treatment of juvenile xanthogranuloma. *Pediatr Blood Cancer*. 2008;51(1):130-3.doi: 10.1002/pbc.21523. PubMed PMID: 18338395.
16. Nakatani T, Morimoto A, Kato R, Tokuda S, Sugimoto T, Tokiwa K, et al. Successful treatment of congenital systemic juvenile xanthogranuloma with Langerhans cell histiocytosis-based chemotherapy. *J Pediatr Hematol Oncol*. 2004;26(6):371-4. PubMed PMID: 15167350.
17. Donadieu J, Bernard F, Van Noesel M, Barkaoui M, Bardet O, Mura R, et al. Cladribine and cytarabine in refractory multisystem Langerhans cell histiocytosis: results of an international phase 2 study. *Blood*. 2015;126(12):1415-23.
18. Orsey A, Paessler M, Lange BJ, Nichols KE. Central nervous system juvenile xanthogranuloma with malignant transformation. *Pediatr Blood Cancer*. 2008;50(4):927-30.doi: 10.1002/pbc.21252. PubMed PMID: 17520744.
19. Vijapura CA, Fulbright JM. Use of radiation in treatment of central nervous system juvenile xanthogranulomatosis. *Pediatr Hematol Oncol*. 2012;29(5):440-5.doi: 10.3109/08880018.2012.691151. PubMed PMID: 22712784.