



## CASE REPORT

# Carcinosarcoma of the Maxillary Sinus: A Case Report

Sethu Thakachy Subha<sup>1</sup>, MS; Mohamad Doi<sup>2</sup>, MS; Nor Yatizah Mohd Yatim<sup>3</sup>, MD

<sup>1</sup>Department of Surgery/ENT, Universiti Putra Malaysia (UPM), Serdang, 43400, Selangor, Malaysia

<sup>2</sup>Department of ENT, Hospital Serdang, Ministry of Health, Malaysia, Serdang, Selangor, 43400, Malaysia

<sup>3</sup>Department of Pathology, Hospital Serdang, Ministry of Health Malaysia, Serdang, Selangor, 43400, Malaysia

## ARTICLE INFO

### Article History:

Received: 28.05.2020

Accepted: 20.07.2020

### Keywords:

Carcinosarcoma

Immunohistochemistry

Maxillary sinus

Nasal cavity

Prognosis

### \*Corresponding author:

Sethu Thakachy Subha, MS;

Department of Surgery/ENT

Universiti Putra Malaysia (UPM),

Serdang, 43400, Selangor, Malaysia

Tel: +60-123459420

Fax: +60-389455217

Email: [subhast2@yahoo.com](mailto:subhast2@yahoo.com)

## ABSTRACT

Carcinosarcoma is a highly malignant tumour exhibiting histological components of both carcinomatous and sarcomatoid elements. Carcinosarcoma is extremely rare in the sinonasal cavity. Due to the rarity and clinical diversity, these neoplasms are often misdiagnosed and pose a challenge in their management.

Here we report a 44-year-old man with epistaxis and progressive symptoms of nasal obstruction. Nasal endoscopy revealed a polypoid mass in right middle meatus extending into the nasal cavity. Polypectomy through endoscopic sinus surgery was performed. Carcinosarcoma was diagnosed based on histopathology and immunohistochemical studies. The patient underwent total maxillectomy followed by radiotherapy for the residual tumor. Unfortunately, the patient suffered from multiple recurrences during 20 months following primary resection. This report is to emphasize the need for early diagnosis and radical multimodality intervention for this rare malignancy with an ominous prognosis.

Please cite this article as: Subha ST, Doi M, Mohd Yatim NY. Carcinosarcoma of the Maxillary Sinus: A Case Report. IJBC 2020; 12(3): 101-103.

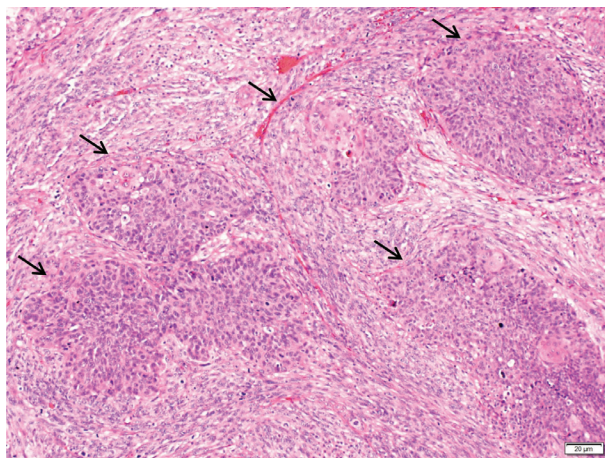
## Introduction

Carcinosarcoma is a rare morphologically heterogeneous and locally aggressive malignant neoplasm.<sup>1</sup> In the head and neck, the carcinosarcoma frequently involves the larynx and pharynx; while extremely rare in the maxillary region.<sup>2-5</sup> Regarding the pathogenesis of this neoplasm, there is increasing evidence that carcinosarcoma is a monoclonal neoplasm originating from a single totipotent stem cell that differentiates into separate epithelial and mesenchymal components.<sup>4, 5</sup> The clinical presentation of sinonasal carcinosarcoma is nonspecific; the initial symptoms include epistaxis, nasal obstruction, and facial pain.<sup>6,7</sup> We report a rare case of sinonasal carcinosarcoma with aggressive behaviour who developed frequent recurrences showing a poor prognosis.

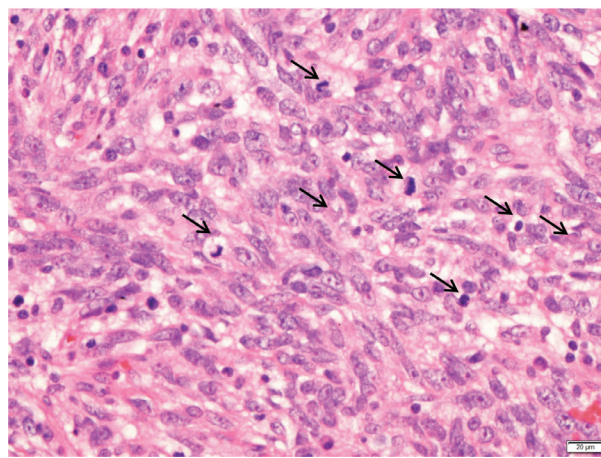
## Case Presentation

A 44-year-old man presented with epistaxis, symptoms

of nasal obstruction and facial pain for a few months. He denied any head ache or orbital symptoms. He was hypertensive with history of chronic smoking. Nasal endoscopy revealed a polypoid mass extending from the right middle meatus to the nasal cavity with blood stained purulent discharge and deviated nasal septum. CT-scan of paranasal sinus showed a mass lesion in right maxillary sinus extending to the nasal cavity with dehiscent right lamina papyracea. Endoscopic sinus surgery and polypectomy was performed. Histopathological examination demonstrated malignant epithelial and mesenchymal cells with frequent mitotic figures (Figures 1 and 2). Immunohistochemical staining of the tumor cells was positive for MNF 116 and epithelial membrane antigen (EMA). Accordingly, the polypoid lesion was designated as carcinosarcoma. Repeated CT-scan, two weeks after excision demonstrated an irregular enhancing mass in the right maxillary sinus with extension to right ethmoid and frontal sinuses and



**Figure 1:** Epithelial (squamous; arrow) and surrounding mesenchymal components of the sinonasal carcinosarcoma (100×).



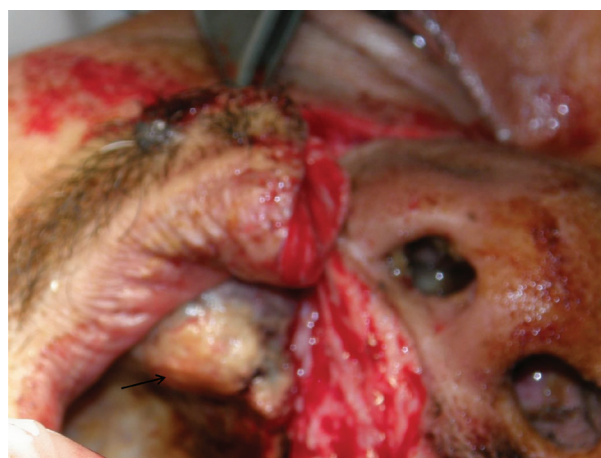**Figure 2:** Mesenchymal component with mitotic figures (arrow) in the tumor (400×)

erosion of medial wall and floor of the right maxillary sinus, nasal septum and medial wall of the orbit. There was no intracranial extension. Patient underwent total maxillectomy; intraoperatively the tumour was found to be involving the whole maxillary antrum eroding the floor, extending to the right ethmoid sinus, middle meatus and nasal cavity (Figure 3). He received postoperative radiotherapy; however, he was noted to have residual tumor five months after initial diagnosis that underwent re-surgery followed by re-irradiation of the tumor bed. During the follow up he was noted to have recurrence of the tumor over right nasal cavity to the anterior cranial fossa and orbit.

He refused to undergo any further surgical treatment and was referred to oncology department. He succumbed to death due to recurrent disease twenty months after primary diagnosis.

### Discussion

Sinonasal carcinosarcoma is a rare neoplasm characterised by complex histological pattern consisting of malignant epithelial and mesenchymal components.<sup>1-4</sup> This distinct combination of tissue components and low incidence of the tumor makes the diagnosis of carcinosarcoma a challenging entity.<sup>5-7</sup> This aggressive neoplasm is mainly seen among adults with average age of 60 years with male preponderance.<sup>2, 6</sup> Our patient was slightly younger than other reported patients. The proposed predisposing factors are smoking, alcohol consumption and history of previous irradiation.<sup>2, 4, 5</sup> The initial clinical features of sinonasal carcinosarcoma may mimic benign conditions like chronic sinusitis, sinonasal polyposis or allergic rhinitis.<sup>1-3, 6</sup> Grossly, these tumors are reddish friable polypoid masses with variegated appearance on cut surface and areas of necrosis and haemorrhage.<sup>4, 5</sup> Microscopically, the carcinomatous component is represented by in situ or an invasive squamous cell carcinoma. The sarcomatoid fraction of the tumor is arranged in storiform or whorled with interlacing bundles or fascicles.<sup>5</sup> The complex histological pattern and rarity of the carcinosarcoma may lead to incorrect diagnoses of spindle cell sarcoma, nodular fasciitis, malignant fibrous histiosarcoma, fibrosarcoma, synovial sarcoma



**Figure 3:** Excision of the mass in the right maxillary sinus by lateral rhinotomy approach

and malignant melanoma.<sup>4, 5</sup>

Immunohistochemical staining is an important diagnostic tool for carcinosarcoma which is dependent on the cell type.<sup>4</sup> Galen et al. noted that epithelial components were positive for cytokeratin and EMA; whereas, mesenchymal components showed positive results for vimentin and focal muscle actin, desmin and S-100 protein.

The optimal treatment of this tumour remains unclear due to its rarity.<sup>1, 3, 6, 7</sup> Treatment of this malignant neoplasm poses a challenge due to aggressive course of the tumor with high chances of recurrence.<sup>1, 3, 7, 8</sup> Previous published series demonstrated that patients who were treated with surgery alone had a high recurrence rate in contrast to those receiving adjuvant radiation therapy.<sup>1, 3, 6-8</sup> The role of adjuvant chemotherapy is not well defined.

Patel et al. in the largest cohort of sinonasal carcinosarcoma patients using SEER database reported that five- and ten-year disease specific survival rates were found to be lower than those of non-sinonasal carcinosarcoma.<sup>6</sup> This infrequent neoplasm has a high propensity for locoregional recurrence causing morbidity and mortality. The rate of local recurrence of carcinosarcoma following surgical excision has been reported as high as 42% at 21months.<sup>8</sup> Local recurrence frequently leads to treatment failure and subsequent

death.<sup>7,8</sup> Our patient succumbed to death 20 months after initial diagnosis.

### Conclusion

Sinonasal carcinosarcoma is a rare aggressive neoplasm with high local recurrence and poor survival rate that can initially present as nasal polyps. Patients with prolonged signs of nasal obstruction should be consulted with ear and nose specialists to go through sinonasal endoscopy for definite diagnosis and appropriate management.

### Acknowledgement

We are grateful to the Director General of Health Malaysia for approval of this study and report.

**Conflict of Interest:** None declared.

### References

1. Moon JK, Kim AY, Chang DS, Park KY. Carcinosarcoma of the maxillary sinus. *Clin Exp Otorhinolaryngol*. 2013; 6 (2):114–6.
2. Sanabre AA, Gonzalez-Launas J, Redecilla PH, Martin GR. Carcinosarcoma of the maxillary sinus: a case report. *J Oral Maxillofac Surg*. 1998; 56(12):1456–60. doi: 10.1016/s0278-2391(98)90417-7. PubMed PMID: 9846548.
3. Yuen J, Varadarajan V, Stavarakas M, Muquit S, Khalil H. A Case of Invasive sinonasal carcinosarcoma: the importance of early detection. *Case Rep Otolaryngol*. 2018. Article ID 2745973. doi: 10.1155/2018/2745973.
4. Gale N, Zidar N. Spindle cell carcinoma: Benign and potentially malignant lesions of the squamous epithelium and squamous cell carcinoma. In: Cardesa A, Slootweg PJ, eds. *Pathology of the Head and Neck*. Berlin: Springer-Verlag; 2006:16–17.
5. Thompson L, Chang B, Barsky SH. Monoclonal origins of malignant mixed tumors (carcinosarcomas). Evidence for a divergent histogenesis. *Am J Surg Pathol*. 1996; 20(3):277–85. doi: 10.1097/00000478-199603000-00003.
6. Patel TD, Vazquez A, Plitt MA, Baredes S, Eloy JA. A case-control analysis of survival outcomes in sinonasal carcinosarcoma. *Am J Otolaryngology*. 2015; 36(2): 200–4. doi: 10.1016/j.amjoto.2014.10.031.
7. Gore MR. Treatment, outcomes, and demographics in sinonasal sarcoma: a systematic review of the literature. *BMC Ear Nose Throat Disorders*. 2018; 18:4. doi: 10.1186/s12901-018-0052-5. PubMed PMID: 29581706. PubMed Central PMCID: PMC5861608.
8. Hasnaoui J, Anajar S, Tatari M, Abada R, Rouadi S, Roubal M, et al. Carcinosarcoma of the maxillary sinus: A rare case report. *Ann Med Surg (Lond)*. 2017;19: 41–4. doi: 10.1016/j.amsu.2017.05.036.