



PHOTO CLINIC

CMV-induced Duodenal Papillitis in a Child with Acute Lymphoblastic Leukemia

Parastou Molai Tavana¹, Mitra Khalili^{2*}, Samin Alavi¹

¹Pediatric Congenital Hematologic Disorders Research Center, Research Institute for Children's Health, Shahid Beheshti University of Medical Sciences, Tehran, Iran

²Pediatric Radiology Department, Mofid Children's Hospital, Shahid Beheshti University of Medical Sciences, Tehran, Iran

ARTICLE INFO

Article History:

Received: 02.10.2019

Accepted: 13.11.2019

*Corresponding author:

Mitra Khalili,
Pediatric Radiology Department,
Mofid Children's Hospital, Shahid
Beheshti University of Medical
Sciences, Tehran, Iran
Email: m.khalili76@sbmu.ac.ir

Please cite this article as: Molai Tavana P, Khalili M, Alavi S. CMV-induced Duodenal Papillitis in a Child with Acute Lymphoblastic Leukemia. IJBC 2019; 11(4): 150-152.

A 12-year-old boy, a known case of ALL in remission on maintenance phase of treatment was admitted with fever, severe malaise, and abdominal pain. On physical examination, he was febrile and pale. Abdominal tenderness with localization on right lower quadrant associated with some degrees of rebound tenderness was remarkable. Initial work-up including blood count showed pancytopenia. Leukopenia with lymphopenia was noticeable. Blood cultures obtained at admission were negative. Bone marrow was examined which was negative for relapse. Abdominal ultrasound showed wall thickening of cecum and ascending colon with probable diagnosis of typhlitis. He received broad-spectrum antibiotics along with supportive care. Due to persistence

of fever and ultrasound findings, imaging including brain, chest and abdominopelvic spiral contrast-enhanced CT scan was performed to detect any evidence of fungal infections or suppurative collections. It displayed significant wall thickening and mural ulcerations of ascending and transverse colon along with symmetric bulging and thickening of duodenal papilla representing "duodenal papillitis" (Figure 1a and b). Dilatation of main pancreatic duct, common bile duct and central hepatic bile ducts were also remarkable (Figure 2). Surgical consultation recommended to continue with antibiotics with antipseudomonal activity.

Cytomegalovirus (CMV) infection was suggested as a cause of concomitant colitis and "duodenal papillitis"

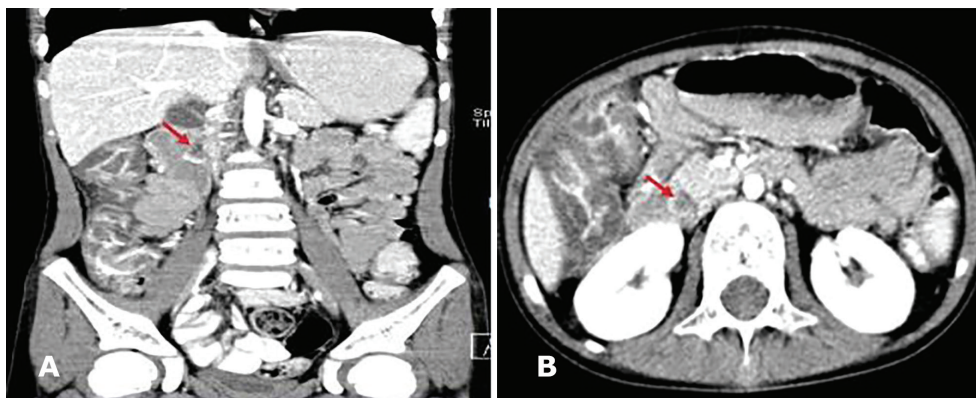


Figure 1: (A and B): Coronal and axial images of abdominal CT scan with IV and oral contrast show wall thickening and mural ulcerations of ascending and transverse colon along with symmetric bulging and thickening of duodenal papilla (Arrow).

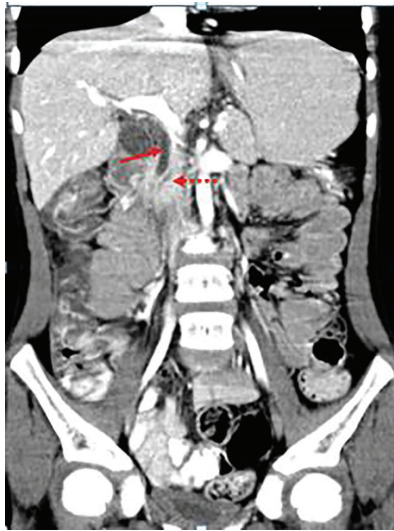


Figure 2: Coronal image of abdominal CT scan with IV and oral contrast shows dilation of common bile duct (straight arrow) and pancreatic duct (dotted arrow)

by our radiologist. Viral assessment for CMV was performed. Plasma CMV was positive with quantitative real time PCR level of 38000 IU/ml. The patient was diagnosed as “CMV duodenal papillitis” associated with some degrees of colitis, and was scheduled to receive intravenous ganciclovir for four weeks followed by oral valganciclovir (10 mg/kg twice daily) until negative results for CMV were achieved. His symptoms recovered, the cytopenia normalized and general condition of the patient improved in a few days.

Viral infections are an underestimated complication in children on standard chemotherapy for ALL. In countries with a high seroprevalence, CMV disease could be an important morbidity leading to end-organ damage in different organs (1). Clinical manifestations of CMV infection is highly variable and dependent on the immune status of the host. Infection in the immunocompetent children is commonly asymptomatic, whereas infections in immunocompromised patients cause significant morbidity and mortality.

Data regarding the incidence and manifestations of CMV disease in pediatric ALL patients are limited. In pediatric ALL in non-transplant settings, CMV disease is very rare with only a few reported cases in the literature. Until 2015, twelve cases of CMV disease in non-transplanted children with ALL has been reported which were comprised of CMV retinitis in 7, hepatosplenic in 3, hemophagocytic lymphohistiocytosis in 2 and CMV pneumonitis in 1 patient (2).

CMV infection is the main cause of gastrointestinal infectious problems such as diarrhea, hemorrhage and perforation in immunocompromised patients. CMV colitis characteristically manifests as cecal wall thickening with contiguous involvement of the terminal ileum and ascending colon. Mucosal ulcerations are frequent and may appear round or serpiginous. CT findings in gastrointestinal CMV infection are similar to those in typhlitis with target sign that can be illustrated even on unenhanced CT scans (3).

CMV-induced duodenal papillitis is a very rare

complication of CMV infection in immunocompromised patients. There are only 3 reports of CMV-induced papillitis in patients with HIV infection in the literature until 2015 which all of them were reported from Japan (4-6). A 40-year-old man with HIV infection complaining of persistent diarrhea revealed to have a positive serum for CMV antigenemia. Upper GI endoscopy revealed the papilla of Vater to be reddish and enlarged. CMV infected cells were detected on immunohistochemistry. The lesions improved within two months after starting treatment with ganciclovir. Interestingly, he had also an active ulcer in the ileocecal valve on colonoscopy along with mucosal edema extended from the terminal ileum to the ileocecal valve (4). In another case report, a 52-year-old man with HIV infection developed vague abdominal pain with intermittent watery diarrhea in whom colonoscopy revealed multiple small ulcers in the ascending and transverse colon. Upper endoscopy showed edematous ampulla of Vater with hyperemic mucosal changes in the second portion of the duodenum. Histopathological examination revealed active papillitis with a few large cells infected with CMV confirmed by specific staining (6). In the third case who was a 59-year-old male with HIV-1 infection, CMV had induced pseudotumor of the duodenum. Endoscopic study revealed a tumor-like lesion with an irregular ulcer at the papilla of Vater. Histological and immunohistochemical studies revealed a CMV-induced pseudotumor and severely inflamed duodenal mucosa with infiltration of CMV-positive cells.

Our patient was the first report of a “CMV-induced duodenal papillitis” in a child with ALL on chemotherapy diagnosed on CT images. Clinically significant CMV reactivation is expected to occur in patients with severe immunodeficiency due to chemotherapy. Gastrointestinal CMV involving different parts of the alimentary tract should be considered in children with ALL with prolonged fever, diarrhea and abdominal symptoms and unexplained cytopenia.

Conflict of Interest: None declared.

References

1. Jain R, Trehan A, Mishra B, Singh R, Saud B, Bansal D. Cytomegalovirus disease in children with acute lymphoblastic leukemia. *Pediatric hematology and oncology*. 2016;33(4):239-47.
2. Rahbarimanesh A, Ehsani M, Karahroudi M, Rashidi A, Aghajani M, Meysami A, et al. Cytomegalovirus disease in children with acute lymphoblastic leukemia in the nontransplant setting: case series and review of the literature. *Journal of pediatric hematology/oncology*. 2015;37(6):429-32.
3. Teixidor HS, Honig CL, Norsoph E, Albert S, Mouradian J, Whalen J. Cytomegalovirus infection of the alimentary canal: radiologic findings with pathologic correlation. *Radiology*. 1987;163(2):317-23.
4. Nagao M, Okamoto T, Nishikawa J, Sakaida I. Cytomegalovirus-induced Duodenal Papillitis. *Internal Medicine*. 2015;54(13):1665-6.

5. Minami R, Takahama S, Nakashima E, Yamamoto M. CMV-induced duodenal papillitis in a patient with HIV-1 infection. *Kansenshogaku zasshi The Journal of the Japanese Association for Infectious Diseases*. 2013;87(4):441-5.
6. Kim Y, Cho Y, Lee J, Jin S, Shim C. Cytomegalovirus infection in an HIV patient with duodenal papillitis. *Endoscopy*. 2007;39(S 1):E23-E.