



LETTER TO EDITOR

Sirolimus: A Rapid Treatment for Coagulopathy Because of Vascular Malformations

Hossein Karami¹, Maryam Ghasemi², Seyed Abdollah Mousavi³, Mohammad Naderisorki^{1*}

¹Thalassemia Research Center (TRC), Hemoglobinopathy Institute, Mazandaran University of Medical Sciences, Sari, Iran

²Immunogenetics Research Center, Faculty of Medicine, Mazandaran University of Medical Sciences, Sari, Iran

³Department of Pediatric Surgery, Pediatric Infectious Diseases Research Center, Mazandaran University of Medical Sciences, Sari, Iran

ARTICLE INFO

Article History:

Received: 10.11.2020

Accepted: 20.12.2020

*Corresponding author:

Mohammad Naderisorki,
Bou Ali Sina Hospital, Mazandaran
University of Medical Sciences,
Pasdaran Boulevard, P.O. Box:
4815838477, Sari, Iran
Tel/Fax: +98-11-33342331
Email: dr.naderisorki@gmail.com

Please cite this article as: Karami H, Ghasemi M, Mousavi SA, Naderisorki M. Sirolimus: A Rapid Treatment for Coagulopathy Because of Vascular Malformations. IJBC 2020; 12(4): 141-142.

Dear Editor

The blue rubber bleb nevus syndrome (BRBNS) is a rare vascular malformation which is characterized by multiple compressible blue rubbery venous malformations of the skin and gastrointestinal tract.¹ This vascular malformation may present at birth (30%) or during childhood (48%).^{1, 2} Kasabach-Merritt syndrome is referred to a constellation of thrombocytopenia, microangiopathic hemolytic anemia, and an acute or chronic consumptive coagulopathy due to localized disseminated intravascular coagulation (DIC) in the setting of extensive giant vascular malformations.³

A 16-year-old man was admitted with long-term pallor and recent bleeding from his skin lesion. He was a known case of BRBNS firstly diagnosed at childhood by observation of skin and gastrointestinal malformations during surgery for acute appendicitis. Physical examination revealed multiple cutaneous rubbery angiomas over his back and extremities (figure 1). The laboratory data showed: *white blood cell* 5.7×10^3 /uL, hemoglobin 7.5 g/dL, platelet count of 34×10^9 /L, prothrombin time (PT) of 19.4 seconds, INR 2.8 and an activated prothrombin time (PTT) of 54.1 seconds. Other lab data were within normal limits.

The ulcerative cutaneous lesion was tried to be removed surgically which pathological examination of showed a true venous malformation represented by large, dilated

vessels lined by flat endothelium and presence of smooth muscle in vessel walls. Dilated vessels were filled by coagulated blood (figure 2).

The patient refused to receive beta-blockers or corticosteroids. Sirolimus was started as a single drug for the patient. Ten days later, the patient returned with normal hematological indices and coagulation tests despite any change in the size of the cutaneous angiomas. New laboratory tests revealed: *white blood cell* 8.3×10^3 /uL, hemoglobin 12.2 g/dL and platelet count 189×10^9 /L, PTT 38.6 seconds, PT 14.6 seconds and INR 1.6.

Corticosteroids, propranolol, interferon- α and vincristine have been used as antiangiogenic agents to treat BRBNS and subsequent kasabach-merritt syndrome for two

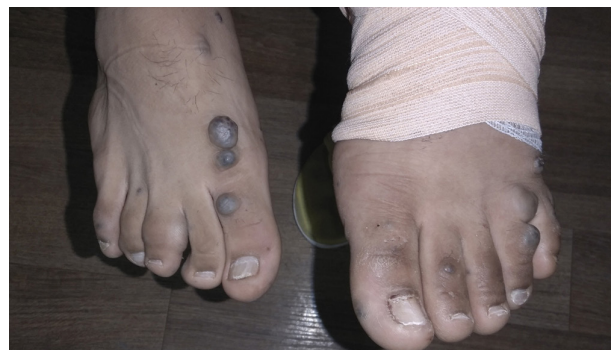

Figure 1: Multiple bleb-like blue rubbery malformations on the skin

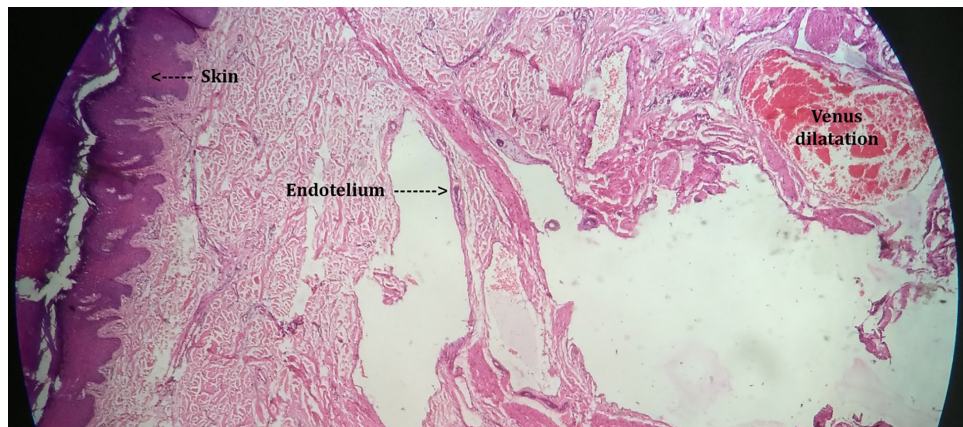


Figure 2: Irregular cavernous channels lined by a single layer of endothelial cells

decades.^{1,2,4} Sirolimus is a specific mammalian target of rapamycin (mTOR) inhibitor which acts as inhibitor of some cellular processes such as cell motility, cellular metabolism and cell growth.⁴ Sirolimus exerts its anti-angiogenic effects by inhibition of vascular endothelial growth factor (VEGF) and regulates angiogenesis and lymphangiogenesis by this way.⁵

It has been described that sirolimus as an angiogenesis inhibitor plays a life-saving role in the treatment of BRBNS and its complications.^{6,7} Zhang et al. reported effective control of size and coagulopathy of blue rubber bleb nevus syndrome in four pediatric patients receiving sirolimus. All four patients were administered oral sirolimus at doses of 1.0-1.5 mg/m²/day for median duration of 20 months. The median time to response was 7.5 weeks (range, 4–12 weeks). In three cases, coagulation disorder resolved successfully after treatment with sirolimus.⁶ Wang et al. also reported a 12-year-old female with blue rubber bleb nevus syndrome and severe anemia who treatment with oral sirolimus markedly increased her hemoglobin from 2.8 g/dL to 6.7g/dL after treatment after one month.⁷ In another report, a 21-year-old man with anemia secondary to BRBNS was treated successfully with sirolimus. He displayed an excellent response to oral sirolimus and became free of transfusions.⁸

Rapid resolution of coagulopathy and increase in platelet count and hemoglobin after treatment with sirolimus, without any change in size and number of vascular lesions, supports adopting sirolimus as first-line drug of choice for treatment of venous malformations, especially when kasabach-merritt syndrome is present. In this condition successful resolution of coagulopathy was more than 90% and the median time to improvement was 13 days.^{9,10}

Our patient was an example of a responsive case of BRBNS with skin and gastrointestinal lesions in an adolescent who had not treated previously. He was planned to continue the treatment and refer for follow-up visits.

Conflict of Interest: None declared.

References

- Salloum R, Fox CE, Alvarez-Allende CR, Hammill AM, Dasgupta R, Dickie BH, et al. Response of blue rubber bleb nevus syndrome to sirolimus treatment. *Pediatr Blood Cancer*. 2016; 63(11):1911-4. doi:10.1002/pbc.26049. PubMed PMID: 27273326.
- Jin XL, Wang ZH, Xiao XB, Huang LS, Zhao XY. Blue rubber bleb nevus syndrome: A case report and literature review. *World J Gastroenterol* 2014; 20(45):17254–9. PubMed PMID: 25493043. PubMed Central PMCID: PMC4258599.
- Chinello M, Di Carlo D, Olivieri F, Balter R, De Bortoli M, Vitale V, et al. Successful management of kaposiform hemangioendothelioma with long-term sirolimus treatment: a case report and review of the literature. *Mediterr J Hematol Infect Dis*. 2018,10(1):e2018043. doi:10.4084/MJHID.2018.043. PubMed PMID: 30002799.
- Vignot S, Faivre S, Aguirre D, Raymond E. mTOR-targeted therapy of cancer with rapamycin derivatives. *Ann Oncol*. 2005; 16:525–37. doi: 10.1093/annonc/mdi113.
- Yesil S, Tanyildiz HG, Bozkurt C, Cakmakci E, Sahin G. Single-center experience with sirolimus therapy for vascular malformations. *Pediatr Hematol Oncol*. 2016;33(3):219-25. doi:10.3109/08880018.2016.1160170. PubMed PMID: 27128161.
- Zhang B, Li L, Zhang N, Zho M, Liu Y, Wei L, et al. Efficacy and safety of sirolimus in the treatment of blue rubber bleb naevus syndrome in paediatric patients. *Clin Exp Dermatol*. 2020;45(1):79-85. doi:10.1111/ced.14003. doi: 31074881.
- Wang KL, Shu-Fang MA, Pang LY, Zhang MN, Hu LY, Liu MJ, et al. Sirolimus alternative to blood transfusion as a life saver in blue rubber bleb nevus syndrome. *Medicine*.2018; 97(8):e9453. doi: 10.1097/MD.00000000000009453.
- Gil F, Serrano PL, Garcia EG. Successful management of anemia with sirolimus in blue rubber bleb nevus syndrome:case report and update. *Rev Esp Enferm Dig*. 2019;111(8):643-7. doi:10.17235/reed.2019.6250/2019. PubMed PMID: 31232079.
- Freixo C, Ferreira V, Martins J, Almeida R, Caldeira R, Rosa M, et al. Efficacy and safety of sirolimus in the treatment of vascular anomalies: A systematic review. *J Vasc Surg*. 2020;71(1): 318-327. doi: 10.1016/j.jvs.2019.06.217.
- Lee BB. Sirolimus in the treatment of vascular anomalies. *J Vasc Surg*. 2020;71(1):328. doi: 10.1016/j.jvs.2019.08.246.