



CASE REPORT

Metastatic Renal Cell Carcinoma to the Humerus Bone: A Report of Two Cases

Mazaher Ramezani¹, Farideh Baharzadeh¹, Homa Hadidi², Maryam Mirzaei¹, Masoud Sadeghi^{3,2*}

¹Molecular Pathology Research Center, Imam Reza Hospital, Kermanshah University of Medical Sciences, Kermanshah, Iran

²Students Research Committee, Kermanshah University of Medical Sciences, Kermanshah, Iran

³Medical Biology Research Center, Kermanshah University of Medical Sciences, Kermanshah, Iran

ARTICLE INFO

Article History:

Received: 10.01.2019

Accepted: 23.03.2019

Keywords:

Renal cell carcinoma

Metastasis

Bone

Humerus

*Corresponding author:

Masoud Sadeghi,
Medical Biology Research Center,
Kermanshah University of Medical
Sciences, Kermanshah, Iran.

Email: sadeghi_mbrc@yahoo.com

ABSTRACT

Renal cell carcinoma (RCC) is an aggressive malignancy which can metastasize to the bone. Long bones or the small bones of the limbs could be rarely the destinations for metastatic RCCs. We report two cases of metastatic RCC to the humerus bone with the initial presentation of pathological fracture. The pathologists must be aware of metastatic RCC to the arm and consider it in the differential diagnosis of any arm lesion with clear cell feature, whether there is a history of RCC or not. Complete clinical data and a history of the patient are of significant importance for pathologists to avoid unnecessary laboratory procedures.

Please cite this article as: Ramezani M, Baharzadeh F, Hadidi H, Mirzaei M, Sadeghi M. Metastatic Renal Cell Carcinoma to the Humerus Bone: A Report of Two Cases. IJBC 2019; 11(2): 69-71.

Introduction

Renal cell carcinoma (RCC) is an aggressive malignancy which accounts for almost 2–3% of the cancers in adults. RCC can metastasize to all parts of the body. Metastasis is seen in about 25% of the cases as the first manifestation or detected after tumor diagnosis. Lungs, lymph nodes, bone, liver, brain, and adrenal glands are the most prevalent sites of metastatic disease.¹⁻³ Bone metastasis is seen in about 20% of metastatic RCCs and the most commonly involved bones are the axial bones including pelvis, ribs, and spine. Rarely, long bones or the small bones of the limbs are destinations for bony metastases.⁴⁻⁸ Histological examination of these metastatic tumors may cause difficulty for pathologists.¹ Clear cell morphology is seen in different lesions.⁹ In the absence of a clinical history of primary tumor or using inappropriate immunohistochemistry, the correct diagnosis may be delayed.^{1,9} Herein, we report two patients with metastatic RCC to the arm involving humerus bone with the

presentation of pathological fracture. Informed consent was obtained from both patients during treatment.

Case Presentation

Case 1

A 56-year-old man was admitted to intensive care unit (ICU) with the chief complaint of respiratory distress where a left arm mass was also observed with evidence of pathological fracture of the humerus bone. The patient had a history of RCC 5 years ago for which he had undergone radical nephrectomy; however, the pathologist was not informed about it. He underwent surgery for the left arm mass. The specimen consisted of multiple pieces of gray-brown tissue measuring 4.5×4.5×3 cm. Microscopic examination demonstrated clear cells in a trabecular pattern (Figure 1).

The pathology was compatible with a metastatic carcinoma with clear cell features. CT angiography revealed massive bilateral pleural effusion mainly on

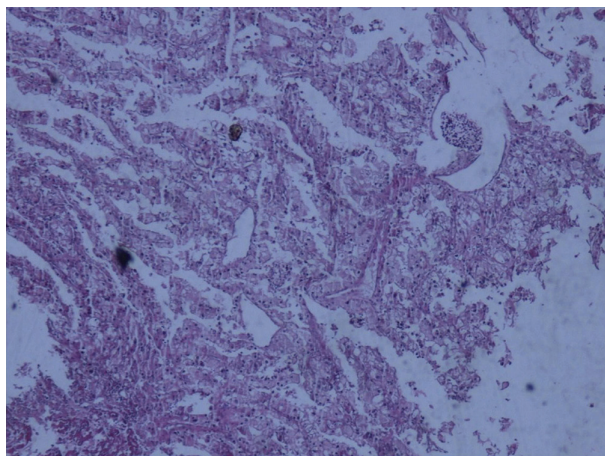


Figure 1: Metastatic renal cell carcinoma (Case 1); Hematoxylin-Eosin staining (×40 Magnification).

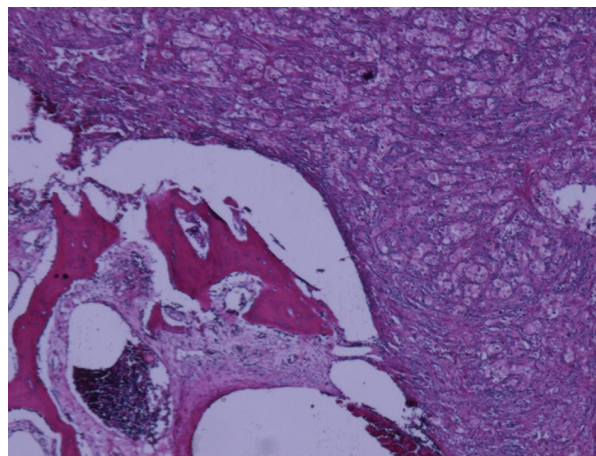


Figure 2: Metastatic renal cell carcinoma (Case 2); Hematoxylin-Eosin staining (×40 Magnification).

the right side, prominent pulmonary trunk, and multiple parenchymal pulmonary nodules in favor of metastasis and ground glass opacities in the right lung upper lobe. The patient was diagnosed as pulmonary thromboembolism following bone fracture along with pulmonary metastases considering his previous history of nephrectomy for RCC five years back. He underwent surgery for humerus bone fixation. The patient was intubated due to respiratory distress. However, he developed anuria and expired due to acute renal failure.

Case 2

A 50-year-old man was admitted to the oncology department with a history of RCC for evaluation of pulmonary symptoms and pathological fracture of the right humerus. Chest CT-scan demonstrated multiple alveolar mass-like opacities with air bronchogram in both lungs in favor of pulmonary metastasis. Third left rib and L1 vertebra metastases were also noted throughout the imaging. Surgery on the arm mass was performed. The specimen was consisted of several gray fragments totally measuring 4×3×2 cm. Histopathology was reported as metastatic clear cell carcinoma to the bone, compatible with metastatic RCC (Figure 2).

Discussion

RCC can metastasize to any part of the body and this potential is unpredictable.³ It is expected that RCC can metastasize after years of primary diagnosis, but most of the cases have a single site of metastasis.¹⁰ Metastatic RCC to the bone is mainly osteolytic that causes prominent morbidity and associated skeletal related events. Skeletal complications consist of pathological fracture, bone pain, hypercalcemia and nerve compression.⁶ These events have negative impression on quality of life and performance of the patient.^{1,6}

The most common skeletal problem is bone pain.⁶ Metastasis to the bones may be associated with other metastatic sites.⁹ Both of our cases had synchronous metastasis of lung and bone. Selvi and colleagues reported a 51-year-old man with clear RCC and 3 synchronous metastases to the maxillary gingiva, scalp, and distal phalanx of the fifth digit.⁴ In the study on 470 patients

with RCC, 19 (4%) patients had only bone metastasis, but 277 patients had concomitant metastases in other organs.¹¹ They found that higher number of metastatic sites, concomitant metastases, higher Fuhrman nuclear grade and non-clear cell histology are indicators of poor prognosis.¹¹ Good prognostic factors in metastatic RCC include single metastasis, younger age of the patient (less than 60 years at the time of metastasis) and longer disease-free interval (more than one year). In metastasis to the lungs, smaller metastatic deposits (less than 4 cm) have the better prognosis. Bone metastasis of kidney origin has better prognosis than lung origin, but these lesions have the best prognosis with origin from the breast or prostate. Early diagnosis and treatment are essential in order to prevent complications.⁶

Radiation can be palliative on the bone pain. Systemic chemotherapeutic agents are not beneficial for metastatic RCC. Surgery is the best modality of therapy in bone metastasis of RCC which is practically palliative. Two percent of the patients require surgery. Sunitinib (tyrosine kinase inhibitor) as a new therapeutic agent is used recently in metastatic RCC with increased disease-free survival and tolerable side effects.⁶

Conclusion

The pathologists must be aware of metastatic RCC to the bones and consider it in the differential diagnosis of any bone lesion with clear cell features, whether there is a history of primary RCC or not.

Acknowledgment

Mrs. Sholeh Akradi provided the documents that the authors thank her.

Conflict of Interest: None declared.

References

1. Badiu CD, Aungurenci A, Manea CA, Tomosoiu R, Chirca N, Rahnea-Nita G, et al. Axillary skin metastasis of renal cell carcinoma-Case report. *Int J Surg Case Rep.* 2017;34:74-76. doi: 10.1016/j.ijscr.2016.11.059. PubMed PMID: 28371635.
2. Chawla A, Mishra D, Bansal R, Chundru M. Rare

- sites of delayed metastasis in renal cell carcinoma. *BMJ Case Reports*. 2013;2013:bcr2013009971. doi: 10.1136/bcr-2013-009971. PubMed PMID: 23813515.
3. Goger YE, Piskin MM, Balasar M, Kilinc M. Unusual Presentation of Renal Cell Carcinoma: Gluteal Metastasis. *Case Rep Urol*. 2013;2013:958957. doi: 10.1155/2013/958957. PubMed PMID: 24392240.
 4. Selvi F, Faquin WC, Michaelson MD, August M. Three Synchronous Atypical Metastases of Clear Cell Renal Carcinoma to the Maxillary Gingiva, Scalp and the Distal Phalanx of the Fifth Digit: A Case Report. *J Oral Maxillofac Surg*. 2016;74(6):1286.e1-9. doi: 10.1016/j.joms.2016.01.054. PubMed PMID: 26954558.
 5. Farooq S, Nadaf A, Beigh A, Khuroo M, Bhat N, Nazir N. Metastatic lesions: A diagnostic dilemma-retrospective study, Srinagar, Jammu and Kashmir, India. *J Oral Maxillofac Pathol*. 2016;20(2):256–60. doi: 10.4103/0973-029X.185925. PubMed PMID: 27601819.
 6. Shankar K, Kumar D, Kumar KVV, Premata C. Renal Cell Carcinoma with Unusual Skeletal Metastasis to Tibia and Ankle: A Case Report and Review of Literature. *J Clin Diagn Res*. 2016; 10(11):XD01–XD02. doi: 10.7860/JCDR/2016/21946.8916. PubMed PMID: 28050490.
 7. Badri M, Gader G, Bahri K, Zammel I. Skull metastasis revealing a renal tumor: A case report and review of the literature. *Int J Surg Case Rep*. 2018;43:56-60. doi: 10.1016/j.ijscr.2018.01.025. PubMed PMID: 29453166.
 8. Asha M, Ibrahim H, Eisawi AK, Orme R, Houghton A. Steal phenomenon in the lower limb: presentation of a case with osseous metastases secondary to renalcell carcinoma and review of the literature. *BMJ Case Reports*. 2009;2009. pii: bcr08.2008.0609. doi: 10.1136/bcr.08.2008.0609. PubMed PMID: 21686724.
 9. Kumar RM, Aziz T, Jamshaid H, Gill J, Kapoor A. Metastatic renal cell carcinoma without evidence of a primary renal tumour. *Curr Oncol*. 2014;21(3):e521–e524. doi:10.3747/co.21.1914. PubMed PMID: 24940113.
 10. Ishak AI, MdPauzi SH, Masir N, Goh BS. Multiple Metastatic Deposits in the Head and Neck Region from a Renal Cell Carcinoma. *Malays J Med Sci*. 2010;17(4):71-4. PubMed PMID: 22135565.
 11. Santoni M, Conti A, Procopio G, Porta C, Ibrahim T, Barni S, et al. Bone metastases in patients with metastatic renal cell carcinoma: are they always associated with poor prognosis? *J Exp Clin Cancer Res*. 2015;34:10. doi: 10.1186/s13046-015-0122-0. PubMed PMID: 25651794.