



LETTER TO EDITOR

Acute Myeloblastic Leukemia with Multiple Extramedullary Relapses

Atakan Turgutkaya*, İrfan Yavaşoğlu, Ali Zahit Bolaman

Adnan Menderes University Hospital Hematology Division, Aytepe Location, Efeler, Aydın, Turkey

ARTICLE INFO

Article History:

Received: 03.11.2020

Accepted: 16.12.2020

*Corresponding author:

Atakan Turgutkaya
Adnan Menderes University Hospital
Hematology Division, Aytepe
Location, Postal code:09100, Efeler,
Aydın, Turkey
Tel: +90-256-4441256-2580
Fax: +90-256-2146687
Email:
atakanturgutkaya@yahoo.com.tr

Please cite this article as: Turgutkaya A, Yavaşoğlu İ, Bolaman AZ. Acute Myeloblastic Leukemia with Multiple Extramedullary Relapses. IJBC 2021; 13(1): 32-34.

Dear Editor

Extramedullary relapse is a rare event in acute myeloblastic leukemia (AML) in contrast to acute lymphoblastic leukemia (ALL) which is associated with bone marrow relapses and extramedullary relapses (EMR) due to sanctuary sites such as testis and central nerve system (CNS).¹ Only 2% of patients with AML with medullary relapse were detected to have coexistent testicular relapse, although this ratio is much higher as 30-70 % in autopsy series.^{1,2} Testicular relapse harbours systemic relapse and aggressive systemic and adjunctive local treatments such as radiotherapy (RT) need to be started appropriately; although there is not any worldwide determined algorithm for isolated EMR, yet.

Here we present an AML case who developed multiple EMRs after allogeneic stem cell transplantation (Allo-SCT). He was successfully managed with gemtuzumab ozogamicin (GO) plus local RT.

A 39-year-old man diagnosed AML, monoblastic/monocytic subtype according to the World Health Organisation 2016 classification was considered as standard risk for AML due to the absence of any cytogenetic abnormality or aberrant mutations. Flow cytometry analysis of the bone marrow showed CD 33 positivity (58%) and CD 56 negativity (1%). After remission induction and consolidation chemotherapy, he underwent Allo-SCT from his matched sibling donor (sister) with the busulfan-cyclophosphamide conditioning

regimen at 2017. During the follow-up, no graft versus host disease (GVHD) occurred and cyclosporine for GVHD prophylaxis was discontinued accordingly. Full donor chimerism (100%) was obtained at the end of the 3rd month after transplantation. After 27 months of Allo-SCT, he was admitted to hospital with new painless right testicular swelling. Scrotal ultrasound showed a 4 cm mass which required unilateral orchiectomy. Pathological examination and IHC study demonstrated 100 % CD34 positive blast involvement consistent with extramedullary relapse. Meanwhile, his blood counts were normal and bone marrow was free of relapse. Chimerism status of the bone marrow was re-evaluated which still showed 100% donor chimerism. CNS fluid examination showed no blast cells, supported by a negative flow cytometry result. In order to detect other potential extramedullary lesions, Position Emission Tomography (PET-CT) was performed and a 11x8x8 cm sized femoral mass was detected (figure 1a). The biopsy of the mass was in favour of involvement by myeloblasts. The patient performance status was very well and he had no sign of systemic involvement. The patient was planned to receive gemtuzumab ozogamicin (GO) and RT to the femoral mass. 28 Gy RT was given in 14 fractions in addition to 2 cycles of GO 3 mg/m² intravenously; monthly on days 1, 4 and 7. The femoral mass disappeared in MR imaging and control PET scans (figure 1b). GO treatment had to be interrupted due to overwhelming pneumonia and long-lasting neutropenia

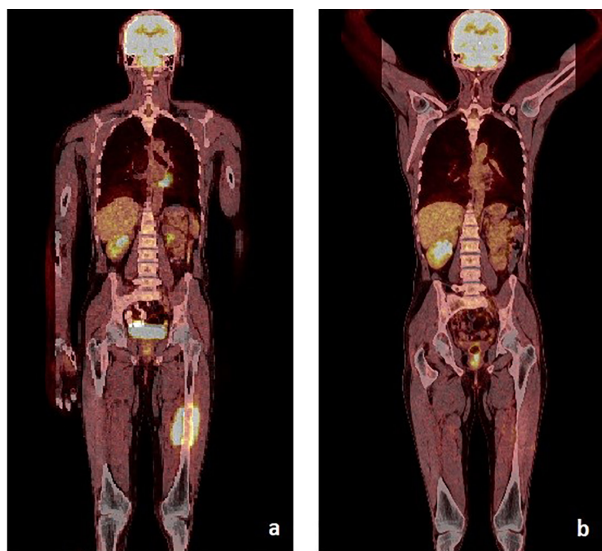


Figure 1: PET-CT images at initial EMR diagnosis (a) and after GO treatment (b).

for 2 months. However, 6 months later, a control PET scan showed a retroperitoneal 4 cm and left femoral 7 cm-sized new developing masses, again with no medullary involvement. fludarabine, high dose cytarabine (Ara-C), idarubicin and granulocyte-colony stimulating factor (FLAG-IDA) regimen was initiated at this time, so that complete resolution of the masses was achieved according to the control PET scan. Finally, he was planned to undergo the second SCT from his sister (the same donor) due to absence of any other suitable donor.

One of the suggested predictors for AML to present with extramedullary involvement is to have the features of monocytic/monoblastic or myelomonocytic subtype.¹ Also t (8; 21), inv (16) positivity, CD56 expression and relapsed/refractory disease at the time of the transplant are associated with increased risk of EMR.^{3,4} Chronic GVHD is considered to decrease relapse risk after SCT, but whether graft versus leukemia affect (GVL) also decreases the relapse rate is not well understood.⁵ Some data support the use of total body irradiation instead of busulfan in the conditioning regimen to decrease the risk of EMR.^{1,6} EMR may develop especially in central nervous system and reproductive organs due to inherent barriers which facilitates escaping from systematic chemotherapy.⁴ When EMR develops, the median time to marrow relapse is suggested to be around 7 months.⁴

The second SCT due to lack of effective therapeutic options can be considered for previously transplanted patients, but some studies report disappointing results and failure to eliminate EMR.^{3,7} There are also remarkable data supporting the benefit of single agent GO to treat EMR after Allo-SCT, since it doesn't suppress GVL effect.⁸ There is no standardized algorithm for new developing EMRs without medullary involvement while on GO therapy. Also, there is no definitive value of CD33 level at the time of diagnosis or during the appearance of EMR to predict response to GO. Regarding our patient, there was no aforementioned risk factor to develop EMR except having monoblastic/monocytic subtype. Donor lymphocyte infusion could be considered for our patient,

especially after detecting new extramedullary masses; but FLAG-IDA regimen was preferred, considering the resistant nature of the EMR and also to avoid GVHD with the fact that the patient had full donor chimerism. Informed consent was obtained from the patient for publication.

In this regard, GO-based approach with adjunctive RT is the reasonable option for isolated EMR after Allo-SCT, although it should be followed closely to detect progression or development of systemic relapse. Further studies are necessary to determine the most beneficial strategy for EMR.

Acknowledgement

The authors are pleased to acknowledge Dr Yakup Yürekli, (Prof of Nuclear Medicine Department, Adnan Menderes University, Aydın/Turkey) who provided PET-CT images for the article.

Conflict of Interest: None declared.

References

1. Lehman LE, Guinan EC, Halpernet SL, Donovan MJ, Bierer BE, Parsons SK. Isolated testicular relapse in an adolescent 5 years following allogeneic bone marrow transplantation for acute myelogenous leukemia. *Bone Marrow Transplant.* 1997; 19: 849–51. doi: 10.1038/sj.bmt.1700753. PubMed PMID: 9134181.
2. Mortimer J, Blinder MA, Schulman S, Appelbaum FR, Buckner CD, Clift RA. Relapse of acute leukemia after marrow transplantation: natural history and results of subsequent therapy. *J Clin Oncol.* 1989; 7(1): 50–7. doi: 10.1200/JCO.1989.7.1.50.
3. Clark WB, Strickland SA, Barrett AJ, Savani BN. Extramedullary relapses after allogeneic stem cell transplantation for acute myeloid leukemia and myelodysplastic syndrome. *Haematologica.* 2010; 95(6): 860–3. doi: 10.3324/haematol.2010.025890. PubMed PMID: 20513805. PubMed Central PMCID: PMC2878780.
4. Bakst RL, Tallman MS, Douer D, Yahalom J. How I treat extramedullary acute myeloid leukemia. *Blood.* 2011; 118(14):3785–93. doi: 10.1182/blood-2011-04-347229. PubMed PMID: 21795742.
5. Dang BN, De Oliveira S, Bowles L, Moore TB. Isolated Testicular Recurrence of AML in Patients With Chronic GVHD >1 Year Following Allogeneic Stem Cell Transplant. *J Pediatr Hematol Oncol.* 2017;39(8):e423–e425. doi: 10.1097/MPH.0000000000000989.
6. Blaise D, Maranichi D, Archimbaud E, Devergie A, Jouet JP, Milpied N, et al. Allogeneic BMT for acute myeloid leukemia in first remission: a randomized trial of a busulfan–cytoxan versus cytoxan–total body irradiation as preparative regimen. A report from the Groupe d'Etudes de la Greffe de Moelle Osseuse. *Blood.* 1992; 79(10):2578–82. PubMed PMID: 1586710.
7. Owonikoko T, Agha M, Balassanian R, Smith R, Raptis A. Gemtuzumab therapy for isolated

- extramedullary AML relapse following allogeneic stem-cell transplant. *Nat Clin Pract Oncol.* 2007;4(8):491-5. doi: 10.1038/ncponc0899. PubMed PMID: 17657254.
8. Ando T, Mitani N, Matsunaga K, Tatsuki N, Toshikazu G, Toshiaki Y, et al. Gemtuzumab ozogamicin therapy for isolated extramedullary AML relapse after allogeneic hematopoietic stem-cell transplantation. *Tohoku J Exp Med.* 2010; 220(2):121-6. doi: 10.1620/tjem.220.121.