

## CASE REPORT

# Erythrophagocytosis in Peripheral Blood Smear of a Patient with Urinary Tract Infection

Asra Amelirad<sup>1\*</sup>, Parisa Modarresi<sup>2</sup>, Farzad Abedi<sup>3</sup>, Hasan Soltani<sup>4</sup>

<sup>1</sup>Kowsar Medical Laboratory, Kowsar Hospital, Kurdistan University of Medical Sciences, Sanandaj, Iran

<sup>2</sup>Department of Pathology, Kowsar Hospital, Kurdistan University of Medical Sciences, Sanandaj, Iran

<sup>3</sup>Department of Urology, Kowsar Hospital, Kurdistan University of Medical Sciences, Sanandaj, Iran

<sup>4</sup>Public Health Laboratories Group, Vice Chancellor for Health Affairs, Kurdistan University of Medical Sciences, Sanandaj, Iran

## ARTICLE INFO

### Article History:

Received: 02.12.2021

Accepted: 17.02.2022

### Keywords:

Erythrophagocytosis  
Peripheral blood smear  
Urinary tract infection

### \*Corresponding author:

Asra Amelirad,  
Unit 1, Floor 1, No 11, Chamran Blvd,  
Postal code: 66187-45161, Sanandaj,  
Iran  
Tel: +98 9186604459  
Fax: +98 87 33629329  
Email: [asra.amelirad@gmail.com](mailto:asra.amelirad@gmail.com)

## ABSTRACT

Erythrophagocytosis refers to the removal of old and damaged red blood cells by leukocytes and macrophages. Observation of erythrophagocytosis in peripheral blood smear is a rare phenomenon that is mostly observed in paroxysmal cold hemoglobinuria and sporadically in some other pathological conditions. Here, we report a case of erythrophagocytosis by monocyte in peripheral blood of a patient with urinary tract infection.

Please cite this article as: Amelirad A, Modarresi P, Abedi F, Soltani H. Erythrophagocytosis in Peripheral Blood Smear of a Patient with Urinary Tract Infection. IJBC 2022; 14(1): 37-39.

## Introduction

More than  $10^{11}$  old red blood cells (RBCs) are removed from the human body every day. RBCs in the human body have a lifespan of 120 days under normal conditions. However, the lifespan of these cells is shortened due to damages caused by pathological changes. During the erythrophagocytosis process, aged and damaged red blood cells are detected and phagocytosed by resident macrophages in the spleen, liver, and bone marrow.<sup>1,2</sup> Degradation of erythrocytes in the bone marrow occurs under both normal and pathological conditions. In the microscopic examination of the bone marrow, the phenomenon of erythrophagocytosis has been observed in different conditions.<sup>3</sup> However, the observation of erythrophagocytosis in the peripheral blood smear is a rare phenomenon. It was first reported by Erlich in 1891<sup>4</sup> in the blood smear of patients with paroxysmal cold hemoglobinuria (PCH). After Erlich, the observation of erythrophagocytosis in the peripheral blood of patients

with PCH were reported by other researchers, so that erythrophagocytosis in peripheral blood has become an important finding in autoimmune hemolytic anemias and PCH.<sup>5-7</sup>

On the other hand, sporadic reports of observation of erythrophagocytosis by polymorphonuclear and mononuclear leukocytes in peripheral blood smears of patients with pathological conditions unrelated to PCH are also present. These reports include hemolytic anemia due to warm antibody, pernicious anemia, tuberculosis, G-CSF intake, quinine intake, spider bites, hematologic malignancies, potassium Chloride poisoning, neonatal hemolytic disease, and viral and bacterial infections.<sup>8</sup>

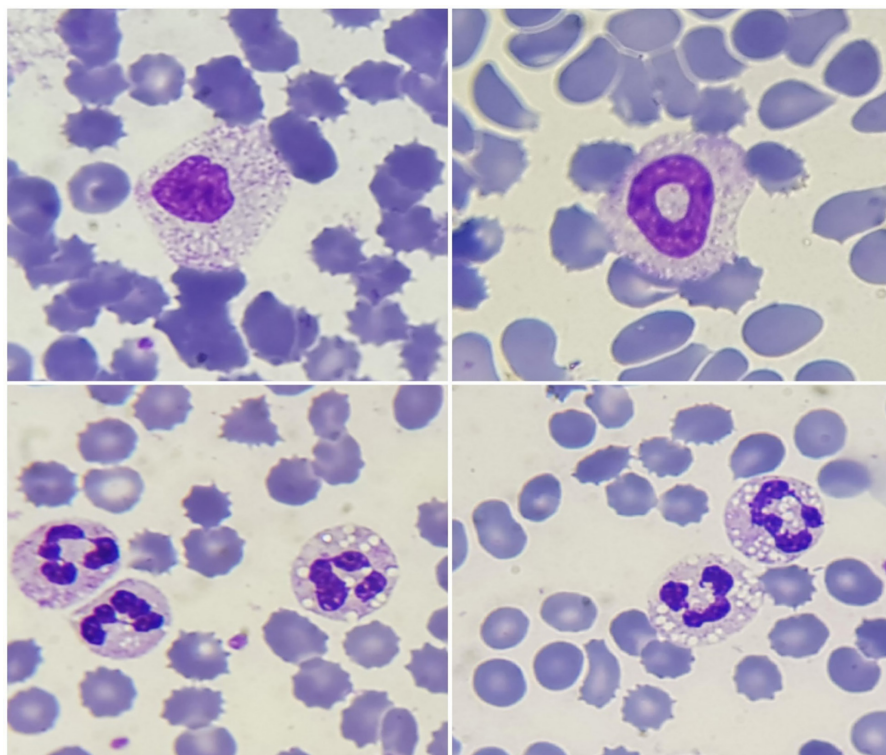
In this study, we report a case of erythrophagocytosis in a patient with urinary tract infection (UTI).

## Case Report

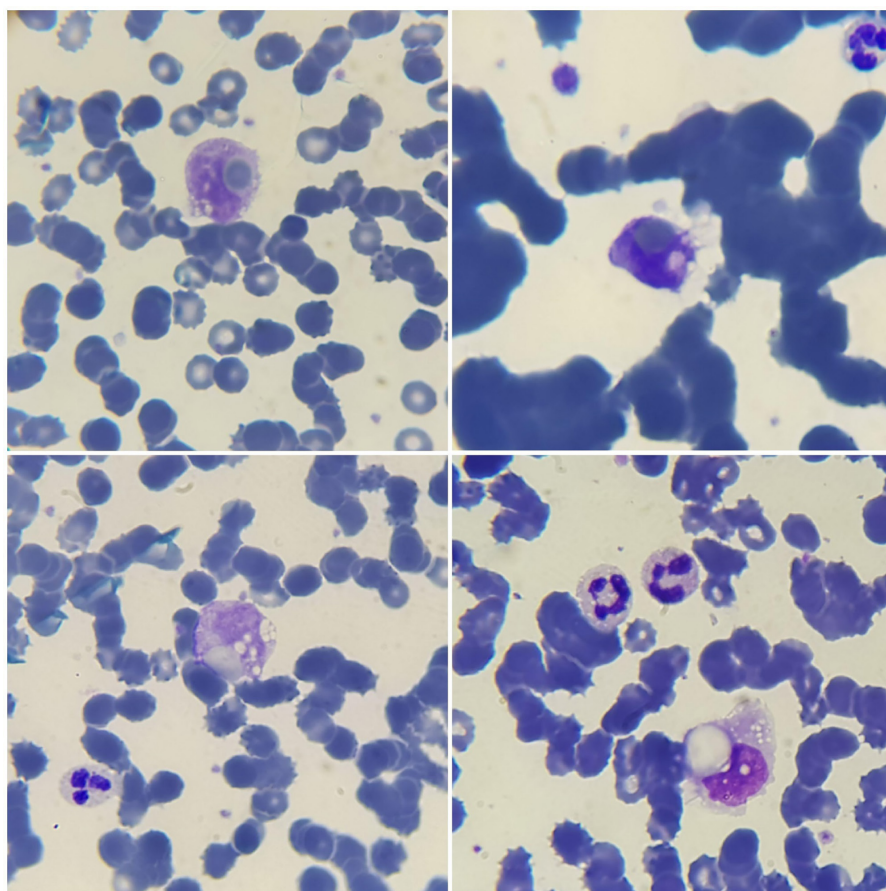
A 63-year-old man with a history of diabetes and COVID-19

who underwent open prostatectomy two weeks ago, referred to the emergency room with symptoms of fever, vomiting and chest pain. Chest CT scan of the patient was normal for COVID-19. Laboratory tests were in favor of urinary tract infection in addition to increased LDH (596 U / L), leukocytosis (WBC: 18300/mm<sup>3</sup>), mild anemia

(Hb: 11 g/dl) and thrombocytopenia (Platelet: 95000/mm<sup>3</sup>). Peripheral blood smear revealed bandemia (Band: 12%), morphological changes in neutrophils (Figure 1) and erythrophagocytosis by monocytes (Figure 2). In subsequent examinations, the results of the direct Coombs test and blood culture came to be negative.



**Figure 1:** Morphologic changes in neutrophils of the patient with UTI



**Figure 2:** Erythrophagocytosis by monocytes of the patient with UTI

The patient was admitted and was treated with intravenous meropenem and vancomycin for presumed UTI. He was discharged after 3 days with good conditions. In follow up tests, one month after discharge, the patient still had hematuria (RBC: 25-50) which was not far from expectation in a patient who had recently undergone open prostatectomy, but all other laboratory abnormalities were normalized.

### Discussion

Observation of erythrophagocytosis by leukocytes in peripheral blood smear is a rare phenomenon. Unlike erythrophagocytosis by neutrophils which is almost specific for PCH, erythrophagocytosis by monocytes can be caused by hemolytic anemias with various causes. Although direct Coombs test is positive in most cases of hemolytic anemia, in 5-10% of cases of hemolytic anemia direct Coombs is negative. Possible causes of Coombs-negative hemolytic anemia include lower sensitized RBC counts beyond the standard detection threshold, low affinity IgG, or binding of RBC to IgA or IgM.<sup>9</sup>

There have been reports of erythrophagocytosis in various viral, bacterial, and parasitic infections.<sup>10-12</sup> In 2018, Saranya Kodali and his colleagues reported granulocyte-induced erythrophagocytosis in a 39-year-old female patient with severe urinary tract infection and septicemia. The patient also had a severe urinary tract infection with toxic granulations in neutrophils.<sup>13</sup> In 2019, Zuhre Kaya and colleagues also reported erythrophagocytosis by monocytes in the peripheral blood smear of a 3-year-old boy with urinary tract infection receiving cefixime, suggesting that erythrophagocytosis may be due to the toxic effects of cefixime.<sup>10</sup> Our patient had also received cefixime to prevent infection after prostatectomy.

It should be noted that in addition to UTI, the patient had a history of Covid-19 disease during the past month. Many studies have reported various findings of covid-19 infection on blood cell count and morphology.<sup>14</sup> Therefore, with a lesser possibility, the observed erythrophagocytosis may be due to the residual effects of the Covid-19 infection.

In conclusion, since the association of anemia and infection has been reported in various studies, erythrophagocytosis can be considered as one of the possible causes of anemia in infectious processes. Despite all the advancements made in hematology analyzers, the diagnosis of erythrophagocytosis can only be made by examination of the peripheral blood smear. Moreover, peripheral blood smear examinations are not performed in most advanced laboratories, except in a limited number of cases, and many cases of this phenomenon may be ignored due to the lack of smear examination of the patients by experiences specialists.

### Ethical Consideration

Informed consent was signed by the patient. Ethics Code: IR.MUK.REC.1399.113

**Acknowledgment:** None.

**Conflict of Interest:** None declared.

### References

1. Arias CF, Arias CF. How do red blood cells know when to die? *Royal Society open science*. 2017;4(4):160850.
2. Pretini V, Koenen MH, Kaestner L, Fens M, Schiffelers RM, Bartels M, et al. Red Blood Cells: Chasing Interactions. *Front Physiol*. 2019;10:945.doi: 10.3389/fphys.2019.00945. PubMed PMID: 31417415. PubMed Central PMCID: PMC6684843.
3. Marton PF. Erythrophagocytosis in the human bone marrow. *Scand J Haematol*. 1970;7(3):177-83.doi: 10.1111/j.1600-0609.1970.tb01885.x. PubMed PMID: 5447963.
4. Dacie J. The haemolytic anaemias. Auto-immune haemolytic anaemia: Aetiology. 1992:363-91.
5. Garratty G. Erythrophagocytosis on the peripheral blood smear and paroxysmal cold hemoglobinuria. *Transfusion*. 2001;41(8):1073-4.doi: 10.1046/j.1537-2995.2001.41081073.x. PubMed PMID: 11493743.
6. Abt AF. Mononuclear erythrophagocytosis in the blood of a new-born infant. *American Journal of Diseases of Children*. 1931;42(6):1364-71.
7. Lewandowski K, Homenda W, Mital A, Complak A, Hellmann A. Erythrophagocytosis by neutrophils--a rare morphological phenomenon resulting in acquired haemolytic anaemia? *Int J Lab Hematol*. 2011;33(4):447-50.doi: 10.1111/j.1751-553X.2011.01312.x. PubMed PMID: 21418543.
8. Mukhopadhyay S, Keating L, Souid AK. Erythrophagocytosis in paroxysmal cold hemoglobinuria. *Am J Hematol*. 2003;74(3):196-7.doi: 10.1002/ajh.10438. PubMed PMID: 14587049.
9. Takahashi T. Direct Antiglobulin Test-Negative Autoimmune Hemolytic Anemia. *Acta Haematol*. 2018;140(1):18-9.doi: 10.1159/000489253. PubMed PMID: 30007988.
10. Kaya Z, Kürekçi F, Akkuzu E, Göral S, Kalkan G. Autoimmune hemolytic anemia, erythrophagocytosis and liver dysfunction after cefixime use for urinary tract infection in a child. *Indian Journal of Hematology and Blood Transfusion*. 2019;35(1):203-4.
11. Puigvi L, Baumann T, Fernandez S, Castro P, Pereira A, Merino A. Massive erythrophagocytosis by peripheral monocytes and neutrophils in parvovirus-B19 autoimmune hemolytic anemia. *Ann Hematol*. 2017;96(5):881-2.doi: 10.1007/s00277-017-2957-2. PubMed PMID: 28224193.
12. La Raja M. Erythrophagocytosis by peripheral monocytes in *Plasmodium falciparum* malaria. *Haematologica*. 2002;87(4):EIM14. PubMed PMID: 11940501.
13. Kodali S. Erythrophagocytosis in Sepsis. *Hematology & Transfusion International Journal*. 2018;6(6):232.doi: 10.15406/htij.2018.06.00190.
14. Rodriguez-Morales AJ, Cardona-Ospina JA, Gutierrez-Ocampo E, Villamizar-Pena R, Holguin-Rivera Y, Escalera-Antezana JP, et al. Clinical, laboratory and imaging features of COVID-19: A systematic review and meta-analysis. *Travel Med Infect Dis*. 2020;34:101623.doi: 10.1016/j.tmaid.2020.101623. PubMed PMID: 32179124. PubMed Central PMCID: PMC7102608.