Iranian Journal of Blood & Cancer

Iran J Blood Cancer, 2024, 16(2), 1-6
https://ijbc.ir

Case Report

BCR-ABL positive T cell Acute Lymphoblastic Leukemia (T-ALL): Exploring A Rare Case with A Comprehensive Review

Setare Kheyrandish[1], Shiva Shadani[2], Aziz Eghbali[2#], Behzad Poopak[3], Davood Bashash[4*]

[1]Student Research Committee, Department of Hematology and Blood Banking, School of Allied Medical Sciences, Shahid Beheshti University of Medical Sciences, Tehran, Iran.
[2]Clinical Research Development Center of Aliasghar Hospital, Iran University of Medical Sciences, Tehran, Iran.
[3]Department Of Medical Laboratory Sciences, Faculty of Paramedical Sciences, Tehran Medical Sciences, Islamic Azad University, Tehran, Iran.
[4]Department of Hematology and Blood Banking, School of Allied Medical Sciences, Shahid Beheshti University of Medical Sciences, Tehran, Iran.

Scan and read the article online

Citation Kheyrandish S, Shadani S, Eghbali A, Poopak B, Bashash D. BCR-ABL positive T cell acute lymphoblastic leukemia (T-ALL): exploring a rare case with a comprehensive review. Iran J Blood Cancer. 2024 June 30;16(2):1-6.

doi 0

Article info:
Received: 01 Mar 2024
Accepted: 22 Jun 2024
Published: 30 Jun 2024

Keywords:
P-190 BCR-ABL
Philadelphia
CD4$^+$/CD8$^+$ double-positive T-ALL
Malignancy

Abstract

CD4$^+$/CD8$^+$ double-positive (DP) thymocytes are normal cells within the thymus. However, the presence of mature DP T cells is indicative of cancer and abnormality in peripheral blood. Philadelphia$^+$ (Ph$^+$) T-ALL is extremely rare, but it holds significant therapeutic and prognostic implications. The incidence and outcomes of BCR-ABL$^+$ T-ALL remain uncertain, and distinguishing it from T-cell lymphoblastic crises of CML can be challenging. The current document discussed a rare case of CD4$^+$/CD8$^+$ BCR-ABL$^+$ T-ALL in an 11-year-old Iranian male, detailing his medical conditions, laboratory findings, and treatment. The patient presented with enlarged lymph nodes, splenomegaly, anemia, leukocytosis, and severe thrombocytopenia. The blood smear was nearly filled with irregular/convoluted and cleaved nuclear blasts with fine chromatin. The patient received imatinib with induction chemotherapy. After two months, the patient achieved complete remission with undetectable Minimal/Measurable Residual Disease (MRD). By detailing the patient's characteristics and the required tests, the manuscript contributes to a deeper understanding of this complex disease subtype. Furthermore, by examining and comparing the current case with other available cases, the study lays the groundwork for better characterizing the disease and developing more effective therapeutic strategies.

1. INTRODUCTION

Philadelphia chromosome-positive acute lymphoblastic leukemia (Ph$^+$ ALL) is a subtype of ALL distinguished by a specific chromosomal abnormality. This abnormality involves a reciprocal translocation between the ABL-1 oncogene on chromosome 9's long arm and a breakpoint cluster region (BCR) on chromosome 22's long arm, creating a fusion gene, BCR-ABL. This gene encodes an oncogenic protein with constantly active tyrosine kinase (TK) [1-3]. Depending on the specific breakpoint within the BCR gene that is fused with exon a2 of ABL, three different products are formed. The BCR-ABL fusion gene can

* Corresponding Authors:
Davood Bashash
E-mail: David_5980@yahoo.com

Aziz Eghbali
E-mail: aziz_eghbali@yahoo.com

[Downloaded from ijbc.ir on 2026-11-27]

[DOI: 10.61186/ijbc.16.2.1]

produce three different fusion proteins: p190, p210, or p230. The fusion genes of b2a2 and b3a2 are the most frequently observed fusion transcripts in CML [4]. The b2 and b3 are located between exons 13 and 14 or 14 and 15, respectively. This results in the formation of an abnormal 210-kD fusion protein (P210BCR-ABL), which plays an essential role in the malignant transformation of CML and contributes to phenotypic abnormalities. The introns 1 or 2 of the ABL gene can make two other different fusions: the first with the alternative BCR exons e2' and e2 of the minor breakpoint cluster region (m-BCR), forming a P190BCR-ABL (which is common in ALLs), and the second with the μ-BCR gene, located downstream between exons 17 and 20, leading to the production of a 230-kd fusion protein (P230BCR-ABL) which is linked to the uncommon Ph-positive chronic neutrophilic leukemia **(Figure 1)** [5-7]. P190BCR-ABL is linked to a poorer prognosis and is present in approximately 20% to 30% of adults diagnosed with ALL. Ph^+ ALL is more prevalent in older adults, with up to 50% of individuals aged 50 or older diagnosed with ALL. Patients with Ph^+ ALL encounter an increased risk of central nervous system (CNS) involvement [8]. The Philadelphia chromosome (Ph) is commonly linked to B-cell ALL in older adults containing 15% to 30% of B-ALL cases [9, 10]. It was first identified by a distinctive gene expression pattern in patients with very poor clinical outcomes and a high frequency of IKZF1 and other B-cell transcription factor deletions. Based on previous reports, malignancies characterized by the presence of Ph exhibit aggressive clinical presentations especially when the patient is presenting T-ALL. Ph^+ T-ALL/lymphoblastic lymphoma (LBL) is exceptionally rare, with a limited number of cases documented in the literature [11, 12]. Here, we documented a rare BCR-ABL^+/dual positive ($CD4^+$/$CD8^+$) T-ALL with de novo P190 BCR-ABL1 as a cytogenetic abnormality. Given the rarity of T-ALL associated with the Ph-positive (Ph^+), this cytogenetic abnormality's clinical significance, prognosis, and impact on leukemogenesis remain uncertain. This paper also aims to provide a comprehensive review of reported Ph^+ T-ALL cases, shedding light on the current understanding of this infrequent presentation and its implications.

2. CASE PRESENTATION

The patient is an 11-year-old Iranian male with several concurrent medical conditions, including enlarged mediastinal and cervical lymphadenopathy (2 cm in diameter) besides splenomegaly. Upon examination, the

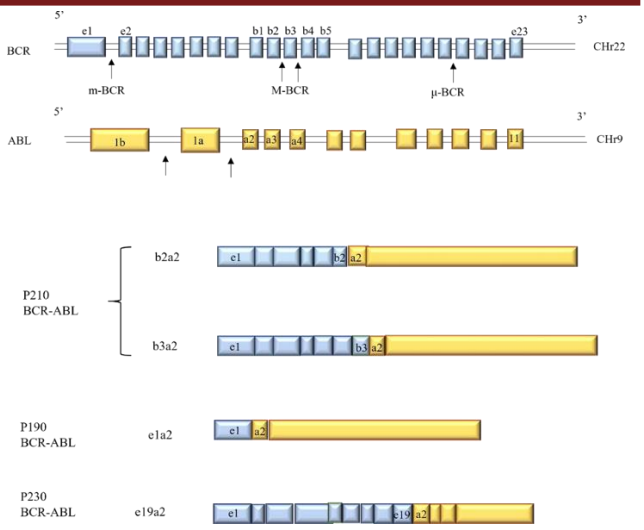

Figure 1. The specific locations of ABL and BCR gene breakpoints, as well as the structure of the resulting chimeric BCR/ABL mRNA transcripts.

patient appeared pale with bruising. He also presented with ecchymoses, petechiae, and purpura with no prior history of diseases. A complete blood count showed significant leukocytosis with a white blood cell count of $287 \times 10^3/mm^3$ (normal range: 4-10), mild microcytic hypochromic anemia with a hemoglobin level of 10.5 g/dL (normal range: 14–18), and severe thrombocytopenia with a platelet count of $15 \times 10^3/mm^3$ (normal range: 140-440). Peripheral blood smear analysis revealed anemia with some nucleated red blood cells (NRBCs) and schistocytes. There was marked leukocytosis with 91% blasts, some of which were medium to large with abundant cytoplasm, irregular/convoluted, and cleaved nuclear borders with fine chromatin **(Figure 2)**. Other cells like neutrophils (2%), lymphocytes (5%), monocytes (1%), and eosinophils (1%) were decreased significantly **(Figure 2A)**. In addition, the bone marrow aspirate exhibited a hypercellular sample with an abundance of immature lymphoid cells, the lymphoblasts. These cells exhibit a high nuclear-cytoplasmic ratio, scant cytoplasm, and irregular nuclear morphology with an open chromatin pattern and prominent nucleoli. The morphology is characteristic of T-cell ALL **(Figure 2B)**. The other pathological laboratory findings were: LDH 1545 U/L (normal range: <746), AST 288 U/L (normal range: 15-40), and ALT 55 U/L (normal range: 10-55). The patient's blood urea nitrogen (BUN) and creatinine levels fell within the normal range; However, the blood uric acid concentration was markedly elevated (8.6 mg/dL, normal range: 2.2-6.6). Flow cytometry on bone marrow aspirate showed an abnormal population of blasts expressing $CD45^{dim}$ 100%,

[Downloaded from ijbc.ir on 2026-11-27]

[DOI: 10.61186/ijbc.16.2.1]

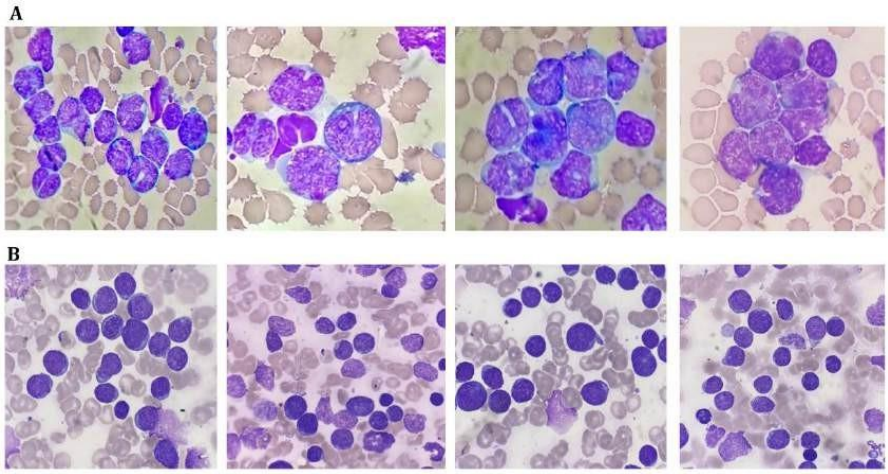

Figure 2. A) Peripheral blood smear (Giemsa stain) with irregular/convoluted and cleaved nuclear blasts. **B)** The patient's bone marrow aspirate demonstrates a hypercellular sample with a marked increase in immature lymphoblasts. These cells have a high nuclear-to-cytoplasmic ratio, scant basophilic cytoplasm, and a round to irregular nuclear shape with an open chromatin pattern. The nucleoli are prominent. The morphological features are consistent with a population of immature, proliferating T-lymphoid cells, characteristic of T-cell ALL.

CD1a 73%, CD2 98%, iCD3 64%, CD5 96%, CD7 96%, CD4 76%, CD8 96%, and dual CD4/8 60%. Other markers such as CD 33, 117, 14, 64, 19, and 20 were negative (**Figure 3A**). The RT-PCR analysis revealed the presence of a BCR-ABL1 e1a2 rearrangement, leading to the formation of a p190 protein. This fusion transcript type is frequently linked with de novo ALL. Cytogenetic analysis revealed a normal Karyotype: 46, XY compatible with a normal male. PB and BM findings were consistent with $CD4^+/CD8^+$ dual-positive T-ALL with t (9;22); BCR-ABL1 (Ph^+). He was started on imatinib at the day of diagnosis at 340 mg/m^2/day besides following the Children's Oncology Group (COG) protocol for treating T-ALL induction regimen including vincristine (1.5 mg/m^2), daunorubicin (25 mg/m^2), pegaspargase (Oncaspar®), and dexamethasone (3 mg/m^2/ dose BID). Following two months, the patient achieved a complete remission of his condition. Minimal/Measurable Residual Disease (MRD) in total cells was reported to be undetectable (**Figure 3B**).

3. DISCUSSION

Groffen et al. discovered a breakpoint on chromosome 22 within a 5.8 Kb region known as the BCR breakpoint, leading to the BCR-ABL fusion protein formation. The BCR protein characterized by a coiled-coil domain, promotes phosphorylation and activation. On the other hand, the ABL1 gene, located in the 9p34 band, contains alternative exons (1a, 1b) and a homology exon (from 2 to 10) within its 230 Kb region [13]. The ABL1 protein consists of three SRC homology domains (SH1, SH2, and SH3), with SH1 responsible for crucial TK activity essential for oncogenic transformation. On the other hand, SH2 and SH3 are engaged in facilitating protein-protein interactions and play pivotal roles in regulating and restraining the activation of ABL1, especially within signal transduction pathways. Importantly, the ABL1 protein does not impede apoptosis even under conditions of severe cellular stress [14, 15]. The m-BCR then results in the production of a 7 kb mRNA and p190 leading to the production of BCR-ABL1 tyrosine kinase. The constitutively active TK reduces the SHIP1 expression in a SHIP1-Y1021 phosphorylated-dependent manner with subsequent proteasomal degradation. The phosphatase SHIP1 is a crucial suppressor of the PI3K/AKT signaling cascade, frequently overactive in ALL. Notably, SHIP1 protein levels are reduced in most T-cell ALL cases [16]. The m-BCR breakpoint is observed in most Philadelphia -positive ALL (Ph^+ ALL) patients.[17].

To differentiate between the p210 and p190, we provided **Figure 4**. Generally, both mutations activate similar signaling pathways, for example such as the Ras-Ref-Mek pathway, leading to the production of Erk1/2. However, P210 uniquely triggers STAT 5 activation, whereas P190 typically activates adaptors such as DOK-1. Additionally, through AKT signaling, the Bad protein binds with the BCL-XL protein, promoting survival and anti-apoptotic actions. These and other pathways may explain the differing outcomes and prognosis between CML and ALL.

T-ALL is a highly aggressive and uncommon form of leukemia that affects individuals of all ages. It often presents with a notably elevated white blood cell count and/or a large

[Downloaded from ijbc.ir on 2026-11-27]

[DOI: 10.61186/ijbc.16.2.1]

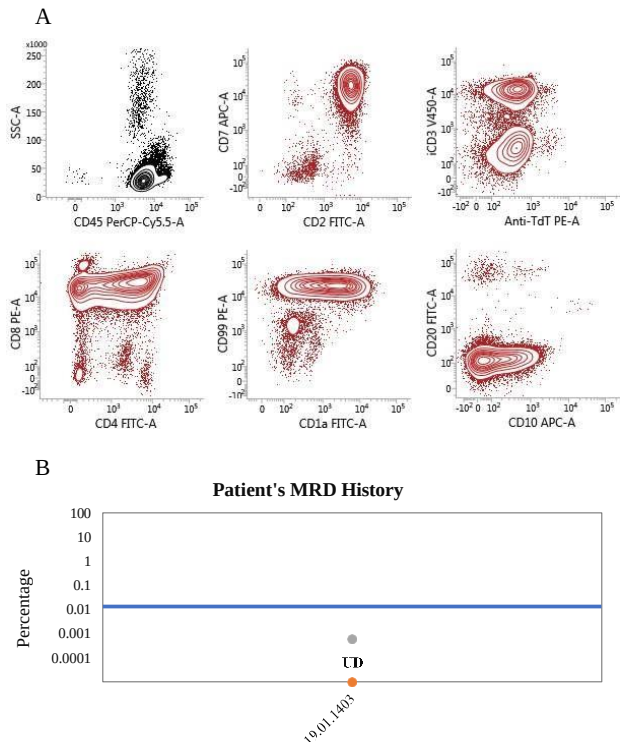

Figure 3. **A)** Immunophenotyping of Peripheral Blood by flow cytometry shows a mononuclear population (about 97% of the cells analyzed). These cells show expression of CD1a, CD2, iCD3, CD4, CD5, CD7, CD8, CD45, CD99 and they were negative for all other markers. **B)** This diagram indicates that the patient's minimal residual disease (MRD) levels became negative after two months (LLOD <0.0006%, LLOQ <0.002%).

mass in the mediastinum. In T-cell ALL, a significant portion of patients exhibit cytogenetic abnormalities; however, unlike B-cell ALL or acute myeloid leukemia (AML), no consistently recurring genetic abnormalities define the disease [18]. The accurate identification of T-ALL relies on the assessment of various CD markers expressed on the malignant cells. Particularly crucial in this regard is the evaluation of CD1a, CD2, iCD3, CD4, CD5, CD7, and CD8, which serve as reliable indicators of T-cell lineage. CD1a is a cell surface glycoprotein expressed on immature T-cells during the early stages of T-cell development. In T-ALL, CD1a positivity is an important marker for identifying the early T-cell precursor (ETP) subtype, which is associated with a poorer prognosis. The expression of CD1a helps distinguish T-ALL from other acute leukemias, making it a key diagnostic feature. Assessing CD1a aids in the classification and risk stratification of T-ALL subtypes, informing appropriate treatment approaches. CD2 is a surface glycoprotein expressed on mature T-cells and natural killer (NK) cells. The presence of CD2 is typically used in combination with other T-cell markers like iCD3 which is a reliable and specific indicator of T-cell differentiation and is crucial for the diagnosis of T-ALL. The assessment of CD4 and CD8 expression patterns is essential for the classification of T-ALL into distinct subgroups. Typically, the presence of CD4 or CD8 individually would aid in the delineation of helper or cytotoxic T-cell lineages, respectively. However, in the presented case of ours, the simultaneous positivity for both CD4 and CD8 suggests a more complex phenotypic presentation. This finding may indicate the presence of an immature or biphenotypic T-ALL subtype, which can pose additional challenges in terms of risk stratification and therapeutic decision-making. Similarly, CD5 and CD7, in conjunction with other T-cell markers, contribute to the comprehensive immunophenotypic characterization of T- ALL. Furthermore, the implementation of molecular techniques, such as the detection of BCR-ABL fusion transcripts, provides valuable diagnostic information. The presence of specific genetic aberrations, like the BCR-ABL fusion, can aid in the precise classification and risk stratification of T-ALL subtypes. Ph^+ T-ALL prevalence is limited to being documented in case reports, and this abnormality's clinical characteristics and prognostic significance remain largely unknown [12]. Lee et al. presented a unique situation of T-ALL with t (9;22) in a patient previously diagnosed with primary breast cancer. The interval between the breast cancer diagnosis and the onset of ALL was 4 years. The patient received treatment for breast cancer but later developed bone metastases, resulting in the coexistence of leukemic lymphoblasts and metastatic breast cancer cells in the bone marrow [19]. Identifying and diagnosing this condition can present significant challenges in some cases, often requiring a comprehensive approach by medical professionals as Dong et al. represented a 27-year-old man with worsening abdominal pain, leukocytosis, and thrombocytopenia. Imaging revealed several abnormalities and a peripheral blood smear showed blasts, leading to an initial diagnosis of AML. However, subsequent diagnosis indicated $BCR\text{-}ABL1^+$ acute leukemia with T-cell lymphoblastic leukemia and aberrant expression of CD33 and CD19. Fortunately, the case underwent chemotherapy and stem cell transplantation and was reported to be stable with no major issues [20]. BCR-ABL hybrid oncokinase protein is predominantly observed in CML, and typically, if CML progresses aggressively, it can transform into B-cell lymphoid lineage (20- 30% of cases), although the transformation into T-cell leukemia is exceedingly rare, but not impossible. A 56-year-old male with a history of hypertension, family history of Gaucher disease, and Ph^+ positive CML treated with imatinib for eight years,

[Downloaded from ijbc.ir on 2026-11-27]

[DOI: 10.61186/ijbc.16.2.1]

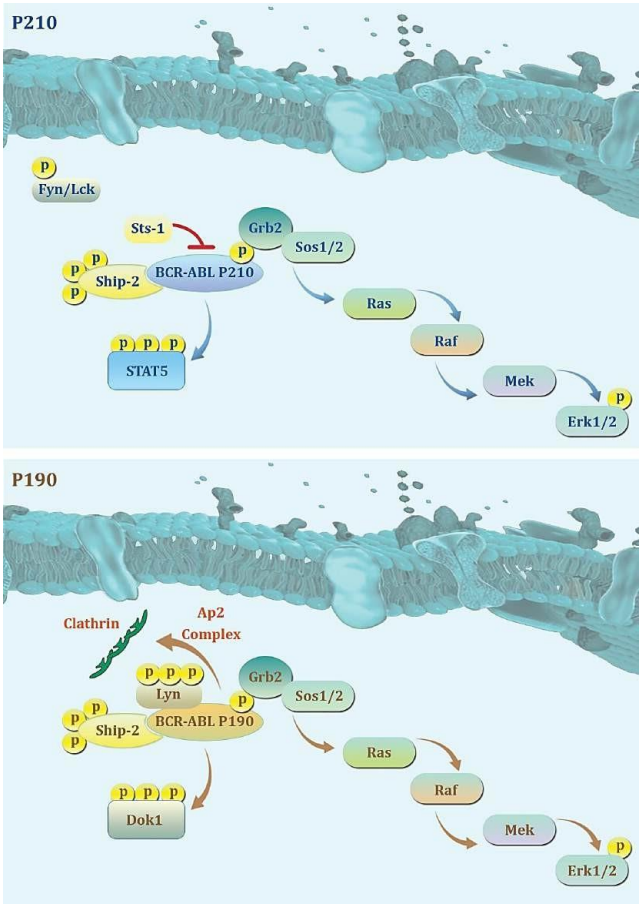

Figure 4. Model of differential signaling networks of p210 and p190 BCR–ABL.

presented with pancytopenia and lymphadenopathy. After blood transfusion, his hemoglobin remained low, with decreased platelet count and elevated monocyte and basophil percentages. Imaging showed pathological lymph nodes in the neck and chest, with no significant abnormalities in the lungs, mediastinum, or abdominal organs. The immunohistochemistry stains of his biopsy of the cervical lymph nodes revealed positive for CD3, CD5, BCL2, CD34, TdT. These histopathological findings were indicative of T-ALL. Subsequently, the patient received hyper- CVAD regimen A + B to achieve full remission as a bridge to allogeneic bone marrow transplant (BMT), while continuing Nilotinib at a dosage of 400 mg twice a day. Flow cytometry results then showed no indication of an elevated blast population in the bone marrow [21]. Through a review of the aforementioned cases, we found a predilection for the occurrence of T-ALL in males over females (**Figure 5**). The same was reported by Li et al. with 25 males and 5 females among 30 cases presented [22]. Lymphadenopathy and

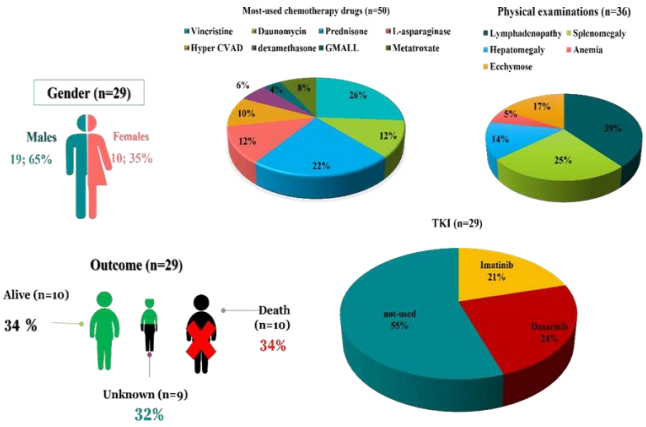

Figure 5. A summary of demographic data, physical examinations, the most-used drugs and outcomes of the cases.

splenomegaly has emerged as the most prevalent manifestations among affected individuals, although cases without splenomegaly have also been observed. The predominant-used chemotherapy regimen encompassed Vincristine, Prednisone, daunomycin, and L- Asparaginase. Despite the prevailing notion that the presence of BCR-ABL tyrosine kinase greatly heightens the likelihood of utilizing TKIs, it was only administered in half of the cases. Notably, studies employing Dasatinib as a TKI have yielded more positive treatment responses in the majority of cases, although it is important to accomplish further research to substantiate such findings. In terms of overall prognosis, the survival rates and mortality rates among patients have been equal. Lee and colleagues also reported that six patients received a treatment regimen comprising both chemotherapy and TKIs but the overall survival in all the cases was reported to be unfavorable (ranging from 0.1 to 60 months) [22]. **Figure 5** summarizes the available data about Ph^+ T-ALL cases. According to the literature, dual-positive Ph^+ T-ALL is a very rare disease. No possible data are available about this disease. Both a dual positive ($CD 4^+/8^+$) T-ALL and Ph^+ T-ALL generally show poor prognoses therefore differential diagnosis from CML and other leukemias are important.

4. CONCLUSION

The findings presented in the article shed light on the rare occurrence and clinical significance of Ph^+ T-ALL, highlighting the challenges associated with diagnosis and treatment due to limited documented cases. The discovery of de novo P190 BCR-ABL1 in dual positive ($CD4^+/CD8^+$) T-ALL with the Philadelphia chromosome raises uncertainties regarding prognosis and leukemogenesis, underscoring the need for further research to elucidate the implications of this cytogenetic abnormality on the

[Downloaded from ijbc.ir on 2026-11-27]

[DOI: 10.61186/ijbc.16.2.1]

aggressive nature of Ph^+ T-ALL and to facilitate the development of enhanced management approaches.

Acknowledgment

None.

Conflict of interest

The authors have no relevant conflict of interest.

References

1. Liu-Dumlao, T., et al., Philadelphia-positive acute lymphoblastic leukemia: current treatment options. Curr Oncol Rep, 2012. 14(5): p. 387-94.

2. Barnes, D.J. and J.V. Melo, Cytogenetic and molecular genetic aspects of chronic myeloid leukaemia. Acta haematologica, 2002. 108(4): p. 180-202.

3. Sampaio, M.M., et al., Chronic myeloid leukemia-from the Philadelphia chromosome to specific target drugs: A literature review. World journal of clinical oncology, 2021. 12(2):

p. 69.

4. Azad, N.A., et al., Prognostic implication of BCR-ABL fusion transcript variants in chronic myeloid leukemia (CML) treated with imatinib. a first of its kind study on CML patients of kashmir. Asian Pacific journal of cancer prevention: APJCP, 2018. 19(6): p. 1479.

5. Hazlehurst, L.A., et al., Signaling networks associated with BCR-ABL-dependent transformation. Cancer control : journal of the Moffitt Cancer Center, 2009. 16 2: p. 100- 7.

6. Iqbal, Z., A comprehensive analysis of breakpoint cluster region-abelson fusion oncogene splice variants in chronic myeloid leukemia and their correlation with disease biology. Indian J Hum Genet, 2014. 20(1): p. 64-8.

7. Romero-Morelos, P., et al., Frequencies of BCR::ABL1 Transcripts in Patients with Chronic Myeloid Leukemia: A Meta-Analysis. Genes (Basel), 2024. 15(2).

8. Raanani, P., et al., Philadelphia-chromosome-positive T-lymphoblastic leukemia: acute leukemia or chronic myelogenous leukemia blastic crisis. Acta Haematol, 2005. 113(3): p. 181-9.

9. Alshomar, A. and R. El Fakih, Philadelphia Chromosome-Positive T-cell Acute Lymphoblastic Leukemia: A Case Report and Review of the Literature. Hematol Oncol Stem Cell Ther, 2022. 15(1): p. 59-62.

10. Schrappe, M., et al., Philadelphia chromosome-positive (Ph+) childhood acute lymphoblastic leukemia: good initial steroid response allows early prediction of a favorable treatment outcome. Blood, The Journal of the American Society of Hematology, 1998. 92(8): p. 2730-2741.

11. Zhang, L., et al., Clinicopathologic characteristics, genetic features, and treatment options for acute lymphoblastic leukemia with JAK2 rearrangement—A 10-case study and literature review. Human Pathology, 2023. 136: p. 1-15.

12. Kohla, S., et al., P190 (BCR-ABL1) in a Patient with Philadelphia Chromosome Positive T-Cell Acute Lymphoblastic Leukemia: A Rare Case Report and Review of Literature. Case Rep Oncol, 2021. 14(2): p. 1040-1050.

13. Groffen, J., et al., Philadelphia chromosomal breakpoints are clustered within a limited region, bcr, on chromosome 22. Cell, 1984. 36(1): p. 93-99.

14. Wang, J.Y., Abl tyrosine kinase in signal transduction and cell-cycle regulation. Current opinion in genetics & development, 1993. 3(1): p. 35-43.

15. Kaveh, T., et al., < The> Role of BCR-ABL P190 in Diagnosis and Prognosis of ALL patients. 2015.

16. Ehm, P., B. Bettin, and M. Jücker, Activated Src kinases downstream of BCR-ABL and Flt3 induces proteasomal degradation of SHIP1 by phosphorylation of tyrosine 1021. Biochimica Et Biophysica Acta-Molecular Cell Research, 2023. 1870(5).

17. Adnan-Awad, S., et al., Characterization of p190-Bcr-Abl chronic myeloid leukemia reveals specific signaling pathways and therapeutic targets. Leukemia, 2021. 35(7): p. 1964-1975.

18. Marks, D.I. and C. Rowntree, Management of adults with T-cell lymphoblastic leukemia.

Blood, 2017. 129(9): p. 1134-1142.

19. Lee, S.G., et al., Therapy-related acute lymphoblastic leukemia with t(9;22)(q34;q11.2):a case study and review of the literature. Cancer Genet Cytogenet, 2009. 191(1): p. 51-4.

20. Dong, Q., et al., Philadelphia chromosome-positive T-cell acute lymphoblastic leukemia: a case report. J Int Med Res, 2024. 52(2): p. 3000605231156757.

21. Al-Janazreh, H., et al., An unusual case of T-cell acute lymphoblastic leukemia in a patient with BCR-ABL positive chronic myeloid leukemia and Gaucher disease. Annals of Medicine and Surgery, 2021. 68.

22. Li, X., et al., Case report: a case with Philadelphia chromosome positive T-cell lymphoblastic lymphoma and a review of literature. Frontiers in Oncology, 2021. 10: p. 584149.

[Downloaded from ijbc.ir on 2026-11-27]

[DOI: 10.61186/ijbc.16.2.1]