Iranian Journal of Blood & Cancer

Iran J Blood Cancer, 2024, 16(3), 8-13
https://ijbc.ir

Case Report

Management of Hypoxia in the Simultaneous Presentation of Sickle Cell Trait and Cystic Fibrosis. Exploring a Rare Case with a Comprehensive Review

Seyed Ahmad Tabatabaii [1], Neda Entezari Farahabadi [1,*]

[1] *Department of Pediatric Pulmonology, Mofid Pediatrics Hospital, Shahid Beheshti University of Medical Sciences, Tehran, Iran.*

Scan and read the article online

Citation Tabatabaii SA, Entezari Farahabadi N. Management of hypoxia in the simultaneous presentation of Sickle cell trait and cystic fibrosis. Exploring a rare case with a comprehensive review. Iran J Blood Cancer. 2024 Sep 30;16(3): 8-13.

doi 0

Article info:
Received: 13 Aug 2024
Accepted: 23 Sep 2024
Published: 30 Sep 2024

Keywords:
Cystic fibrosis
Sickle cell trait
Hypoxia

Abstract

Background: Cystic fibrosis (CF) is an inheriting disorder that has a strong impact on the pulmonary systems of individuals, as a result, hypoxia might be presented among patients who have CF. In addition, hypoxia is a pathological condition that might be present among patients with sickle cell trait (SCT). However, the simultaneous presentation of both SCT and CF in a patient is rare.

Case presentation: A 7-year-old boy came to the hospital with a chief complaint of cyanosis and cough. In his physical examination, he has low SpO2. His fiber-optic bronchoscopy depicted purulent secretion in the main bronchus. As well, his sweet chloride test was above 80 mmol/L. Thus, by the impression of CF exacerbation, he got HARD treatment and antibiotics. Additionally, during hospitalization, SCT as another impression was diagnosed for him.

Conclusion: Although the co-existence of CF and SCT is rare among patients. The physicians must consider both CF and SCT when a child comes to the emergency room with hypoxia.

.

1. INTRODUCTION

Cystic fibrosis is a hereditary disorder that impacts both the respiratory and digestive systems. One common complication of CF is hypoxia, which occurs when the body does not receive enough oxygen. This can stem from factors such as inflammation and lung infections, as well as the thick, sticky mucus that blocks the airways in CF patients. Hypoxia can lead to symptoms such as difficulty breathing, fatigue, and bluish skin discoloration (1, 2). Hypoxia in cystic fibrosis arises from lung damage and reduced lung function, leading to insufficient blood oxygenation. Managing hypoxia in cystic fibrosis involves both preventive measures and the treatment of acute episodes (3). Overall, the management of hypoxia in cystic fibrosis requires a comprehensive approach that includes preventive measures to maintain lung function and prompt treatment of acute episodes to optimize oxygenation and prevent further lung damage. Close monitoring of lung function and prompt intervention are crucial in managing hypoxia in individuals with cystic fibrosis (4). Sickle Cell trait (SCT) is a chronic blood disorder characterized by red blood cells' abnormal, rigid sickle shape. This shape reduces the flexibility of the cells, leading to an increased risk of health complications. The sickling is caused by a mutation in the hemoglobin gene (4). This mutation in the hemoglobin (Hb) gene causes

* **Corresponding Author:**
Neda Entezari Farahabadi
Affiliation: *Department of Pediatric Pulmonology, Mofid Pediatrics Hospital, Shahid Beheshti University of Medical Sciences, Tehran, Iran.*
E-mail: **neda93farahabadi@gmail.com**

[Downloaded from ijbc.ir on 2026-11-27]

[DOI: 10.61186/ijbc.16.3.8]

severe and potentially life-threatening complications, including hemolytic anemia, inflammation, reduced immunity to encapsulated pathogens, and blood vessel blockage (5). Cystic fibrosis (CF) and sickle cell trait (SCT) are associated with both acute and chronic pulmonary complications. Although rare, the co-occurrence of CF and hemoglobinopathy in inheritance is relatively uncommon. However, physicians must take both conditions into account when a child presents to the emergency room with hypoxia.

2. CASE PRESENTATION

The 7-year-old boy presented at the hospital with complaints of cyanosis, low SPO2, coughing, and noisy breathing. The patient has a history of two hospitalizations with the same complaint since two years ago. He was hospitalized for two weeks, received antibiotic treatment, and was discharged. He also underwent HRAD treatment. The patient was the first child in the family, gestational age: 36 weeks, with a birth weight of 3 kg. The patient's weight gain was good until the age of 5 years, but for the past 2 years, the patient's weight gain has been disrupted. During hospitalization, the patient underwent a course of intensive treatment for cough and wheezing, but it had no effect. As a result of a drop in SPO2, the patient was admitted to the hospital for bronchoscopy. The patient underwent a fiber optic bronchoscopy, which revealed purulent secretion in the main bronchus. Following the bronchoscopy, the patient was requested to undergo a sweat test and a stool test. Additionally, due to a drop in SpO2, a venous blood gas (VBG) test was requested for the patient during sleep (see **Tables 1** and **2**). After the patient experienced cyanosis during CF exacerbation episodes, we decided to initiate CF treatment. However, a few weeks into the treatment, the patient had more episodes of cyanosis, which prompted us to investigate other potential causes. This was unexpected as we did not anticipate hypoxia and cyanosis in the early stages of CF. The sweat test was repeated for the patient (Sweat Chloride = 90). Tests for thromboembolism were performed, and all results were normal. A CT angiography of the thoracic aorta was also conducted, and the result was reported as normal. Additionally, an echocardiogram with contrast was performed and found to be normal. An ultrasound of the abdomen, liver, spleen, and pancreas was performed, and the results came back normal. Additionally, a lung perfusion/ventilation scan was carried out, and the result showed no signs of pulmonary thromboembolism (PTE) or right to left shunt. However, evidence of cephalization was noted, indicating increased pulmonary artery pressure Finally, the patient's hemoglobin electrophoresis showed Hb S, D, G=51%, Hb A=45%, Hb F=0.5%, and Hb A2=3.2% (**Table 3**). After the hematology consult, a capillary zone Hb electrophoresis was requested for the patient, and the result is as follows: According to the above data, sickle trait anemia was also diagnosed for the patient. Finally, the patient was diagnosed with a sickle cell crisis, which can also occur after a CF exacerbation. This condition is relatively rare and is reported in the literature.

3. LITERATURE REVIEW

Both sickle cell trait and cystic fibrosis are passed down through an autosomal recessive inheritance pattern. The β-globin gene cluster is located on chromosome 11, while the CFTR gene is present on chromosome 7. In typical situations, it's unlikely for these two conditions to be inherited simultaneously. The combination of cystic fibrosis and sickle cell anemia (CF and SS) is considered a rare disorder (6, 7). The coexistence of sickle cell trait (SCT) and cystic fibrosis (CF) in a single patient is extremely rare due to their distinct genetic origins and pathophysiology. Our case study emphasized the importance of managing hypoxia and providing care to patients with both of these genetic disorders. We searched Google Scholar, Scopus, and PubMed databases and found fewer than two studies related to our study. The case involves a 2-year-old African-American girl who has been diagnosed with hereditary cystic fibrosis and β+ sickle cell thalassemia. She experienced significant blood-related issues during periods of worsening lung problems associated with cystic fibrosis, along with weight loss. Tests showed that her lung function was moderately to severely obstructed in the lower airways, with moderate air trapping and no signs of restrictive lung disease (8). Other previously documented cases involve a specific group of five patients who have both cystic fibrosis and hemoglobinopathy (9-12).

4. DISCUSSION

In previous reports, the patient's lung function was relatively well-preserved. In our case, however, the patient presented with complaints of cyanosis and lung involvement. Surprisingly, the lung function was ultimately found to be maintained, consistent with the findings of previous reports. Additionally, it's worth noting that pulmonary and hematological complications did not occur simultaneously. The simultaneous occurrence of pulmonary and hematological complications is influenced by multiple factors and may be attributed to a combination of physiological effects (12). Hypoxia in individuals with CF

[Downloaded from ijbc.ir on 2026-11-27]

[DOI: 10.61186/ijbc.16.3.8]

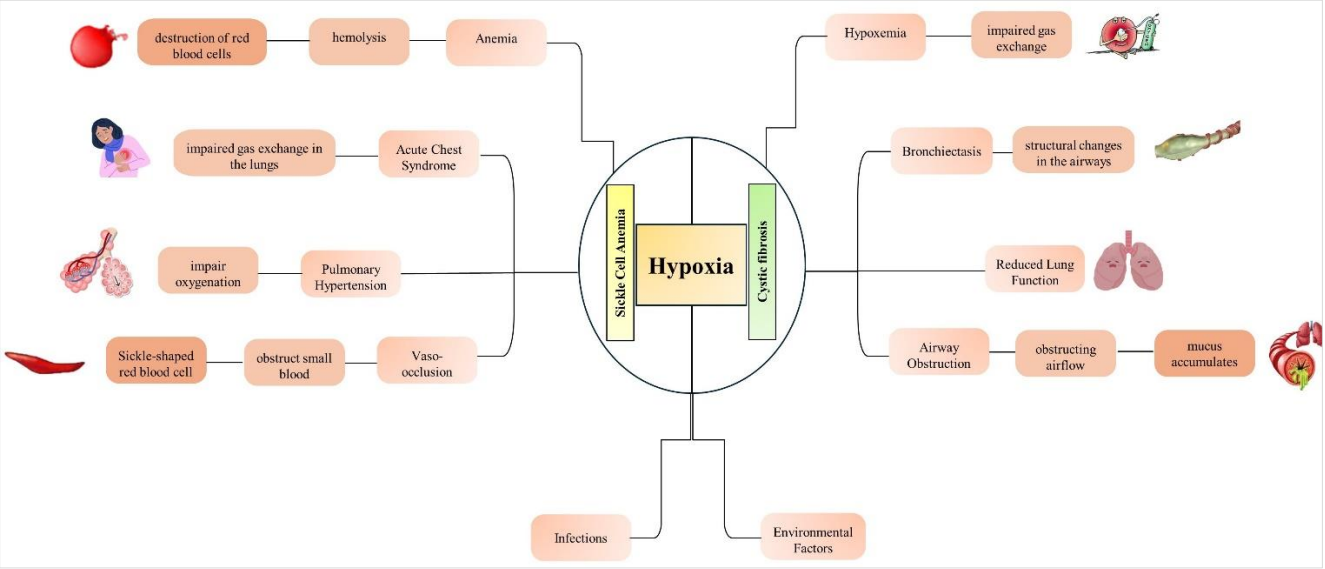

Figure 1. The process of hypoxia in the context of concurrent Cystic Fibrosis (CF) and Sickle Cell Trait.

Table 1. Test results obtained from the patient.

Hematology	Biochemistry	Coagulation	VBG	Immunoglobulin
WBC= 4.6	Na= 142	PT= 15.5	PH= 7.47	IgM= 140
Hb= 11.5	K=2.7	PTT=29	PCO2= 31	IgA= 133
PLT= 417		INR=1	HCO3= 17	Ig E= 337
			VBG	IgG=843
				NBT= 100

Table 2. Paraclinical measures performed for the patient.

Barium swallow test	Normal
Sweat Test	Above 80 mmol/L
Sputum culture	Normal floras
Bronchoscopy	Clear secretions in trachea, purulent secretions in RMB, adenoid hypertrophy
BAL Culture	Negative
VBG during Sleep	PH= 7.28 Pco2= 34 HCO3= 16
Cardiology consult	Normal anatomy, small PFO, good LV Function
Abdominal sonography	Normal
Spirometry	FEV1= 107 FEV1/FVC= 91 FVC= 122 FEF=71 FEF25%= 76 FEF 50%= 77 FEF 75%= 59

is thought to be caused by the mucus blockage of small airways, leading to a mismatch in ventilation/perfusion (V/Q). In contrast, the majority of children with sickle cell disease do not experience hypoxia when their condition is stable (13). Hypoxia in sickle cell trait raises the likelihood of irreversible sickling, which can result in partial pulmonary embolism or acute chest syndrome (14). Individuals with sickle cell disease who have had acute chest syndrome often experience increased hypoxia during sleep, increasing their risk of further blood vessel blockages (14, 15). A patient with both cystic fibrosis and sickle cell disease may be at an elevated risk for irreversible sickling and pulmonary complications due to the hypoxia associated with cystic fibrosis. This increased hypoxia could lead to the development of severe pulmonary disease at an earlier age compared to individuals with either condition alone. Given these factors, it may be prudent to consider a chronic transfusion regimen for patients who have both cystic fibrosis and sickle cell disease to help manage and mitigate these complications_(15). Amendola reported a case involving a 9-year-old African American child who has cystic fibrosis, along with a distinctive combination of sickle cell

[Downloaded from ijbc.ir on 2026-11-27]

[DOI: 10.61186/ijbc.16.3.8]

Table 3. Hb electrophoresis and capillary zone electrophoresis of the patient

Hb electrophoresis	Hb A 45 %	Hb F 0.5%	Hb S.D.G 51 %	Hb A2 3.2 %
Capillary zone electrophoresis	Hb A 58 %	Hb F 0.5 %	Hb S 37 %	Hb A2 3.5 %

hemoglobin and hemoglobin D-Punjab disease. The child started receiving transfusions at the age of one because her pulmonary disease was progressing rapidly. At the time of the report, her pulmonary disease was similar to that of other children with cystic fibrosis of the same age (10). The cases of two African American children, a 22-month-old and a 7-year-old, who were diagnosed with both cystic fibrosis and sickle cell anemia (hemoglobin SS disease) was documented (9). It appeared that neither child had experienced a worsening of one condition that affected the other. The third report described an adolescent of both Black and Hispanic heritage from the Dominican Republic who had both diseases. This patient had normal pulmonary function tests and remained stable while on cephalexin prophylaxis and using inhaled albuterol, with no noticeable complications. The unexpected coexistence of sickle cell disease and cystic fibrosis raises significant questions about how both conditions impact each other and how they can be effectively managed in a single child. Specifically, does sickle cell disease have a positive or negative impact on the progression of cystic fibrosis? Additionally, in what ways does cystic fibrosis affect the progression of sickle cell disease? None of the four previously reported cases in the literature have shown any negative effects from this co-occurrence.

5. CONCLUSION

The simultaneous occurrence of cystic fibrosis and sickle cell disease in a single patient is a rare phenomenon, with only a handful of reported cases globally. This combination has not previously been documented in the Iranian population. It is crucial to raise awareness about the possibility of both diseases coexisting, especially since sickle cell disease is commonly seen in pediatric clinics. Emphasis should be placed on screening for the presence of cystic fibrosis, particularly in patients with sickle cell disease who experience recurrent chest infections. Although having both conditions may not impact disease progression, affected patients will need multiple medications and careful monitoring.

Acknowledgment

The authors would like to thank all the people who contributed to the writing of this article.

Conflict of interest

The authors declared no conflict of interest.

Ethical statement

There was no ethical consideration to be considered in this research. The patient's information was confidential, and this consent was obtained during the investigation.

References

1. Rafeeq MM, Murad HAS. Cystic fibrosis: current therapeutic targets and future approaches. J Transl Med. 2017;15(1):84.

2. De Boeck K. Cystic fibrosis in the year 2020: A disease with a new face. Acta Paediatr. 2020;109(5):893-9.

3. Bergeron C, Cantin AM. Cystic Fibrosis: Pathophysiology of Lung Disease. Semin Respir Crit Care Med. 2019;40(6):715-26.

4. Montgomery ST, Mall MA, Kicic A, Stick SM. Hypoxia and sterile inflammation in cystic fibrosis airways: mechanisms and potential therapies. Eur Respir J. 2017;49(1).

5. Rees DC, Williams TN, Gladwin MT. Sickle-cell disease. The Lancet. 2010;376(9757):2018-31.

6. Beaudet AL, Perciaccante RG, Cutting GR. Homozygous nonsense mutation causing cystic fibrosis with uniparental disomy. American journal of human genetics. 1991;48(6):1213.

7. Spence J, Perciaccante R, Greig G, Willard H, Ledbetter D, Hejtmancik JF, et al. Uniparental disomy as a mechanism for human genetic disease. American journal of human genetics. 1988;42(2):217.

8. Sobush KT, Thornburg CD, Voynow JA, Davis SD, Peterson-Carmichael SL. A 2-year-old girl with co-inherited cystic fibrosis and sickle cell-β+ thalassemia presenting with recurrent vaso-occlusive events during cystic fibrosis pulmonary exacerbations: a case report. J Med Case Rep. 2013;7:203.

9. Porter RC, Cloutier MM, Brasfield DM, Mangos JA, Miale T, Tiller RE. Cystic fibrosis in two black children with sickle cell anemia. 1979.

10. Amendola G, Garvin J, Piomelli S. Cystic fibrosis in a black child with hemoglobin SD disease. Journal of Pediatric Hematology/Oncology. 1990;12(3):340-2.

11. Warwick AB, Haver K, Rosoff PM. Homozygous sickle cell disease and cystic fibrosis in an adolescent. Pediatric pulmonology. 1998;26(3):224-7.

12. Banjar HH. Cystic fibrosis: presentation with other diseases, the experience in Saudi Arabia. Journal of Cystic Fibrosis. 2003;2(3):155-9.

13. Needleman JP, Franco ME, Varlotta L, Reber-Brodecki D, Bauer N, Dampier C, et al. Mechanisms of nocturnal

[Downloaded from ijbc.ir on 2026-11-27]

[DOI: 10.61186/ijbc.16.3.8]

oxyhemoglobin desaturation in children and adolescents with sickle cell disease. Pediatric pulmonology. 1999;28(6):418-22.

14. D'Aloya N. Sleep related upper airway obstruction and hypoxaemia in sickle cell disease. Archives of Disease in Childhood. 1993;68(5):715.

15. Samuels MP, Stebbens VA, Davies SC, Picton-Jones E, Southall DP. Sleep related upper airway obstruction and hypoxaemia in sickle cell disease. Archives of Disease in Childhood. 1992;67(7):925-9.

[Downloaded from ijbc.ir on 2026-11-27]

[DOI: 10.61186/ijbc.16.3.8]