Iranian Journal of Blood & Cancer

Iran J Blood Cancer, 2024, 16(3), 1-7
https://ijbc.ir

Case Report

Mesenteric Vein Thrombosis (MVT) as the Cause of Abdominal Pain in Pediatric Cystic Fibrosis (CF): A Case Report

Arya Behzadi [1], Pooya Poormehr [1], Nazanin Farahbakhsh [2*]

[1] School of Medicine, Shahid, Beheshti University of Medical Sciences, Tehran, Iran.
[2] Department of Pediatric Pulmonology, Mofid Pediatrics Hospital, Shahid Beheshti University of Medical Sciences, Tehran, Iran.

Scan and read the article online

Citation Behzadi A, Poormehr P, Farahbakhsh N. Mesenteric vein thrombosis (MVT) as the cause of abdominal pain in pediatric cystic fibrosis (CF): A case report. Iran J Blood Cancer. 2024 Sep 30;16(3): 1-7.

doi 0

Article info:
Received: 31 July 2024
Accepted: 23 Sep 2024
Published: 30 Sep 2024

Abstract

Background: Cystic fibrosis (CF) represents a prevalent autosomal recessive condition that predominantly impacts the respiratory and gastrointestinal systems. Abdominal pain in patients with cystic fibrosis is commonly linked to conditions including distal intestinal obstruction syndrome, pancreatitis, or hepatic disease. This case report presents a rare etiology of abdominal pain, specifically mesenteric vein thrombosis (MVT) attributed to hereditary thrombophilia, observed in a pediatric patient diagnosed with cystic fibrosis (CF).

Case Presentation: A 3-year-old female patient with a confirmed diagnosis of cystic fibrosis, established through a sweat chloride test, exhibited significant right lower quadrant (RLQ) abdominal pain. The initial diagnostic evaluation, comprising an abdominal series, laboratory assessments, and abdominal ultrasound, ruled out prevalent etiologies including DIOS, pancreatitis, and appendicitis. The presence of persistent pain necessitated additional diagnostic evaluation through a contrast-enhanced CT scan, which subsequently identified mesenteric vein thrombosis. The analysis of genetic testing revealed a homozygous mutation in the MTHFR C677T gene, which is suggestive of hereditary thrombophilia. These findings were corroborated through Sanger sequencing methodologies.

Conclusion: This case highlights the importance of evaluating uncommon conditions such as mesenteric vein thrombosis in pediatric patients with cystic fibrosis who exhibit atypical abdominal pain. An extensive diagnostic strategy, incorporating genetic analysis, is crucial for the prompt identification and focused intervention necessary to avert significant complications. Abdominal pain is a significant clinical symptom that may be associated with various underlying conditions, including cystic fibrosis, venous thrombosis, and mesenteric ischemia. Each of these conditions presents unique challenges in diagnosis and management, necessitating a comprehensive understanding of their pathophysiology and clinical implications.

Keywords:
Abdominal Pain
Cystic Fibrosis
Venous Thrombosis
Mesenteric Ischemia

[Downloaded from ijbc.ir on 2026-11-27]

[DOI: 10.61186/ijbc.16.3.1]

* Corresponding Author:
Nazanin Farahbakhsh
Affiliation: *Department of Pediatric Pulmonology, Mofid Pediatrics Hospital, Shahid Beheshti University of Medical Sciences, Tehran, Iran.*
E-mail: **naznin26farahbakhsh@gmail.com**

1. INTRODUCTION

Cystic fibrosis (CF) represents the most common Mendelian autosomal recessive disorder among Caucasians, marked by a considerable reduction in life expectancy (1). The etiology of this condition is attributed to genetic modifications in the cystic fibrosis transmembrane conductance regulator (CFTR) gene. The gene in question encodes a protein that plays a critical role in the transport of chloride ions across the membranes of epithelial cells. Mutations in the CFTR gene disrupt the regulation of chloride and sodium ion transport, leading to the production of thick mucus in various organs, notably the respiratory and digestive systems (2). Viscous secretions are associated with an increased risk of sinopulmonary infections, pancreatic insufficiency, diabetes, venous thromboembolism (VTE), and liver disease. Airway infection and inflammation are defining characteristics of cystic fibrosis (CF) and represent the principal determinants of morbidity and mortality in individuals affected by this condition (3,4).

Cystic fibrosis affects not only the respiratory system but also leads to various gastrointestinal symptoms that are essential for the diagnosis, prognosis, and overall health of individuals impacted by the disease. No text was provided by the user. Cystic fibrosis (CF) has the potential to affect multiple regions of the gastrointestinal tract, including pancreatic insufficiency, gastroesophageal reflux disease, hepatic disorders, and conditions that influence the large intestine. Distal intestinal obstruction syndrome (DIOS) is a prevalent gastrointestinal complication associated with cystic fibrosis (CF) and often manifests with clinical symptoms that resemble those of appendicitis. The clinical manifestations observed encompass abdominal pain, bloating, bilious vomiting, the presence of a palpable mass, and challenges in the passage of stool or flatus. The incidence of gastrointestinal cancers is increasing within the cystic fibrosis population, attributed to the prolonged lifespans of patients (5–7). The identification of the etiology of abdominal pain in pediatric patients diagnosed with cystic fibrosis (CF) presents a complex clinical challenge. Cystic fibrosis is associated with a diverse array of gastrointestinal complications and exhibits a multifaceted nature, which complicates the diagnostic process (8). The determination of the specific etiology of abdominal pain in patients with cystic fibrosis is a complex endeavor, requiring a thorough assessment of the pain's localization and its clinical manifestation (9). The presence of comorbidities and atypical gastrointestinal symptomatology introduces additional complexity to the diagnostic process (10).

Imaging plays a crucial role in the identification of abdominal manifestations associated with cystic fibrosis, particularly in the diagnosis of cystic fibrosis-related hepatic disease (8).

Acute superior mesenteric vein thrombosis (SMV) represents a significant gastrointestinal complication associated with cystic fibrosis (CF). This condition is characterized by clinical manifestations including colicky abdominal pain, nausea, anorexia, vomiting, and diarrhea. The duration of these symptoms typically does not exceed 4 weeks; however, some individuals may remain asymptomatic. In specific cases, this may lead to bowel infarction, which is identified by symptoms including fever, peritonitis, or hemodynamic instability. In these instances, timely intervention is essential (6).

Thrombus formation in individuals with cystic fibrosis is attributed to the recurrent administration of intravenous antibiotics, necessitating the utilization of implanted ports and peripherally inserted central catheters (PICC) (3). Thrombus formation in cystic fibrosis is mediated by multiple mechanisms, including the activation of platelets (11) and the deficiency of protein C and protein S (6). The occurrence of a defective CFTR protein results in the secretion of altered pro-inflammatory mediators, including IL-17, alongside pro-resolution mediators within the eicosanoid pathway (12). Other cell types, including neutrophils, macrophages, and T lymphocytes, are similarly affected by the failure of CFTR (12). Alongside infections that stimulate the expression of tissue factors, these mechanisms serve as the principal contributors to the initiation of the body's inflammatory response, thereby activating the coagulation cascade (3).

This case report details a 3-year-old female patient diagnosed with cystic fibrosis (CF) who was admitted to our facility presenting with abdominal pain as her primary complaint. Abdominal pain is a common symptom observed in individuals diagnosed with cystic fibrosis (CF), largely attributable to the various gastrointestinal (GI) complications linked to the condition, including pancreatic insufficiency, gastroesophageal reflux disease, and liver disease (5,6). In the present case, we identified mesenteric vein thrombosis as the underlying cause of the abdominal pain, a rare condition that may complicate the diagnostic process and management strategies for abdominal pain in patients with cystic fibrosis (6).

[Downloaded from ijbc.ir on 2026-11-27]

[DOI: 10.61186/ijbc.16.3.1]

2. CASE PRESENTATION

The subject of this case study is a 3-year-old female who received a diagnosis of cystic fibrosis during infancy, confirmed via a sweat chloride test. Throughout her lifetime, she experienced multiple episodes of pneumonia and underwent continuous antibiotic therapy. The patient was referred to Mofid's Children Hospital for evaluation of her abdominal pain. The patient reported experiencing severe abdominal pain localized to the right lower quadrant (RLQ). Furthermore, the mother articulated her apprehension regarding her child's reduced appetite. The patient's bowel habits were noted to be regular, with no reported symptoms of diarrhea, constipation, or dysentery from the mother. The patient's parents did not furnish any medical history pertaining to diabetes or other health conditions. During the evaluation, it was observed that the patient demonstrated failure to thrive (FTT) and presented with a weight that was considerably below the expected range for her age. Upon conducting the abdominal examination, tenderness and rebound tenderness were observed in the right lower quadrant (RLQ) region of the abdomen. In order to validate our hypotheses regarding the potential diagnoses of appendicitis, DIOS, DKA, peritonitis, or pancreatitis in the patient, we performed an array of laboratory assessments. These included measurements of amylase and lipase levels, a complete blood count (CBC), a basic electrolyte panel, venous blood gas (VBG) analysis, blood sugar (BS) evaluation, ultrasonography, and coagulation studies comprising prothrombin time (PT), partial thromboplastin time (PTT), and international normalized ratio (INR), along with an abdominal series. The tests were conducted to validate the precision of our preliminary hypotheses. The findings demonstrated that the abdominal series, blood glucose levels, venous blood gas analysis, amylase, lipase, complete blood count, and metabolic panel fell within the established normal parameters. In summary, we have excluded DIOS and DKA as possible diagnoses for the patient under consideration. Additionally, the abdominal ultrasound findings were negative for appendicitis, hepatitis, or peritonitis. Given the ongoing pain that showed no improvement following 48 hours of admission and the inadequate response to standard analgesics, we suspected that maybe the reason behind the severe pain in our patient is ischemia caused by a vascular abnormality or occlusion. So we decided to perform an abdominal CT scan with Intravenous contrast and D Dimer to more precisely determine the source of the abnormality. The D Dimer test result was 600 (maximum normal range: 200). Furthermore, the computed tomography scan demonstrated the existence of a thrombus within the mesenteric vein of the patient, leading to abdominal pain attributable to ischemia secondary to diminished blood flow (see **Figures 1** and **2**). Subsequent to the administration of anticoagulant therapy, genetic testing was conducted to investigate the etiology of the patient's thrombosis and assess her for potential hereditary thrombophilia. Also, we measured the levels of homocysteine levels to pinpoint the exact etiology more accurately. The result of the homocysteine test was 36 µmol/L with the maximum normal range of up to 30 (confirming hyperhomocysteinemia in our patient). The results of the genetic testing demonstrated that the patient presents with hereditary thrombophilia. The subject exhibited identical mutations in the C677T gene, characterized by a T/T genotype (see **Table 1**). The validation of genetic testing results was achieved through Sanger sequencing. It is important to note that all assessments detailed in this report were performed following the acquisition of consent from the patient's parents, subsequent to a thorough explanation of the associated risks, benefits, and procedures involved. The results of the genetic testing were communicated exclusively to the parents of the patient in question.

Table 1. The table presents the genetic analysis results for our case report, detailing the genotypes for three specific polymorphisms: Factor II (G20210A), MTHFR C677T, and MTHFR A1298C. The individual is homozygous for the wild type (GG genotype) for the Factor II (G20210A) polymorphism, homozygous for the T/T mutation in the MTHFR C677T polymorphism, and homozygous for the wild type (A/A genotype) for the MTHFR A1298C polymorphism.

Explored Mutation	Factor II (G20210A)	MTHFR C677T	MTHFR A1298C
Statue	Wild type homozygous (GG genotype)	Homozygous mutation (T/T genotype)	Wild type homozygous (A/A genotype)[1]

3. DISCUSSION

This case report examines atypical causes of abdominal pain in pediatric patients diagnosed with cystic fibrosis. Identifying the underlying cause of abdominal pain is a critical step in formulating an effective treatment strategy for these patients. Abdominal pain in patients with cystic

[Downloaded from ijbc.ir on 2026-11-27]

[DOI: 10.61186/ijbc.16.3.1]



Figure 1. The sagittal view of CT scan with contrast of our patient showing filling defect in mesenteric vein confirming the diagnosis of thrombosis with a red oval.

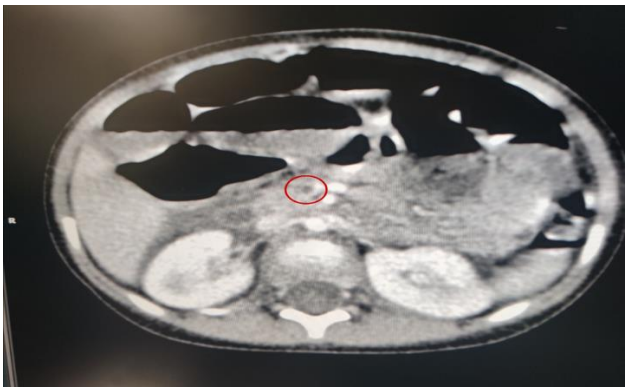

Figure 2. The same CT scan with contrast of the patient in the transverse view highlighting the filling defect confirming mesenteric vein thrombosis with a red circle.

fibrosis is primarily attributed to distal intestinal obstruction syndrome, pancreatitis, and liver damage (5,6). This case report holds considerable importance as it reveals that, contrary to our initial hypotheses, the patient's abdominal pain was not linked to the previously identified etiologies. The condition's etiology was identified as mesenteric vein thrombosis (MVT), a complication arising from thrombophilia. Mesenteric venous thrombosis (MVT) is associated with significant morbidity and mortality, leading to complications such as bowel ischemia and peritonitis. This case underscores the importance of evaluating hereditary thrombophilia as a potentially rare etiology for abdominal pain. This information may encourage healthcare practitioners to implement timely interventions and engage in evidence-based decision-making concerning the optimal therapeutic approach (13).

A comprehensive analysis has identified over 2000 mutations within the CFTR gene, each of which has implications for the phenotypic manifestations observed in patients (1). The F508del mutation represents the predominant variant, accounting for more than 70% of cystic fibrosis cases (14). Additionally, documentation regarding the P5L mutation has been reported from Spain (15). Additional mutations, including SCNN1A and SCNN1B, may result in symptomatology akin to that observed in cystic fibrosis patients. The identified mutations have a significant impact on the functionality of the ENaC channel (16).

The management of SMV thrombosis in the population affected by cystic fibrosis is complicated by the existence of an underlying prothrombotic condition and an increased risk of bleeding associated with cystic fibrosis and cystic fibrosis-related liver disease (6). The management of the condition involves the oral administration of pancreatic enzymes, alongside the incorporation of microelements and potentiators, including ivacaftor, to improve the chloride conductance of CFTR. Furthermore, pharmacological agents such as lumacaftor, tezacaftor, and lumacaftor are employed to enhance the folding and trafficking processes associated with CFTR mutations, particularly the F508del variant. Moreover, compounds such as ataluren are utilized to enhance CFTR translation (1,17).

The relationship between CF and coagulopathy is complex and requires further investigation. Patients with cystic fibrosis exhibit an increased susceptibility to thrombophilia (18). McGivern et al. (2013) report that there is no observed impairment in platelet aggregation or P-selectin expression, both of which are essential for proper platelet function (19). The pulmonary environment in patients diagnosed with cystic fibrosis (CF) promotes the establishment of Pseudomonas aeruginosa colonization and sustains neutrophil viability, consequently resulting in the onset of chronic inflammatory processes (20). Mitochondrial calcium signaling plays a critical role in the heightened inflammatory response observed in cystic fibrosis, wherein flagellin from Pseudomonas aeruginosa induces the activation of the NLRP3 inflammasome, leading to the production of interleukin-1β (21). It is noteworthy that various conditions, such as cystic fibrosis, are associated with an increased risk of venous thromboembolism due to inflammation (22). Ex-vivo investigations of platelets

[Downloaded from ijbc.ir on 2026-11-27]

[DOI: 10.61186/ijbc.16.3.1]

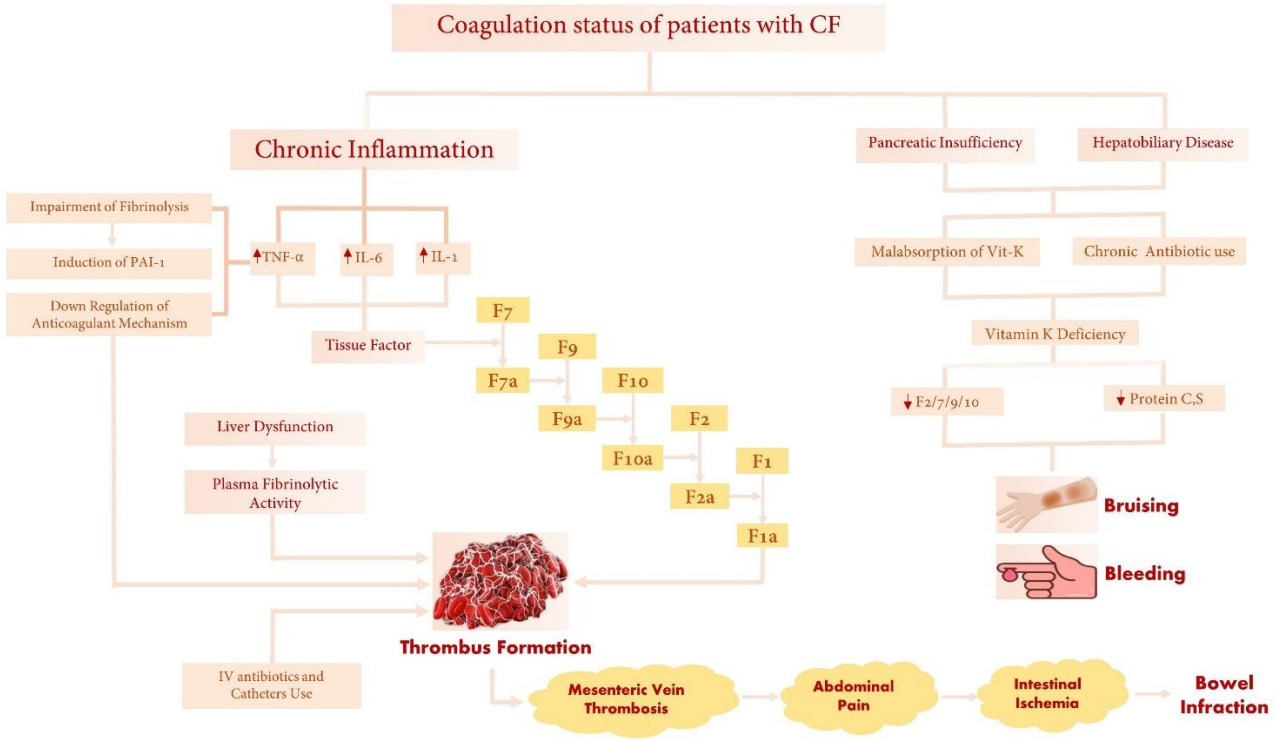

Figure 3. This diagram illustrates the pathways leading to coagulopathy and abdominal pain in cystic fibrosis (CF).

derived from individuals diagnosed with cystic fibrosis (CF) demonstrate an elevation in CD62P activity, which is not accompanied by a proportional increase in GPIIb/IIIa levels. Furthermore, while there is an increase in the platelet-monocyte complex, there is no corresponding elevation in the platelet-neutrophil complex. Furthermore, the inhibition of CFTR on platelets results in a reduction of lipoxin A4 (LXA4) synthesis, an essential anti-inflammatory mediator that plays a significant role in modulating inflammation during interactions between platelets and monocytes (11). Furthermore, Lindberg et al. documented an association between platelet activation and BPI-ANCA, also known as anti-neutrophil cytoplasmic antibodies (11). In individuals diagnosed with cystic fibrosis, hepatic impairment may result in diminished levels of anticoagulant proteins, including protein C and S, thereby contributing to the development of thrombophilia (6). In patients with cystic fibrosis, the incidence of thrombosis is elevated as a consequence of impaired vitamin K absorption, a critical factor in the synthesis of anticoagulant proteins including protein C, protein S, and antithrombin III (18). Research indicates a heightened vulnerability to venous thromboembolism (VTE) among pediatric patients diagnosed with cystic fibrosis (CF) (3). Following comprehensive laboratory evaluations and imaging studies to rule out pancreatitis and bowel obstruction, CT angiography revealed the presence of superior mesenteric vein thrombosis. Consequently, the initiation of anticoagulant therapy for the patient was undertaken without delay.

Similar instances have been recorded in the existing body of literature. In a study conducted by Scott (2020), a case was presented involving a 51-year-old individual. Alongside genetic mutations, such as Phe508del/Phe508 in certain instances and the C677T gene with T/T in our cases, additional variations were observed among the subjects. The subject in this case did not present any clinical manifestations indicative of diabetes, cirrhosis, constipation, hemoptysis, or hepatic encephalopathy. Nevertheless, despite these differences, certain similarities were observed. Both patients were referred to medical facilities for evaluation and management of severe, persistent abdominal pain. Additionally, the abdominal CT scan corroborated that the pain reported by both patients was linked to the development of a thrombus in the mesenteric vein (6).

A study conducted by Balfour-Lynn et al. determined that a considerable percentage of children diagnosed with cystic fibrosis exhibit a thrombophilia abnormality. This finding may play a role in the heightened risk of thrombosis

[Downloaded from ijbc.ir on 2026-11-27]

[DOI: 10.61186/ijbc.16.3.1]

observed in these patients, especially in the context of utilizing percutaneous long lines and implantable venous access devices (TIVADs) (23).

A study conducted by Williams et al. reported a significant increase in the incidence of lupus anticoagulants, as well as reductions in protein C and protein S levels among pediatric patients with cystic fibrosis when compared to the general population. The observed elevation in thrombophilic tendency did not correlate with any particular cystic fibrosis phenotype and was improbable to be exclusively attributable to hepatic dysfunction.

Notwithstanding the observable thrombophilic propensity, the study period did not yield any clinically significant thrombotic events, which stands in contrast to findings reported in several other studies within the existing literature (24).

The results indicate an increased propensity for thrombosis and coagulopathy among patients with cystic fibrosis, highlighting the necessity for further research into this complex phenomenon. Healthcare professionals must remain aware of this potential risk when assessing alternative diagnoses for abdominal pain. **Table 2** presents a summary of the review of literature in this section. **Figure 3** displays a diagram of the relationship between different factors that CF leads to abdominal pain due to thrombophilic tendency.

Acknowledgment

We would like to express our sincere gratitude to the patient and her family for their cooperation and consent and to the founders of Mofid children's hospital for provision of advanced diagnostic paraclinical tests, which made this case report possible.

Conflict of interest

The authors declare that they have no conflict of interests.

Funding

The authors confirm independence from the sponsors; the content of the article has not been influenced by the sponsors.

Ethical statement

The Institutional Ethics Committee of Shahid Beheshti University of Medical Sciences gave ethical approval for this case report.

Table 2. Review of literature on mesenteric vein thrombosis (MVT) in pediatric patients with cystic fibrosis (CF). The table summarizes key studies and articles that explore the increased risk of venous thromboembolism (VTE), including MVT, in CF patients. The studies provide insights into the gastrointestinal and hematological complications associated with CF, highlighting the predisposition to thrombosis due to chronic inflammation, platelet activation, and liver dysfunction, as discussed in the presented case report.

Author(s)	Year	Study Focus	Key Findings	Relevance to Case
Knight-Perry et al.	2017	Venous thromboembolism in children with CF	Retrospective study showing increased risk factors for VTE in pediatric CF patients	Highlights the importance of considering thrombotic events like MVT in CF patients with abdominal pain
Scott et al.	2020	Superior mesenteric venous thrombus in CF patients	Case study of a 51-year-old CF patient with SMV thrombosis	Similar to the case report; points out diagnostic challenges and treatment strategies
Lindberg et al.	2018	Platelet activation in CF patients	Demonstrates increased platelet activation and its association with thrombosis in CF patients	Correlates CF-related thrombophilia to thrombus formation as seen in the case
Balfour-Lynn et al.	2005	Thrombophilia in children with CF	Study showing increased incidence of thrombophilia in pediatric CF patients, linked to catheter use	Provides background on the hypercoagulability in CF patients, explaining the risk of MVT in the reported case
McGivern et al.	2013	Platelet function in CF patients	Identified a defect in platelet granule secretion that contributes to an increased inflammatory response	Helps understand the inflammatory processes leading to thrombophilia in CF patients

[Downloaded from ijbc.ir on 2026-11-27]

[DOI: 10.61186/ijbc.16.3.1]

Arora et al.	2016	CFTR mutations and management	Pharmacological management of CF patients with specific CFTR mutations	Supports genetic testing in CF patients, as performed in the case to identify thrombophilia
Branchford & Carpenter	2018	Role of inflammation in venous thromboembolism	Describes how inflammation in CF increases the risk of venous thromboembolism	Relevant for understanding the inflammatory mechanisms behind MVT in CF patients
Williams et al.	2022	Thrombophilic tendency in pediatric CF patients	Found elevated levels of lupus anticoagulants and reductions in protein C and S in pediatric CF patients	Reinforces the importance of testing for hereditary thrombophilia as done in the case report

References

1. Branfield S, Washington AV. Control the platelets, control the disease: A novel cystic fibrosis hypothesis. J Thromb Haemost. 2020 Jul;18(7):1531–4.

2. Döring G, Elborn JS, Johannesson M, de Jonge H, Griese M, Smyth A, et al. Clinical trials in cystic fibrosis. In: Journal of Cystic Fibrosis. 2007. p. 85–99.

3. Knight-Perry J, Branchford BR, Thornhill D, Martiniano SL, Sagel SD, Wang M. Venous thromboembolism in children with cystic fibrosis: Retrospective incidence and intrapopulation risk factors. Thromb Res [Serial online]. 2017 Oct;158(May):161–6.

4. Mingora CM, Flume PA. Pulmonary Complications in Cystic Fibrosis: Past, Present, and Future: Adult Cystic Fibrosis Series. Chest [Serial online]. 2021 Oct 1;160(4):1232–40.

5. Konrad J, Eber E, Stadlbauer V. Changing paradigms in the treatment of gastrointestinal complications of cystic fibrosis in the era of cystic fibrosis transmembrane conductance regulator modulators. Paediatr Respir Rev [Serial online]. 2022 Jun 1;42:9–16 .

6. Scott JA, Barry PJ, Jones AM, Athwal VS. Management of superior mesenteric venous thrombus in cystic fibrosis related liver disease. Paediatr Respir Rev [serial online]. 2020 Sep;35:106-108.

7. Mavilia M. Distal intestinal obstructive syndrome (DIOS): a gastrointestinal complication of cystic fibrosis in adults. Clin J Gastroenterol [serial online]. 2019;12(6):571-573.

8. Gillespie CD, O'Reilly MK, Allen GN, McDermott S, Chan VO, Ridge CA. Imaging the Abdominal Manifestations of Cystic Fibrosis. Int J Hepatol [serial online]. 2017;2017:1–9.

9. Lusman SS, Grand R. Approach to chronic abdominal pain in Cystic Fibrosis. J Cyst Fibros [serial online]. 2017 Nov;16 Suppl 2:S24-S31.

10. Dracea LL, Vida LC, Patran OC. Appendicitis in Cystic Fibrosis: A Challenging Diagnosis. Bulletin of the Transilvania University of Brasov [serial online]. 2020 Dec 30;13 (62)(2):19–26.

11. Lindberg U, Svensson L, Hellmark T, Segelmark M, Shannon O. Increased platelet activation occurs in cystic fibrosis patients and correlates to clinical status. Thromb Res [serial online]. 2018 Feb;162(November 2017):32–7.

12. Roesch EA, Nichols DP, Chmiel JF. Inflammation in cystic fibrosis: An update. Pediatr Pulmonol [serial online]. 2018;53(S3):S30-S50 (21 screens).

13. Samoyedny A, Sajja S, Ratnasekera A. Idiopathic acute mesenteric venous thrombosis causing ischemic enteritis: A case report. Int J Surg Case Rep [serial online]. 2020;74:247-250.

14. Arora K, Naren AP. Pharmacological Correction of Cystic Fibrosis: Molecular Mechanisms at the Plasma Membrane to Augment Mutant CFTR Function. Curr Drug Targets. 2016;17(11):1275–81.

15. Spicuzza L, Sciuto C, Di Dio L, Mattina T, Leonardi S, del Giudice MM, et al. Mild cystic fibrosis in patients with the rare P5L CFTR mutation. J Cyst Fibros. 2012 Jan;11(1):30–3.

16. Handschick M, Hedtfeld S, Tümmler B. Frequency of the hyperactive W493R ENaC variant in carriers of a CFTR mutation. J Cyst Fibros. 2012 Jan;11(1):53–5.

17. Freswick PN, Reid EK, Mascarenhas MR. Pancreatic Enzyme Replacement Therapy in Cystic Fibrosis. Nutrients. 2022 Mar 23;14(7):1341.

18. Anıl H, Kılıç Yıldırım G, Harmancı K, Bozkurt Turhan A, Akay OM, Bör Ö, et al. Thromboelastogram as a Tool to Predict Hypercoagulability in Children With Cystic Fibrosis. Clin Appl Thromb. 2018 Mar;24(2):348–52.

19. McGivern TJ, Molloy K, Bahar M, McElvaney NG, Moran N, Kerrigan SW. A platelet dense-granule secretion defect may lead to a muted inflammatory cell mobilization response in cystic fibrosis patients. J Thromb Haemost [serial online]. 2013;11(10):1939-1942.

20. Marteyn BS, Burgel P-R, Meijer L, Witko-Sarsat V. Harnessing Neutrophil Survival Mechanisms during Chronic Infection by Pseudomonas aeruginosa: Novel Therapeutic Targets to Dampen Inflammation in Cystic Fibrosis. Front Cell Infect Microbiol. 2017;7:243.

21. Rimessi A, Bezzerri V, Patergnani S, Marchi S, Cabrini G, Pinton P. Mitochondrial Ca2+-dependent NLRP3 activation exacerbates the Pseudomonas aeruginosa-driven inflammatory response in cystic fibrosis. Nat Commun [serial online]. 2015;6:6201.

22. Branchford BR, Carpenter SL. The Role of Inflammation in Venous Thromboembolism. Front Pediatr. 2018;6:142.

23. Balfour-Lynn IM, Malbon K, Burman JF, Davidson SJ. Thrombophilia in children with cystic fibrosis. Pediatr Pulmonol. 2005;39.

24. Williams V, Griffiths ABM, Sci BM, Yap ZL, Martin J, Smith G, et al. Increased Thrombophilic Tendency in Pediatric Cystic Fibrosis Patients. :71–6.

[Downloaded from ijbc.ir on 2026-11-27]

[DOI: 10.61186/ijbc.16.3.1]