

# Wandering Spleen with Venous Aneurysm as the Cause of Recurrent Abdominal Pain and Thrombocytopenia

Rahim Mahmodlou M.D

Department of surgery, Emam Khomeini Hospital, Urmia University of Medical Sciences.

Corresponding author: Rahim Mahmodlou, Department of Surgery, Emam Khomeini Hospital, Urmia University of medical science.  
(Phone: +98-4413447113, Fax: +984413469935, E-mail:mahmodlou@yahoo.com)

**Keywords:** Wandering spleen, Torsion, Venous aneurysm.

## Introduction

Wandering spleen is an extremely rare condition with a reported incidence of <0.2% of splenectomies and is characterized by excessive motility and displacement of the spleen from its normal site.<sup>1</sup> Because of excessive motility and absence of normal fixation, complications are common. Thrombocytopenia and venous aneurysm are very rare.<sup>1,2</sup> Diagnosis is made by abdominal ultrasonography and computed tomography (CT) scan.<sup>1,3</sup> We report a case of wandering spleen who presented with abdominal pain and thrombocytopenia.

## Case Report

The patient was a 36-years-old man who referred to the Emergency Department due to abdominal pain. He had gradually increasing pain for ten days without nausea and vomiting and with normal bowel function. His pain was mild and recurrent in the past year and he was treated as an outpatient.

There were no pathologic findings in the head, neck and chest examination. In the abdomen, a mobile mass was detected in the left side of the umbilicus without tenderness. His laboratory examinations were normal except for thrombocytopenia with a platelet count of 40000/ $\mu$ L. Ultrasonography of the abdomen revealed that spleen was not in its usual site and was located in mid-abdomen with a 4 cm aneurysm in the splenic vein. He underwent abdominal CT

scan with intravenous contrast which showed soft tissue in mid abdomen (Fig 1).

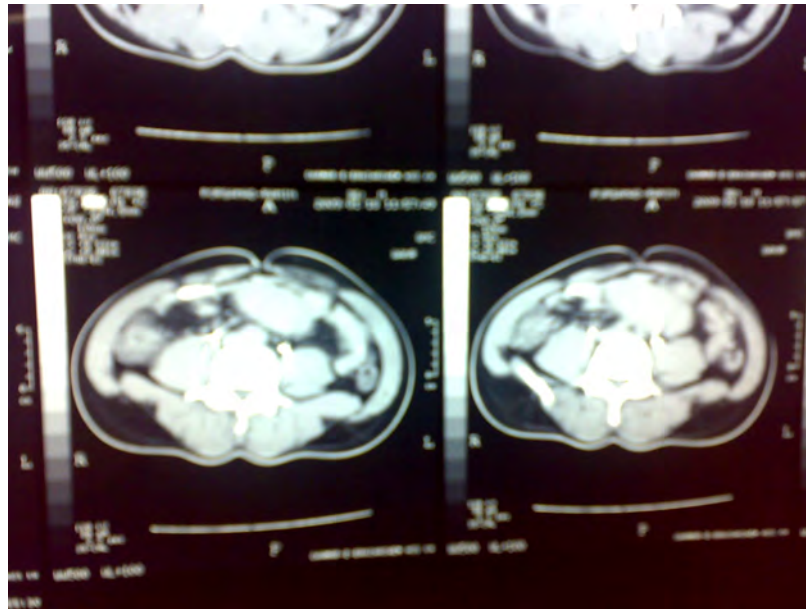
He underwent laparotomy with the diagnosis of wandering spleen and aneurysm of splenic vein and hypersplenism after injection of pneumovax. Operative finding was a large spleen with a long twisted pedicle and a 4-5 cm aneurism in the splenic vein and sequel of previous infarctions in the spleen (Fig 2). Splenectomy was carried out due to infarcted regions in the spleen, aneurysm of the vein and cytopenia. Post-operative period was eventless and the patient was discharged on 4<sup>th</sup> post-operative day with platelet count of 164000/ $\mu$ L. Four months after operation, he had no problem.

## Discussion

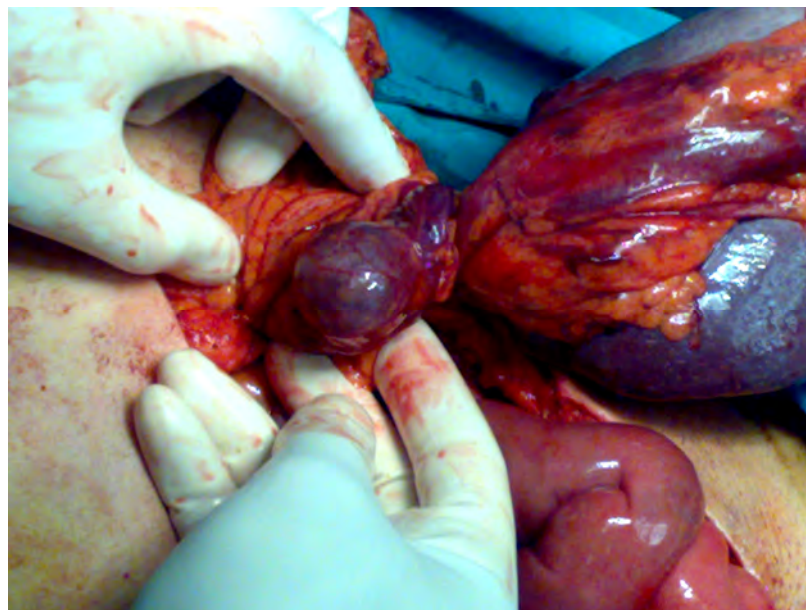
Wandering spleen is an extremely rare condition that is characterized by excessive mobility and displacement of the spleen from its normal position due to congenital or acquired absence of splenic ligaments.<sup>1,5</sup>

Hippocrates, Pliny, Heophilus and Galen recognized that the spleen could be located in an unusual place but a clinical description of wandering spleen (WS) was first noted at autopsy in 1967 by Van Horne.<sup>5</sup>

As an intraperitoneal organ, the spleen develops as mesenchymal cell clusters within the dorsal mesogastrium at approximately 28 days. The most important structure derived from the dorsal mesogastrium is the gastrolinal and lienorenal



**Figure 1.** CT scan of abdomen shows soft tissue mass in mid abdomen.



**Figure 2.** Intraoperative finding showing large Spleen with twisted pedicle and venous aneurysm.

ligaments. It has been hypothesized that spleen develops during foregut rotation, this period influences splenic positioning and a congenital wandering spleen develops as a result of laxity or maldevelopment of its suspensory ligaments. There is improper formation of a long splenic pedicle with increased probability for abnormal fixation and torsion.<sup>6</sup>

In acquired conditions, abdominal laxity, multiple pregnancies, hormonal changes with pregnancy or splenomegaly have also been implicated.<sup>3,5,7</sup>

It is observed more commonly in women who are 20 to 40 years old.<sup>1,3,5</sup> The age at presentation may vary from 3 months to 80 years. Women constitute 80% of cases and one third are children.<sup>1,2,5</sup>

The clinical presentation is variable. The patient may be asymptomatic or may have intermittent pain resulting from intermittent torsion and

distortion or may present with a mobile palpable mass.<sup>1,4,5</sup>

Excessive mobility of the spleen can predispose it to complications including acute torsion of the vascular pedicle, gangrene or splenic abscess formation, hemorrhage from gastro-esophageal varices, acute pancreatitis or necrosis of pancreatic tail secondary to torsion, partial or complete gastric volvulus and intestinal obstruction. In these conditions, the patient presents with acute abdomen and may be confused with appendicitis, ovarian torsion, diverticulitis, cholecystitis, pancreatitis and non specific peritonitis.<sup>1-2</sup>

Laboratory evaluations are usually non specific but may rarely reveal evidence of hypersplenism or functional asplenia by evaluating peripheral smears for Howell-jolly bodies or other particles, in particular when associated with torsion of an elongated splenic pedicle.<sup>8</sup>

Since a clinical diagnosis can be difficult, noninvasive imaging procedures, such as sonography, nuclear scintigraphy, CT scan and MRI are the common diagnostic modalities.<sup>1,5</sup> Plain radiographs and barium examination are usually non specific.<sup>1</sup>

Ultrasonography and CT scan show absence of spleen in its normal position and a comma-shaped, mobile mass in the abdomen or pelvis. CT scan is the diagnostic modality of choice for the diagnosis of wandering spleen, especially when there is suspicious of torsion and when the spleen cannot be observed on ultrasonography because of bowel gas. Post-contrast CT scan reveals nonenhancing low-attenuation area in the regions of splenic infarction thereby providing crucial information concerning the viability of the spleen. The "Whirl sign" of the splenic pedicle is diagnostic of splenic torsion. Another specific sign of splenic infarction on CT scan is the "rim sign" in which the splenic capsule is hyper dense compared with its parenchyma. An angiographic finding characteristic

of the diseases is a tapered and abruptly twisted distal splenic artery.<sup>1,3</sup>

Treatment of WS is operative because conservative treatment is associated with increased complications.<sup>1,3</sup> Splenectomy is advocated if there is functional asplenia due to torsion, splenic infarction, splenic vessel thrombosis, secondary hypersplenism or any suspicion of malignancy.<sup>1,3,4</sup> Splenopexy is preferred when a viable WS is found at laparotomy and there is no evidence of infarction, thrombosis or hypersplenism.<sup>1,3,5,6</sup>

## References

1. Singla V, Galwa RP, Khandelwal N, Poornachandra KS, Dutta U, Kochhar R. Wandering spleen presenting as bleeding gastric varices. *Am J Emerg Med.* 2008;26:637 e1-4.
2. Tucker ON, Smith J, Fenlon HM, McEntee GP. Recurrent torsion of a wandering spleen. *Am J Surg.* 2004;188:96-7.
3. Bakir B, Poyanli A, Yekeler E, Acunas G. Acute torsion of a wandering spleen: imaging findings. *Abdom Imaging.* 2004;29:707-9.
4. Sarimurat N, Tekant GT, Huseyin S, Soylet Y, Senyuz OF. Wandering spleen in childhood: a report of three cases. *Surg Today.* 1997;27:1086-8.
5. Soleimani M, Mehrabi A, Kashfi A, Fonouni H, Buchler MW, Kraus TW. Surgical treatment of patients with wandering spleen: report of six cases with a review of the literature. *Surg Today.* 2007;37:261-9.
6. Breisch EA, Krous HF. Autoinfarcted wandering spleen and fatal pneumococcal sepsis in an infant. *Pediatr Dev Pathol.* 2005;8:132-5.
7. Ben Ely A, Segulier E, Lotan G, Strauss S, Gayer G. Familial wandering spleen: a first instance. *J Pediatr Surg.* 2008;43:E23-5.
8. Ajello A, Minniti A, Malatesta A, Federici Di Abriola G, Dall'Oglio L. The wandering spleen: something to bear in mind in the presence of a mobile abdominal mass. *Eur J Pediatr.* 2004;163:277-8.
9. Moll S, Igelhart JD, Ortel TL. Thrombocytopenia in association with a wandering spleen. *Am J Hematol.* 1996;53:259-63.