

## Case Report

## Under Pressure: A Rare Portrait of Cardiac Strain and Respiratory Distress in Mediastinal Neuroblastoma

Mohsen Rahmanian<sup>1</sup>, Sarah Khosropanah<sup>1</sup>, Amir Muhammad Khuban Azghadi<sup>1</sup>, Hamid Farhangi<sup>2\*</sup><sup>1</sup>School of Medicine, North Khorasan University of Medical Sciences, Bojnord, Iran.<sup>2</sup>Department of Pediatrics Hematology and Oncology, School of Medicine, Mashhad University of Medical Sciences, Mashhad, Iran.Scan and read the  
article online**Citation** Rahmanian M, Khosropanah S, Khuban Azghadi AM, Farhangi H. Under Pressure: A Rare Portrait of Cardiac Strain and Respiratory Distress in Mediastinal Neuroblastoma. Iran J Blood Cancer. 2025 June 30;17(2): 13-23.**Article info:**

Received: 25 Mar 2025

Accepted: 15 June 2025

Published: 30 June 2025

**Keywords:**Neuroblastoma  
Chemotherapy  
Pediatrics  
Cardiac Compression  
Thoracic Tumors**Abstract****Background:** Neuroblastoma is the most common extracranial solid tumor in children, typically arising from the adrenal glands or abdominal sympathetic chain. Thoracic involvement, particularly in the posterior mediastinum, is rare and may present with nonspecific respiratory symptoms. When adjacent cardiac structures are compressed, clinical severity increases, posing diagnostic and therapeutic challenges.**Case Presentation:** A one-year-old girl presented with persistent wheezing and recurrent pneumonia unresponsive to antibiotics. Initial imaging suggested pulmonary sequestration, but further evaluation—including echocardiography and angiography—revealed a posterior mediastinal mass compressing the left atrium and ventricle. Biopsy confirmed neuroblastoma. No metastasis was found on staging. Classified as intermediate-risk, she was treated per the Children's Oncology Group (COG) A3961 protocol with chemotherapy. Treatment was well-tolerated, symptoms improved, and follow-up imaging showed significant tumor reduction without complications or recurrence.**Conclusion:** Posterior mediastinal neuroblastoma may mimic common respiratory illnesses, delaying diagnosis. Cardiac compression can worsen symptoms and increase risks. Early recognition, accurate diagnosis, and multidisciplinary care are essential for favorable outcomes, as demonstrated by this case with no treatment complications or tumor recurrence on follow-up.**1. INTRODUCTION**

Neuroblastoma is one of the most common extracranial solid tumors in pediatric patients, with an incidence of 2.26 per million person-years in the United States [1]. Males have

a slightly higher incidence than females, and there are racial differences in incidence among young children [2]. Risk factors may include maternal alcohol use during pregnancy, while protective factors include maternal vitamin intake and a history of allergic disease [2]. Socioeconomic factors and farming activity have also been associated with incidence [3].

**\* Corresponding Author:**

Hamid Farhangi

Affiliation: Department of Pediatrics Hematology and Oncology, School of Medicine, Mashhad University of Medical Sciences, Mashhad, Iran.

E-mail: FarhangiH@mums.ac.ir

Neuroblastoma arising in the chest is uncommon and accounts for a smaller proportion of cases, potentially complicating diagnosis and treatment. The management of neuroblastoma is stratified into low, intermediate, and high-risk groups based on factors such as age, stage, and tumor biology. The intermediate-risk group, defined by the COG, represents a category where aggressive treatment is necessary to prevent progression while also minimizing long-term toxicities [4].

This report details the clinical course of a pediatric patient with intermediate-risk mediastinal neuroblastoma, presenting with unusual thoracic involvement and persistent respiratory symptoms unresponsive to standard treatment. The case underlines the challenges of diagnosing neuroblastoma in rare locations, the significance of cardiac compression as a complicating factor, and the critical need for a multidisciplinary approach in managing such complex cases.

## 2. HIGHLIGHTS

- A rare case of mediastinal neuroblastoma in a pediatric patient highlights the diagnostic challenges and respiratory complications caused by cardiac compression, emphasizing the need for early imaging and intervention.
- Mediastinal neuroblastoma was diagnosed in a one-year-old patient after persistent wheezing and pneumonia unresponsive to antibiotics, underscoring the need to consider malignancy in pediatric patients with atypical respiratory symptoms.
- Advanced imaging techniques, including echocardiography and angiography, enabled prompt diagnosis and treatment with the COG A3961 protocol, leading to a favorable clinical outcome despite significant cardiac involvement.
- This case emphasizes the critical role of coordinated care between pediatric oncology, cardiology, and radiology in managing complex thoracic neuroblastoma, minimizing long-term toxicities.
- Aggressive chemotherapy with carboplatin, etoposide, and doxorubicin, along with vigilant monitoring for cardiotoxicity, led to an improved prognosis in this case of cardiac compression.

## 3. PLAIN LANGUAGE SUMMARY

Neuroblastoma is a type of cancer that most commonly affects children. While it usually begins in the abdomen, in rare cases, it can also appear in the chest area, specifically in the mediastinum. Diagnosing mediastinal neuroblastoma can be difficult because its symptoms are similar to common

illnesses like chest infections. In this case report, we describe a one-year-old girl with persistent respiratory symptoms and pneumonia that failed to respond to standard treatments. Initially, clinicians suspected a pulmonary condition; however, subsequent imaging revealed a mediastinal mass compressing the heart and exacerbating her respiratory distress. The mass was diagnosed as neuroblastoma. After confirming the diagnosis and ruling out any spread of the cancer, the patient was treated using a chemotherapy regimen designed for her age and condition.

This case highlights the importance of considering rare conditions such as neuroblastoma when conventional treatments prove ineffective. It also shows the importance of detailed testing and teamwork in treatment, especially when the tumor is near vital organs like the heart. Even though the treatment worked, this case shows how hard it can be to diagnose rare diseases. Early detection and treatment are crucial, and this case highlights the importance of healthcare professionals being aware of unusual presentations of diseases that may resemble more common illnesses.

## 4. CASE PRESENTATION

### 4.1. Initial Presentation

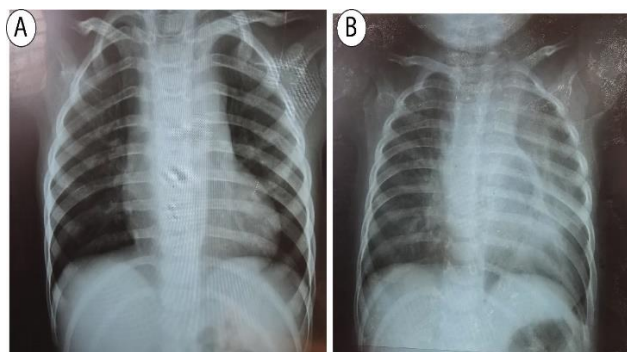
A one-year-old female patient presented to Sheikh Hospital with a persistent history of pneumonia and wheezing, unresponsive to conventional antibiotic therapy. Despite ongoing treatment, symptoms persisted, prompting further evaluation.

### 4.2. Imaging Findings

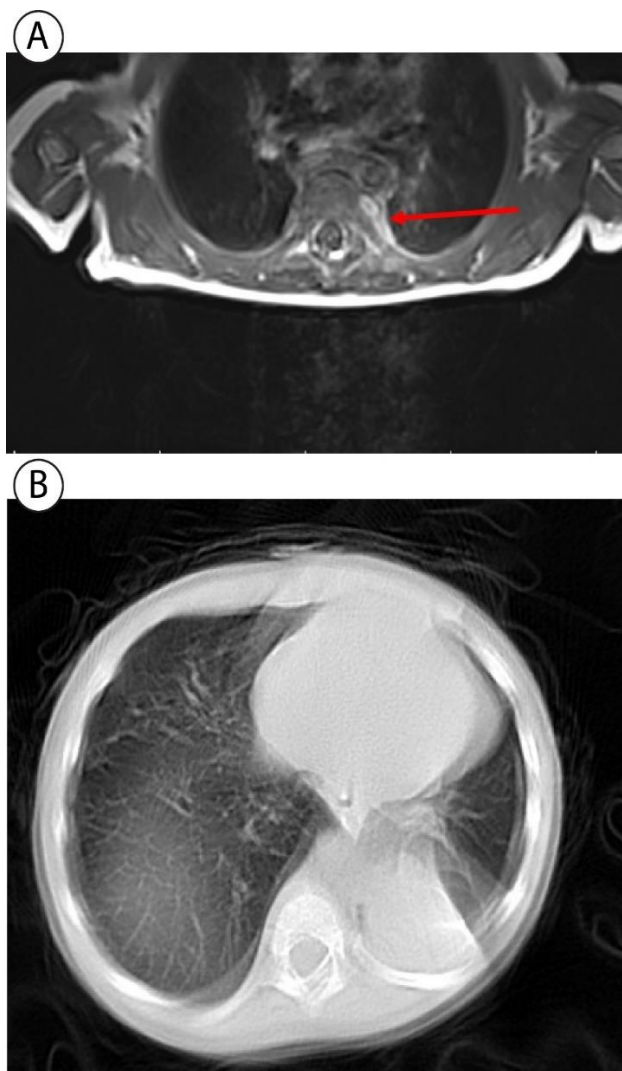
Chest X-ray revealed abnormal findings (Figure 1). The tumor measures 7.5 × 6.5 × 5.8 cm. Chest ultrasound identified a mass in the posterior mediastinum, necessitating further imaging to clarify its nature. A non-contrast CT scan raised suspicion of lung sequestration (Figure 2); however, this was excluded after angiography (Figure 3) showed no aberrant vascular supply. Echocardiography performed by a pediatric cardiologist confirmed a mediastinal mass compressing the left atrium and ventricle, causing leftward shifting of the great vessels. The mass was also associated with mild to moderate mitral regurgitation, mild tricuspid regurgitation, and evidence of pulmonary hypertension, likely contributing to the patient's respiratory symptoms.

### 4.3. Histopathology

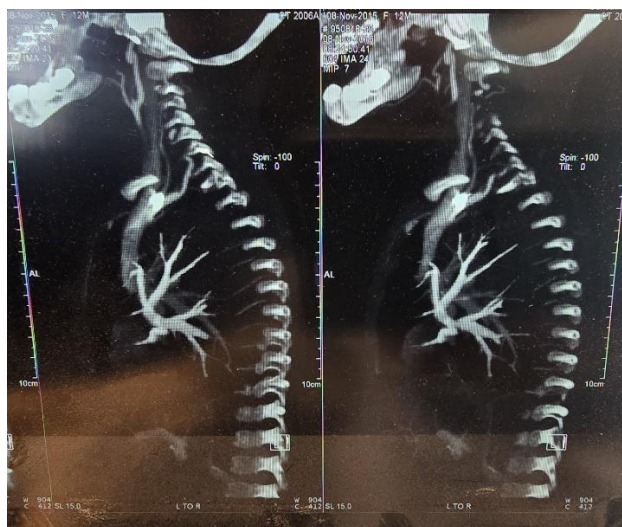
A sonography-guided biopsy confirmed poorly differentiated neuroblastoma, characterized by small round blue cells with fine chromatin, high mitotic activity, and



**Figure 1.** Chest X-ray showing a localized opacity in the left thoracic cavity, indicative of a mass-like lesion.



**Figure 2.** Non-contrast CT scan revealing a suspicious mass in the posterior mediastinum, initially raising the possibility of lung sequestration.



**Figure 3.** Angiographic study confirming the absence of lung sequestration, excluding the possibility of abnormal blood supply to the mass and providing clarity on the mass's vascular characteristics.

tumor nests. Abdominal ultrasound showed no evidence of metastasis. Laboratory tests included CBC, renal and liver function, and urine catecholamines.

#### 4.4. Laboratory Findings

The laboratory results revealed a slightly elevated lactate dehydrogenase (LDH), often linked to higher tumor burden. Electrolytes, liver enzymes, and renal function were normal, indicating no organ compromise. Tumor markers alpha-fetoprotein (AFP) and beta-human chorionic gonadotropin ( $\beta$ -hCG) were within normal limits, helping exclude germ cell tumors. Normal platelet count and low erythrocyte sedimentation rate (ESR) suggested absence of significant inflammation or bone marrow involvement.

#### 4.5. Treatment Strategy

The patient was treated following the Children's Oncology Group (COG) A3961 protocol for intermediate-risk neuroblastoma. The chemotherapy regimen consisted of multiple cycles adjusted for age and weight. The first cycle included carboplatin 560 mg/m<sup>2</sup> IV over 1 hour on Day 1 and etoposide 120 mg/m<sup>2</sup> IV over 2 hours on Days 1-3. Subsequent cycles added cyclophosphamide 1,000 mg/m<sup>2</sup> IV over 1 hour on Day 1 with hydration, and doxorubicin 30 mg/m<sup>2</sup> IV over 1 hour on Day 3. Due to doxorubicin's cardiotoxicity, cardiac function was monitored by serial echocardiograms. Chemotherapy was repeated every 21 days, with close monitoring of clinical status, blood counts, and organ functions. Supportive care included antiemetics

and prophylactic antibiotics to manage side effects and prevent infections. Chemotherapy was planned for four cycles, with the option to stop early if remission was achieved, balancing efficacy with minimizing toxicity. At the latest follow-up, the patient continues regular visits with no reported tumor recurrence or serious complications.

## 5. LITERATURE REVIEW

Posterior thoracic neuroblastoma is associated with various complications, most notably pleural effusion and respiratory distress. In a study of 295 patients, 10.5% presented with pleural effusion, which was often linked to high-risk disease. Tumor extension through the intervertebral foramina may manifest as back pain, limping, limb weakness, paralysis, or urinary incontinence or retention, often necessitating urgent neurosurgical intervention, as reported by Singh et al. and Ramachandran et al. To our knowledge, our case represents the first reported instance of posterior mediastinal neuroblastoma associated with significant cardiac compression as the primary complication. A review of reported cases highlights the clinical burden of pediatric posterior mediastinal neuroblastoma, with complications such as neurological deficits and respiratory distress frequently documented across multiple studies (Table 1).

## 6. DISCUSSION

### 6.1. Diagnostic Challenges

Persistent cough in children is common but can be diagnostically challenging, especially when it remains unresponsive to standard therapy. Though often benign, it may signal underlying pathology. Chronic and treatment-resistant cough in children, unlike in adults, shows fewer clear links to upper airway disorders, asthma, or GERD. Other possible causes include foreign body aspiration, airway lesions, exposure to environmental toxins, non-asthmatic eosinophilic bronchitis, respiratory infections, adverse drug reactions, otogenic sources, and masses such as tumors or cystic echinococcosis cysts [18, 20]. Every pediatrician should be familiar with the common differential diagnoses of chronic, treatment-resistant cough, although malignancy is a rare underlying cause. Therefore, prompt evaluation of such cases is essential to exclude uncommon and malignant underlying causes. Neuroblastoma typically originates in the adrenal glands or along the sympathetic nervous system chain, with mediastinal involvement occurring in only about 20% of cases. While the majority of neuroblastomas present in the abdomen, thoracic presentations, such as in this case, are

rarer and can lead to diagnostic dilemmas. Pediatric cases of mediastinal neuroblastoma have been reported, often presenting with respiratory symptoms. Common symptoms include breathing difficulty, cough, pleural effusion, and superior vena cava syndrome [21].

Imaging can assess the extent of a primary tumor, determine its relationship with anatomical structures, and identify metastases. As ultrasonography is widely available and noninvasive, it is the initial imaging modality used for neuroblastoma. In this case, abdominal sonography revealed no evidence of metastasis. More localized assessments require computed tomography (CT) or magnetic resonance imaging (MRI) [21].

### 6.2. Therapeutic Considerations

Mediastinal neuroblastoma with intraspinal extension can cause spinal cord compression, manifesting as neurological symptoms such as weakness or paralysis, which require prompt intervention [19]. Cardiac compression and related symptoms are extremely rare in pediatric thoracic neuroblastoma, as tumorigenesis in mediastinal neuroblastoma typically occurs in the paraspinal regions and is more likely to affect the spinal cord [22]. In this case, although early diagnosis prevented progression to overt cardiac compromise, echocardiography demonstrated that the mediastinal mass had already impacted the heart, contributing to mitral and tricuspid regurgitation and pulmonary hypertension. Because this case represents, to our knowledge, the first reported instance of a posterior mediastinal neuroblastoma with significant cardiac compression and related complications, it is crucial to review conventional neuroblastoma treatments through the lens of cardiotoxicity.

Among commonly used agents, doxorubicin stands out for its high cardiotoxic potential, capable of inducing dose-dependent cardiomyopathy and heart failure—thus requiring strict cumulative dose limits and close cardiac monitoring [23, 24]. Cyclophosphamide presents a moderate risk, especially at high doses, due to potential hemorrhagic myocarditis or arrhythmias [25]. Busulfan has been associated with pulmonary hypertension and endocardial fibrosis [26, 27]. Melphalan, meanwhile, has been linked to supraventricular tachycardia, with increased risk in patients receiving intensive chemotherapy or those with underlying cardiac vulnerabilities [28]. In addition, thoracic radiation therapy carries a high long-term cardiotoxic risk—especially when cardiac structures lie within or near the radiation field [29, 30].

The treatment approach, based on the Children's Oncology Group (COG) A3961 protocol for intermediate-risk

**Table 1.** Summary of Pediatric Posterior Mediastinal Neuroblastoma Cases with Significant Complications, Published 1971–Present.

Author and date	Number of Cases	Age / Gender	Clinical Presentation	Tumor Location	Tumor Size (cm)	Histopathology	Molecular Findings	Treatment Administered	Outcome	Ref.
Ait Si Abdessadeq et al. (2025)	1	4 y/o / Male	Cervical lymphadenopathy, right apical opacity on CXR	Right posterior-superior mediastinum	6.4 × 4.9 × 7.6	Neuroblastoma (confirmed)	Not reported	Neoadjuvant chemotherapy	Death before surgery	[5]
Singh et al. (2021)	1	6 y/o / Female	Upper backache, paraplegia, bladder dysfunction	Posterior mediastinum with spinal canal extension (D3-D6)	Not specified	Poorly differentiated neuroblastoma	Positive for neuron-specific enolase (NSE)	D3–D6 laminectomy, subtotal excision, spinal decompression, chemotherapy	Symptom-free at 2-year follow-up	[6]
Bargujar et al. (2023)	1	5 months / Male	Sudden onset of inability to move lower limbs, weak cry, urinary dribbling, lethargy, seizures, respiratory distress, upper limb weakness	Posterior mediastinum, left paravertebral region (D1 to D8 vertebral level)	1.9 cm × 3.0 cm	Poorly differentiated neuroblastoma; round tumor; neuron-specific enolase positive	Not reported	Supportive care, ventilator support; multidisciplinary approach (neurosurgery, oncology, physician), but no specific chemo/surgery details due to rapid deterioration	The patient did not survive due to rapid disease progression with spinal cord and respiratory involvement.	[7]
Feki et al., 2021	1	13 y / Female	Lumbar pain, paraplegia; concurrent bilateral breast masses and axillary LAD	Posterior mediastinum with spinal compression	Large (not precisely measured)	Neuroblastoma in mediastinum; breast mass = metastatic NB deposits	– (not reported)	Not detailed (likely decompression + systemic therapy)	Poor prognosis—disseminated disease with synchronous breast mets	[8]
Ko et al., 1996	1	3 y / Female	2-week history of painless 2×2 cm posterior chest-wall mass; no neuro deficit	Left posterior mediastinum with chest-wall & T9–T10 intraspinal extension	6 × 5 × 3	Interlacing fibroblasts in dense collagen; no mitoses (fibromatosis)	Normal AFP, β-hCG, VMA; negative bone scan/marrow	En bloc resection (ribs 9–11, T9–10 laminectomy, extradural decompression, chest-wall reconstruction); no chemo/radiotherapy	Uneventful recovery; no recurrence at last follow-up	[9]

Atwal et al. (2014)	1	12 y/o / Male	Occasional dull chest pain, dry cough, progressive lower limb weakness (4 months)	Left posterior mediastinum with intraspinal extension (T9 to L2)	Not specified	Neuroblastoma	Not specified	Surgical removal of the mass with intraspinal component + chemotherapy	Marked symptomatic relief post-surgery	[10]
Kazemian et al. (2019)	1	17-day-old / F	Respiratory distress, stridor, and tachypnea from day 7 of life	Posterior mediastinum (R)	4.2 × 3.3 × 4.1	Poorly differentiated neuroblastoma; INPC: favorable histology	Normal urine VMA; no BM involvement	Emergency surgical resection, debulking; post-op supportive care; transferred to oncology ward for chemotherapy	Improved post-surgery; extubated; referred for further oncologic care	[11]
McLatchie et al. (1981)	7	6 months to 4.5 years; 5 M, 2 F	Respiratory symptoms (2), neurological symptoms (4), urinary tract symptoms (1)	Thoracic (intrathoracic)	Not specifically reported	Neuroblastoma	Urinary VMA (catecholamine metabolites) is elevated variably pre-op, decreased post-op	Surgery (thoracotomy excision) in all; some received local radiotherapy and chemotherapy (vincristine, cyclophosphamide, prednisolone, adriamycin)	5 symptom-free long-term survivors; 1 died from an unrelated tumor; 1 died from neuroblastoma	[12]
Stetsenko TI et al., 2024	1	1 year 9 months / Female	Opsoclonus, truncal tremor, cerebellar ataxia, behavioral changes, sleep disorder after URI	Posterior mediastinum, left paravertebral region (T5-T9 level)	5.4 × 1.9 × 2.1 × 3.6 (max vertical 5.4 cm, sagittal 1.9 cm, lateral 2.1 cm, intercostal 3.6 cm)	Neuroblastoma (ICD-O 9500/3), pT1bpN0M0, negative N-myc	Increased antibodies to neuron-specific enolase; immune studies showed a slight T-cell increase, reduced HLA-DR expression	IV Immunoglobulin 2 g/kg over 5 days (6 courses over 1 year), radical surgical resection of tumor, immunosuppressive therapy	Improvement in ataxia and walking; opsoclonus remained unchanged; positive dynamics overall; further cancer institute follow-up	[13]
Tang et al., 2021	77	Median 31.7 months (range two mo-13 yr), 40 M / 37 F	Symptoms: neurological deficits (44/77), paraparesis (14), lower extremity weakness (34), bladder dysfunction (16), pain (11), polypnea	Cervicothoracic (22), Thoracic (45), Thoracolumbar (10)	<5 cm (varied), 5-10 cm (varied), >10 cm (few cases)	Neuroblastoma (38), ganglioneuroblastoma (13), ganglioneuroma (10), PNET (2), others	MYCN amplified (1 case)	4 groups: chemotherapy, VATS/thoracotomy, neurosurgical decompression, combined thoracic-neurosurgical	Best neurological recovery and survival in combined surgery group; 76.5% neurological improvement	[14]

			(11), others (constipation, diarrhea, hypertension, scoliosis)						after neurosurgery; shorter symptom duration ( $\leq 4$ weeks) associated with better recovery; combined approach had 90% survival and 80% complete tumor regression	
<b>Fatimi et al., 2011</b>	1	8-year-old male	Right-sided lumbar pain; no constitutional signs	Posterior mediastinum	$9.5 \times 7 \times 4.5$	Ganglioneuroblastoma, nodular type; composite Schwannian stroma-rich/stroma-dominant and stroma-poor	Positive IHC: neurofilament, synaptophysin, chromogranin; MKI $< 2\%$ , mitotic rate 2-3/HPF; no MYCN mentioned	Surgical excision via left thoracotomy; post-op antibiotics and NSAIDs; no chemo or radiotherapy noted	Patient stable with no recurrence at 1-year follow-up; transient fever and desaturation post-op	[15]
<b>Kinsella et al., 2011</b>	1	5-month-old male	Progressive stridor for 2 weeks, supraclavicular mass, biphasic stridor, elevated urinary catecholamines	Right posterior mediastinum extending to the supraclavicular region	$5 \times 3$	Small round blue cell tumor; confirmed neuroblastoma on histology	MYCN not amplified; localized disease; elevated urinary HMMA	Emergency intubation, chemotherapy (vincristine, adriamycin, cyclophosphamide); later surgical resection of residual mass	Extubated after 14 days, no viable tumor on resection, well and tumor-free at 10 months	[16]
<b>Ochi T, Koga H, Ueno H, et al., 2023</b>	1	28-month-old girl	Fever, left thigh pain	Right posterior mediastinum	7 cm (initial), shrunk to 5 cm post-chemo	Neuroblastoma (NB)	MYCN non-amplified neuroblastoma	Induction chemotherapy (cyclophosphamide, vincristine, pirarubicin, cisplatin), high-dose chemo with autologous stem cell transplantation; complete robotic-	Complete tumor resection, no intraoperative rupture, no recurrence at 7-month follow-up	[17]

								assisted surgical resection		
Rudolf JW, Thapa M, 2016 (Case report)	1	9-day-old female	Labored breathing, sweating on feeding, episodic stridor, tachypnea, neurologic decline (lower extremities weakness)	Left posterior mediastinum	2.4 × 4.7 × 2.9	Poorly differentiated (Schwannian-poor), low mitotic-karyorrhectic index (1%)	No N-MYC amplification	Thoracotomy with biopsy, radiation therapy, chemotherapy, and supportive care	Improvement in neurological function and respiratory status; follow-up MRI showed tumor regression	[18]
Ramachandran et al., 2025	1	2.5 years / Female	paraparesis, hypotonia, absent DTR, sensory loss, no cranial nerve deficit	Posterior mediastinum with intraspinal extension T5-L1	7.7 x 8.3 x 11.4 cm	Yolk sac tumor (YST)	Positive immunohistochemistry: SALL4, glypican 3; elevated serum AFP 29347 ng/ml	Emergency laminectomy + chemotherapy (PEb regimen: cisplatin, etoposide, bleomycin) + dexamethasone	neurological recovery, ambulant after two cycles; complete remission at 1 year post-treatment	
Yahya et al. (2019)	1	3 years old, Female	Flaccid paraparesis, dyspnea, cough, weight loss, opsoclonus-myoclonus eye movements	Posterior mediastinum with spinal canal extension D1-D8	8 x 6 x 5	Poorly differentiated neuroblastoma (small blue round cells, pseudorosettes)	Elevated urine VMA; bone marrow infiltration	Thoracotomy with en bloc tumor resection and spinal decompression; induction chemotherapy	Initial improvement post-op; death during chemotherapy induction	[19]

neuroblastoma, involved carboplatin, etoposide, cyclophosphamide, and doxorubicin. The patient met the criteria for the intermediate-risk group due to the tumor's stage 3 classification, characterized by an unresectable tumor crossing the midline. The intermediate-risk group, with a 5-year event-free survival (EFS) rate between 50% and 75%, is the rarest category, comprising only 9% of patients. In contrast, the high-risk group comprises 36.1% of patients and is associated with an EFS of less than 50% [31].

### 6.3. Literature Context

The patient in this case was younger than the typical age reported in the literature, where the median age ranges from approximately 2 to 4 years. Younger age is significant in neuroblastoma, often correlating with a better prognosis, which may explain the favorable outcome observed here [32]. Unlike the majority of cases, which frequently present with neurological symptoms such as paraplegia or weakness due to spinal cord compression, our patient exhibited respiratory distress possibly secondary to cardiac compression, manifesting as persistent pneumonia and wheezing. While respiratory symptoms are noted in some cases, these are typically linked to airway obstruction rather than cardiac involvement, making this presentation exceptional.

Neuroblastoma most commonly originates in the adrenal glands, with thoracic cases comprising about 20% of all neuroblastomas [33]. In cases of thoracic neuroblastoma, the posterior mediastinum is a known location of origin, as demonstrated by the present case. Histologically, the poorly differentiated neuroblastoma with small round blue cells aligns with many reported cases.

The patient was managed with the COG A3961 protocol for intermediate-risk neuroblastoma, involving chemotherapy without surgical resection. This approach yielded a good response, with no recurrence at follow-up. In contrast, the literature frequently describes surgical intervention, often combined with chemotherapy, particularly for tumors with spinal extension. For example, one study reported using laminectomy and chemotherapy, while another employed emergency intubation, chemotherapy, and subsequent surgery [34, 35].

### 6.4. Genetic and Prognostic Factors

MYCN amplification, present in 20–25% of neuroblastomas, upregulates LIN28B, promoting tumorigenesis and poor prognosis. In our case, MYCN was unamplified, indicating a more favorable risk profile despite

the tumor's aggressive anatomical behavior [22]. In this patient, despite being classified as intermediate-risk, the tumor's behavior—compressing the heart and causing persistent respiratory symptoms—underscores the potential severity of thoracic neuroblastomas. Regarding prognostic factors, the patient's younger age, absence of MYCN amplification, non-metastatic presentation, and thoracic location indicate a favorable prognosis [32, 36, 37]. Unfavorable factors, such as elevated LDH levels, were mitigated by her age and overall treatment success [38].

### 6.5. Lessons Learned

In children presenting with persistent respiratory symptoms unresponsive to standard treatments, it is essential to consider neuroblastoma as a potential underlying cause. This case highlights the critical role of comprehensive imaging—particularly echocardiography—which played a pivotal role in identifying an uncommon yet clinically significant complication involving cardiac compression caused by a posterior mediastinal mass.

In children presenting with persistent respiratory symptoms unresponsive to standard treatments, it is essential to consider neuroblastoma as a potential underlying cause. Conditions commonly associated with respiratory distress—such as pneumonia, pulmonary embolism, asthma exacerbation, ruptured cysts, and patients with a tracheostomy—should also be considered in the differential diagnosis when systemic signs or cardiopulmonary compromise are present [39, 40].

Notably, what initially appeared to be isolated respiratory distress may have been partly attributable to underlying cardiac compromise, underscoring that respiratory symptoms can sometimes reflect cardiovascular involvement rather than primary pulmonary pathology. The diagnostic process was further complicated by the tumor's unusual location and histological heterogeneity, which limited initial biopsy efficacy and necessitated thorough histopathological evaluation for definitive diagnosis. Furthermore, in cases where cardiac structures are already compromised by the tumor itself, the use of cardiotoxic agents such as doxorubicin—commonly included in neuroblastoma treatment protocols—demands particularly careful therapeutic planning to avoid exacerbating cardiac dysfunction.

The critical involvement of a multidisciplinary team, integrating pediatric cardiology, oncology, and radiology, was indispensable for both diagnosis and treatment, reinforcing the value of collaborative expertise in managing such atypical presentations. Additionally, the potential link

between neuroblastoma and congenital heart defects, possibly rooted in their shared neural crest origins, merits further consideration, particularly given the life-threatening implications of their coexistence in cases involving cardiac compression, thus concluding this discussion with a call for heightened awareness and interdisciplinary vigilance.

## 7. CONCLUSION

This case highlights the challenges of diagnosing and treating neuroblastoma in rare thoracic locations with cardiac involvement. Early diagnosis, precise imaging, and prompt treatment, utilizing the COG A3961 protocol, were crucial in preventing severe complications, underscoring the need for a collaborative approach.

## Acknowledgment

We thank our colleagues and co-authors for their invaluable contributions and expertise in both the clinical management of the patient and the preparation of this manuscript.

## Conflict of interest

The authors declare that there are no conflicts of interest regarding this case report.

## Ethical statement

Ethical approval for this case report was not required at our institution, as it was a clinical case managed during the patient's admission. Our institution does not issue ethics approval reference numbers for case reports. Written informed consent for publication of this case report and any accompanying images was obtained from the patient's legal guardians.

## References

- Vishwapriya Mahadev Godkhindi, M.M.B., Kamran Khan, Kiran Thorat, Adult Neuroblastoma-Case Report and Literature Review. *Journal of Clinical and Diagnostic Research*, 2016. 10(12): p. ED01-ED02.
- Davis, S., M.A. Rogers, and T.W. Pendergrass, The incidence and epidemiologic characteristics of neuroblastoma in the United States. *Am J Epidemiol*, 1987. 126(6): p. 1063-74.
- Heck, J.E., et al., The epidemiology of neuroblastoma: a review. *Paediatric and Perinatal Epidemiology*, 2009. 23(2): p. 125-143.
- Sbeih, A.H., et al., Epidemiological and Clinical Data in Low and Intermediate Risk Neuroblastoma: A Single Institution Experience and Survival Outcomes in Jerusalem. *Asian Pac J Cancer Care*, 2020. 5(3): p. 139-144.
- Ait Si Abdessadeq J, C.H., Ouassil S, Ahmanna H, Zouita B, Basraoui D, et al., Posterior Mediastinal Neuroblastoma in Children: An Unusual Location. *Scholars J Med Case Rep.*, 2025. 13: p. 1121-1124.
- Singh, V., L. Tyngkan, and A.R. Bhat, Rare Atypical Presentation of a Neuroblastoma of Posterior Mediastinum. *Int J Recent Surg Med Sci*, 2021. 7.
- Bargujar, P., J. Upadhyay, and H.R. Pahadiya, Posterior mediastinal neuroblastoma presenting with spinal cord compression as oncology emergency. *J Pediatr Crit Care*, 2023. 10(4).
- Feki, J., et al., An uncommon breast metastasis of mediastinal neuroblastoma within a child: A case report. *Breast J*, 2021. 27(4): p. 377-379.
- Ko, S.F., et al., Juvenile fibromatosis of the posterior mediastinum with intraspinal extension. *AJNR Am J Neuroradiol*, 1996. 17(3): p. 522-4.
- Atwal, S.S., Neuroblastoma of posterior mediastinum: classical imaging findings. *J Clin Diagn Res*, 2014. 8(10): p. Rj01.
- Kazemian, M., et al., Neonatal neuroblastoma presented with respiratory distress, a case report. *Respir Med Case Rep*, 2019. 28: p. 100874.
- McLatchie, G.R. and D.G. Young, Presenting features of thoracic neuroblastoma. *Arch Dis Child*, 1980. 55(12): p. 958-62.
- Stetsenko, T., et al., The case of Kinsburn's Encephalopathy in a child with neuroblastoma of posterior mediastinum. *Mod Pediatr Ukr*, 2024(1 (137)): p. 138-142.
- Tang, J., et al., Clinical characteristics and therapeutic outcomes of mediastinal neuroblastoma with intraspinal extension: a retrospective study. *Transl Pediatr*, 2021. 10(4): p. 715-722.
- Fatimi, S.H., S.A. Bawany, and A. Ashfaq, Ganglioneuroblastoma of the posterior mediastinum: a case report. *J Med Case Rep*, 2011. 5: p. 322.
- Kinsella, C., et al., Neuroblastoma and life-threatening tracheal obstruction: A case report and literature review. *Int J Pediatr Otorhinolaryngol Extra*, 2011. 6(3): p. 146-148.
- Ochi, T., et al., Successful all robotic-assisted excision of highly malignant mediastinal neuroblastoma in a toddler: A case report. *Asian J Endosc Surg*, 2023. 16(3): p. 542-545.
- Rudolf, J.W. and M. Thapa, Thoracic neuroblastoma. *Radiol Case Rep*, 2011. 6(2): p. 440.
- Yahya, F.S. and H.A. Al-Shami, Posterior mediastinal neuroblastoma masked as flaccid paraparesis in a 3 year child. *Neurosciences (Riyadh)*, 2019. 24(4): p. 320-323.
- Vantankhah, A., et al., A life-threatening encounter: an uncommon case of ruptured hydatid cyst presenting as anaphylactic shock and respiratory distress in a 12-year-old boy. *Annals of Medicine and Surgery*, 2023. 85(11): p. 5742-5747.
- Han, W. and H.M. Wang, Refractory diarrhea: A paraneoplastic syndrome of neuroblastoma. *World J Gastroenterol*, 2015. 21(25): p. 7929-32.
- Choi, J.H. and J.Y. Ro, Mediastinal neuroblastoma, ganglioneuroblastoma, and ganglioneuroma: Pathology review and diagnostic approach. *Semin Diagn Pathol*, 2022. 39(2): p. 120-130.
- Mitry, M.A. and J.G. Edwards, Doxorubicin induced heart failure: Phenotype and molecular mechanisms. *IJC heart & vasculature*, 2016. 10: p. 17-24.
- Carvalho, F.S., et al., Doxorubicin-induced cardiotoxicity: from bioenergetic failure and cell death to cardiomyopathy. *Med Res Rev.*, 2014. 34(1): p. 106-135.
- Wadia, S., Acute cyclophosphamide hemorrhagic myopericarditis: dilemma case report, literature review and proposed diagnostic criteria. *J Clin Diagn Res*, 2015. 9(11): p. OE01.

26. Weinberger, A., et al., Endocardial fibrosis following busulfan treatment. *JAMA*, 1975. 231(5): p. 495–495.
27. Hagenburg, J., et al., Pulmonary hypertension associated with busulfan. *Pulm Circ*, 2021. 11(4): p. 20458940211030170.
28. Feliz, V., et al., Melphalan-induced supraventricular tachycardia: incidence and risk factors. *Clin Cardiol*, 2011. 34(6): p. 356–9.
29. Ell, P., et al., Cardiotoxicity of Radiation Therapy: Mechanisms, Management, and Mitigation. *Curr Treat Options Oncol*, 2021. 22(8): p. 70.
30. Walls, G.M., et al., Cardiotoxicity following thoracic radiotherapy for lung cancer. *British Journal of Cancer*, 2025. 132(4): p. 311–325.
31. Mancilla, T.R., B. Iskra, and G.J. Aune, Doxorubicin-Induced Cardiomyopathy in Children. *Compr Physiol*, 2019. 9(3): p. 905–931.
32. Schmidt, M.L., et al., Favorable prognosis for patients 12 to 18 months of age with stage 4 nonamplified MYCN neuroblastoma: a Children's Cancer Group Study. *J Clin Oncol*, 2005. 23(27): p. 6474–80.
33. Conces, M.R., Peripheral neuroblastic tumors of the adrenal gland: clinicopathologic features and important molecular alterations. *Diagn Histopathol (Oxf)*, 2020. 26(5): p. 200–206.
34. Singh, V., L. Tyngkan, and A.R. Bhat, Rare Atypical Presentation of a Neuroblastoma of Posterior Mediastinum. 2021.
35. Kinsella, C., et al., Neuroblastoma and life-threatening tracheal obstruction: A case report and literature review. *International Journal of Pediatric Otorhinolaryngology Extra*, 2011. 6(3): p. 146–148.
36. Kojima, M., et al., Detection of MYCN amplification using blood plasma: noninvasive therapy evaluation and prediction of prognosis in neuroblastoma. *Pediatr Surg Int*, 2013. 29(11): p. 1139–45.
37. Häberle, B., et al., Characteristics and outcome of thoracic neuroblastoma. *Eur J Pediatr Surg*, 2002. 12(3): p. 145–50.
38. Moroz, V., et al., The prognostic strength of serum LDH and serum ferritin in children with neuroblastoma: A report from the International Neuroblastoma Risk Group (INRG) project. *Pediatr Blood Cancer*, 2020. 67(8): p. e28359.
39. Smith, D.K., D.P. Kuckel, and A.M. Recidoro, Community-acquired pneumonia in children: rapid evidence review. *American family physician*, 2021. 104(6): p. 618–625.
40. Ortiz-Alvarez, O., et al., Managing the paediatric patient with an acute asthma exacerbation. *Paediatrics & child health*, 2012. 17(5): p. 251–255.