

## Review

# Visual and Tumor Outcomes After Surgical Intervention in Optic Pathway Gliomas: A Systematic Review

Alivery Raihanada Armando<sup>1</sup>, Tedy Apriawan<sup>1,2\*</sup> , Maimanah Zumaro Umami Faiqoh<sup>1</sup>, Venansya Maulina Praba<sup>1</sup>, Ramadhani Rizki Zamzam<sup>1</sup>, Ramidha Syaharani<sup>1</sup>, Muhammad Zulfikar Salim<sup>1</sup>

<sup>1</sup>Faculty of Medicine, Universitas Airlangga, Surabaya, Indonesia.

<sup>2</sup>Department of Neurosurgery, Faculty of Medicine, Universitas Airlangga / Dr. Soetomo General Academic Hospital, Surabaya, Indonesia.



Scan and read the  
article online

**Citation** Armando AR, Apriawan T, Faiqoh MZU, Praba VM, Zamzam RR, Syaharani R, Salim MZ. Visual and Tumor Outcomes After Surgical Intervention in Optic Pathway Gliomas: A Systematic Review. Iran J Blood Cancer. 2025 June 30;17(2): 110-123.



### Article info:

Received: 06 May 2025  
Accepted: 13 June 2025  
Published: 30 June 2025

### Keywords:

Optic Nerve Glioma  
Neurosurgical Procedures  
Visual Acuity  
Recurrence

### Abstract

**Background:** Optic pathway gliomas (OPGs) are rare tumors predominantly affecting children and are often associated with neurofibromatosis type 1 (NF1). Their variable clinical course and critical visual and neuroendocrine pathway involvement present significant management challenges. This systematic review aims to evaluate the role of surgical intervention in OPGs, focusing on its impact on visual outcomes, postoperative tumor status, and treatment-related complications.

**Methods:** A systematic review was conducted following PRISMA guidelines. Data were extracted from peer-reviewed studies reporting surgical outcomes in OPG patients, including Dodge classification, type of surgical approach, intervention details, visual outcomes, tumor progression, progression-free survival (PFS), overall survival (OS), and complications.

**Results:** A total of 13 studies comprising 661 patients were included. Dodge Type III tumors were the most commonly reported. Surgical interventions included biopsy, subtotal resections, gross total resection (GTR), and debulking. Visual outcomes were variable; visual improvement was observed in a minority of cases, stable vision was the most commonly reported outcome, and others documented visual deterioration. Tumor status after surgery was stable in a majority of patients (up to 62,8%). Reported PFS and OS show 5-year OS rates ranging from 84.1% to 97.7% and PFS rates from 47.7% to 70.6%, indicating high survival with moderate variability in disease progression. Reported complications included visual loss, endocrine dysfunction, shunt failure, and mortality in a small subset.

**Conclusion:** Surgical intervention in OPGs is mainly diagnostic or decompressing. Visual improvement is uncommon; stability is more frequent. Aggressive surgery risks deterioration, highlighting the need for careful planning and standardized studies to guide management.

### \* Corresponding Author:

Tedy Apriawan

**Affiliation:** Faculty of Medicine, Universitas Airlangga, Surabaya, Indonesia & Department of Neurosurgery, Faculty of Medicine, Universitas Airlangga / Dr. Soetomo General Academic Hospital, Surabaya, Indonesia.

**E-mail:** [Drtedyapri@gmail.com](mailto:Drtedyapri@gmail.com)

## 1. INTRODUCTION

Optic pathway gliomas (OPGs) are low-grade developmental brain tumors originating from the pre-cortical optic pathways that can develop at any point along the visual pathways, involving the optic nerve, optic chiasm, optic tracts, optic radiations, or the hypothalamus. These rare tumors predominantly affect children, which usually presents earlier in life at less than five years of age, and are often associated with the inherited cancer predisposition syndrome neurofibromatosis type 1 (NF1). The occurrence of NF1 among patients with OPGs varies greatly, reported between 10% and 70%, with an average incidence of 29% (1,2).

The main treatment options for pediatric OPGs usually involve chemotherapy, radiotherapy, surgery, or a combination of these methods. Surgical intervention can provide critical information for both histopathological and molecular diagnoses. Surgery may be recommended in cases where the tumor causes significant symptoms, such as compression of the visual pathway leading to severe vision problems, pain, eye protrusion (exophthalmos), or hypothalamic infiltration by the glioma resulting in endocrine disruption and impact on nearby structures (3). Treating OPGs is complex due to their involvement with the visual pathways and closeness to critical areas of the brain, which leads to increased risk of significant neurological damage. The primary goals of surgery are to enhance or maintain vision, reduce the risk of complications, and alleviate the tumor's mass effect. Despite numerous studies investigating these outcomes, the results have been varied and inconsistent (4,5). This systematic review summarizes existing evidence regarding surgical approaches, outcomes, and complications in treating OPGs.

## 2. METHODS

### 2.1. Protocol and registration

We registered the protocol for this systematic review and meta-analysis in International Prospective Register of Systematic Reviews (PROSPERO: CRD42024625772) and adhered to the Preferred Reporting Items for Systematic Reviews and Meta-Analyses (PRISMA) guidelines.

### 2.2. Literature search and study selection

We conducted a comprehensive literature search in Google Scholar, PubMed Central, PubMed, ScienceDirect, Cochrane from December 4, 2014 to December 4, 2024. Keywords and Medical Subject Headings (MeSH) terms related to (optic nerve glioma) AND (pterial OR

subfrontal OR transcallosal OR orbitozygomatic OR keyhole) AND (gross total resection OR complication OR recurrence OR visual loss). Boolean operators ("AND," "OR") were used to refine the search.

### 2.3. Inclusion and exclusion criteria

We applied the PICOS (Population, Intervention, Comparison, Outcomes, Study Design) framework to define our study parameters. Studies that met the following criteria were eligible for inclusion: (1) studies on pediatric (aged 0-18 years) diagnosed with optic pathway gliomas (OPGs); (2) OPGs in patients with neurofibromatosis type-1 (NF1) and non-neurofibromatosis type-1 (non-NF1); (3) original paper, Randomized Controlled Trials (RCTs), cohort studies, and case control studies; and (4) studies that were written in English. Studies focused on adults or animal models were not included. We also excluded studies with incomplete or insufficient data on visual outcomes.

All search results were imported into Rayyan for de-duplication and screening. Six reviewers independently screened the titles and abstracts for relevance, followed by full-text assessments of potentially eligible studies. Any discrepancies in data extraction or bias assessment were resolved through discussion.

### 2.4. Data extraction

From each publication, information was extracted regarding first author, publication year, study location, Dodge classification, surgical approach, surgical intervention, non-surgical intervention, visual outcomes, tumor progression, PFS/OS, and complications. Surgical approach is classified into 3 categories: category 1 (midline/ interhemispheric/ callosal approaches), category 2 (lateral cortical/ sylvian approaches), and category 3 (orbital/fronto-orbital approaches). Gross total resection (GTR) was defined as the removal of more than 90% of the tumor volume, subtotal resection denotes the removal of 50-90% of the tumor volume, and debulking involves the removal of less than 50% of the tumor volume. We examined visual outcomes postoperatively (improved, stable, or deteriorated), tumor progression (stable/progressive),

### 2.5. Quality appraisal and publication bias assessment

The risk of bias was assessed using the Risk of Bias in Non-Randomized Studies-of Intervention (ROBINS-1) tool. Each study was judged as having low risk, moderate risk, or serious risk of bias across seven deviations domains: (1) Confounding; (2) Intervention Classification; (3)

Participant Selection; (4) Deviations from Interventions; (5) Missing Data; (6) Outcome Measurement; and (7) Reported Result Selection.

### 3. RESULT

#### 3.1. Literature search

We found 1283 studies from 5 databases. After removing 81 duplicates, we screened 1202 abstract studies and excluded 1179 studies because of following reasons (wrong study designs like systematic review, case report, literature review; did not describe optic pathway glioma and surgical approach). We dived through a full text review and decided to exclude 10 studies because of lack of data about surgical approach. We ultimately included 13 studies (Figure 1).

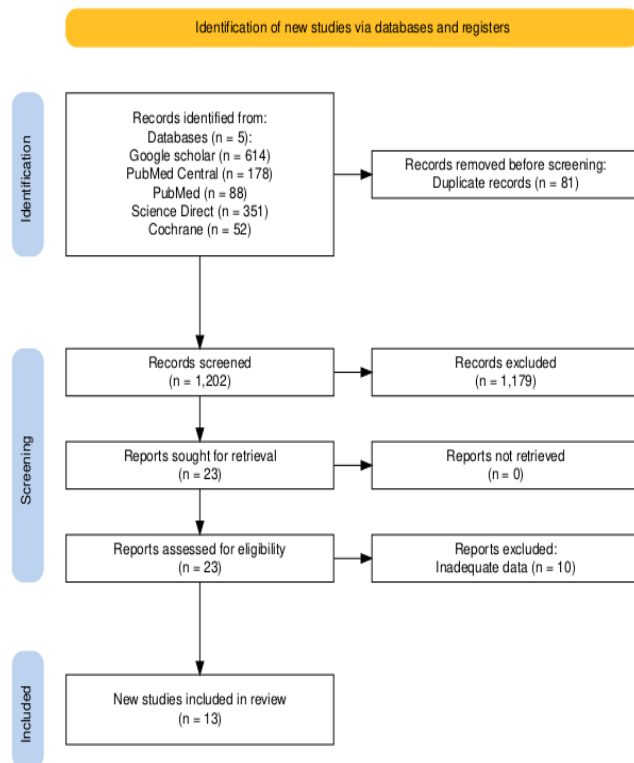


Figure 1. Flowchart of study selection.

Table 1 shows the characteristic of included studies. Karbe (6) presented the largest cohort with 63 patients, all classified as Dodge Grade III OPGs. Their multimodal approach combining surgery and chemotherapy achieved notable success, with 71% of patients experiencing visual improvement and 80% achieving stable tumor control.

Study	Risk of bias domains							Overall
	D1	D2	D3	D4	D5	D6	D7	
Karbe et al, 2024	⊖	⊕	⊖	⊕	⊕	⊖	⊕	⊖
Liao et al, 2020	⊖	⊕	⊖	⊕	⊕	⊖	⊕	⊖
Hill et al, 2021	⊖	⊕	⊖	⊕	⊕	⊖	⊕	⊖
Beltagy et al, 2016	⊖	⊕	⊖	⊕	⊖	⊖	⊕	⊖
Hidalgo et al, 2019	⊖	⊕	⊖	⊕	⊕	⊖	⊕	⊖
Zipfel et al, 2022	⊖	⊕	⊖	⊕	⊕	⊖	⊕	⊖
Yang et al, 2021	⊖	⊕	⊖	⊕	⊕	⊖	⊕	⊖
Abdulqader et al, 2018	⊖	⊕	⊖	⊕	⊕	⊖	⊕	⊗
Li et al, 2025	⊖	⊕	⊖	⊕	⊕	⊖	⊕	⊖
Menon et al, 2020	⊖	⊕	⊖	⊕	⊕	⊖	⊕	⊖
Li et al, 2024	⊖	⊕	⊖	⊕	⊕	⊖	⊕	⊖
Aihara et al, 2018	⊕	⊕	⊕	⊕	⊕	⊖	⊖	⊖
Liu et al, 2018	⊖	⊕	⊖	⊕	⊕	⊖	⊕	⊖

Domains:  
D1: Bias due to confounding.  
D2: Bias due to selection of participants.  
D3: Bias in classification of interventions.  
D4: Bias due to deviations from intended interventions.  
D5: Bias due to missing data.  
D6: Bias in measurement of outcomes.  
D7: Bias in selection of the reported result.

Judgement  
⊗ Serious  
⊖ Moderate  
⊕ Low

Figure 2. Risk of Bias of included studies using ROBINS-I tool.

Liao (7) studied 45 patients with exclusively Dodge Grade III tumors, employing surgery combined with radiotherapy. Their approach utilized predominantly Category 1 surgical approaches (91%) with universal subtotal resection. Visual outcomes were mixed, with only 25% showing improvement while 28% experienced deterioration. The study highlighted significant complications, including electrolyte imbalance (76%) and endocrine disorders (69%). Hill (8) examined the largest patient series with 121 subjects across various Dodge grades, though Grade III comprised 56% of cases. Despite combining surgery with chemotherapy, their outcomes were concerning, with 87% showing progressive disease. Visual improvement occurred in 50% of patients, but complication rates included endocrine deficiency (20%) and cognitive difficulties (16%) El Beltagy (9) analyzed 65 patients with mixed Dodge grades, using surgery and chemotherapy. Their approach achieved excellent tumor control (94% stable) and favorable survival (86% four-year overall survival). Visual outcomes were predominantly stable (63%) with minimal improvement (7%). Complications were relatively low, including diabetes insipidus (5%) and seizures (3%).

Hidalgo (10) focused on 82 patients, predominantly Dodge Grade III (91%), treated with surgery combined with chemotherapy or radiotherapy. All patients underwent

**Table 1.** Characteristics of included studies.

Author, year Title	Study design	Sample	Age at diagnosis	NF 1	Intervention	Conclusion
Karbe et al, 2024 Surgical options of chiasmatic hypothalamic glioma: a relevant part of therapy in an interdisciplinary approach for tumor control	Cohort	63	Mean: 4.6 years (range 0.2-16.9)	8	15 underwent cyst drainage, 27 received VP shunts, and 69.8% received non-surgical therapies (chemo, radio-, or targeted therapy).	Tumor debulking preserved but rarely restored vision, and despite 84.1% having a Karnofsky score $\geq 70$ , hormone deficiencies (30.2%) and vision issues still affected qol.
Liao et al, 2020 The Visual Acuity Outcome and Relevant Factors Affecting Visual Improvement in Pediatric Sporadic Chiasmatic/Hypothalamic Glioma Patients Who Received Surgery	Cohort	45	Mean: 6 years (P25=5.00, P25 =10.50)	0	Surgical approach: Longitudinal fissure, Transcallosal interforniceal and Subtemporal approach	IVA and tumor size correlate with partial resection; decompression is less effective for tumors $\geq 43.5$ cm <sup>3</sup> , but sub-50% resections remain safe and can improve vision.
Hill et al, 2020 Neurosurgical experience of managing optic pathway gliomas	Cohort	121	Mean: 1.8 years	21	Surgical intervention including biopsy, subtotal resection, gross total resection, cyst drainage, and omaya reservoir	Surgical patients had worse baseline and final vision but improved, especially in the better eye, highlighting a complex link between surgery and visual outcomes.
Beltagy et al, 2016 Treatment and Outcome in 65 Children with Optic Pathway Gliomas	Cohort	65	Mean: 5.3 years	20	Biopsy, debulking, and chemotherapy	Surgery for OPG mainly aids diagnosis and symptom relief, not cure. Chemotherapy after surgery helps stabilize tumors and preserve function. The combined approach showed good four-year survival, while surgery alone had limited impact.
Hidalgo et al, 2019 Long-term clinical and visual outcomes after surgical resection of pediatric pilocytic/pilomyxoid optic pathway gliomas	Case control, retrospective	83	Median 4 (0-20)	8	surgery as a first-line treatment compared with children with surgery as a second- or third-line treatment.	Surgical resection of OPGs offers moderate long-term benefits and good survival but risks deficits, helping about half of children, with limited value for those under two or with pilomyxoid tumors.
Zipfel et al, 2022 Surgical Management of Pre-Chiasmatic Intraorbital Optic Nerve Gliomas in Children after Loss of Visual Function?Resection from Bulbus to Chiasm	Cohort	10	Mean: 4.9 $\pm$ 3.88 Median 3.0	4	Surgical resection of Dodge I OPG tumor	Complete resection of Dodge I intraorbital OPGs via transfrontal or transorbital/supraorbital approaches is safe, effective, controls tumors well, avoids permanent damage, normalizes exophthalmos, relieves pain, improves cosmetics, and may eliminate chemo or radiation.
Yang et al, 2021 Comparison of two surgical methods for the treatment of optic pathway gliomas in the intraorbital segment: an analysis of long-term clinical follow-up, which evaluates the surgical outcomes	Case control Retrospective	86	Median at surgery 6 years (range 1-6)	0	surgical excision with and without incising the optic nerve sheath using the trans fronto-orbital approach	Resection of OPGs through an optic nerve sheath incision reduces postoperative complications and leads to better surgical outcomes
Abdulqader et al, 2018 Endoscopic transnasal resection of optic pathway pilocytic astrocytoma	Case series	4	Mean: 15.5 years	0	endoscopic endonasal approach	The endoscopic endonasal approach (EEA) offers direct access to OPGs with acceptable tumor resection and visual outcomes, though hypothalamic-pituitary dysfunction remains a key treatment limitation.

Li et al, 2025 The Use of Diffusion Tensor Imaging in the Differentiation and Surgical Planning of Suprasellar Hypothalamic-Opticohiasmatic Glioma and Craniopharyngioma in Children	Case series	13	Median: 3.92	0	Surgical excision including biopsy and partial resection	Both biopsy and partial resection in Dodge II and III OPG shows favorable outcome and reducing symptoms in most of the cases
Menon et al, 2020 Clinical presentation and outcome of patients with optic pathway gliomas: A series of twenty patients	Cohort, retro spective	20	Mean: 12.8 years	4	Tumor resection followed by adjuvant radiotherapy and chemotherapy	Surgery alone is insufficient for treating OPGs, emphasizing the need for more adjuvant therapy, which were underutilized in this cohort.
Li et al, 2024 Prechiasmatic Transection of the Unilateral Dodge Class I Optic Pathway Glioma without Neurofibromatosis Type 1: Technical Description and Clinical Prognosis	Cohort retro spective	12	Mean: 13.92 years	0	prechiasmatic resection without adjuvant treatments	For OPG Dodge I patients without NF-1, radical prechiasmatic resection of the tumor is possible, without the need for adjuvant therapy
Aihara et al, 2018 Pediatric Optic Pathway/Hypothalamic Glioma	Cohort retro spective (case series)	14	Mean: 12.57, Median: 11.5 ± 6.90	0	Tumor resection	Surgical treatment of Dodge III OPGs offers excellent long-term survival, but the risk of vision loss requires careful balance between tumor control and preserving function.
Liu et al, 2018 Analysis of Survival Prognosis for Children with Symptomatic Optic Pathway Gliomas Who Received Surgery	Retro spective	125	Mean: 6.7 (0.75-17)	3	Sub-total resection followed by adjuvant radiotherapy and chemotherapy	Postoperative radiotherapy, age over 3 years, and lower tumor grade predict better outcomes. In STR, chemo and radiotherapy help optimize results.

subtotal resection, achieving moderate visual improvement (11%) and stability (44%). Their long-term survival data showed 5-year progression-free survival of 55% and overall survival of 87%, with hormone deficits affecting 22% of patients.

Zipfel (11) reported on a smaller cohort of 10 patients using Category 3 surgical approaches with multimodal therapy. They achieved impressive gross total resection rates (70%) and tumor control (70% stable). Complications were primarily cosmetic, including enophthalmos and ptosis (20% each).

Yang (12) studied 86 patients with exclusively Dodge Grade III tumors, employing Category 3 microsurgical approaches with universal debulking. Their tumor control was excellent (98% stable), though visual outcomes were not reported. However, complications were substantial, with ptosis affecting 78% and upward eye movement disorders in 85% of patients (12).

Bin Abdulqader (13) presented the smallest series with 4 patients, all Dodge Grade III, treated with endoscopic surgery and radiotherapy. While visual outcomes remained stable in all patients, tumor control was achieved in 75%.

Complications were significant, including hydrocephalus (75%), hypopituitarism (50%), and meningitis (50%).

Li (14) examined 13 patients, predominantly Dodge Grade III (92%), using Category 1 surgical approaches. Their conservative approach included biopsy (31%) and subtotal resection (69%), achieving visual improvement in 15% and stability in 46%. Endocrine complications occurred in 15% of patients.

Menon (15) studied 20 patients with mixed approaches, predominantly Category 2 (90%). Despite surgery and radiotherapy, tumor control was mixed (45% stable, 55% progressive), though 86% achieved three-year overall survival. Visual stability was achieved in 75% of patients, with complications including hydrocephalus (20%) and infection (15%) (15). Li(16) presented unique outcomes in 12 patients with exclusively Dodge Grade I tumors using Category 3 approaches. Their complete resection strategy achieved universal tumor control and visual stability, with only transient ptosis affecting 42% of patients.

Aihara (17) studied 14 patients with all Dodge Grade III tumors using Category 1 approaches. They achieved tumor control and visual stability in 71% of patients with minimal endocrine complications (7%).

Liu et al (2018) analyzed the second-largest cohort with 125 patients across mixed Dodge grades, combining surgery with radiotherapy. Their extensive resection approach (82%) achieved good tumor control (77% stable) and

**Table 2.** Summary of the patient characteristics.

Study	N	Surgical Approach N(%)	Dodge Grade III N(%)	Primary Treatment	Extent of resection N(%)	Visual Outcome N(%)	Tumor Control N(%)	Survival (OS/PFS)	Major Complications N(%)
Karbe et al., (2024)	63	NR	Dodge III 63 (100%)	Surgery + Chemo	biopsy 20 (32%), Debulking 43 (68%)	42 (71%) Improved	47 (80%) Stable	4 (6%) Mortality	19 (33%) Hormone deficits
Liao et al., (2020)	45	Category 1 41(91%), Category 2 4(9%)	Dodge III 45 (100%)	Surgery + RT	STR 45 (100%)	improve eyes 23 (25%), stable 43(47%), deteriorated 24(28%)	NR	NR	34 (76%) Electrolyte imbalance, 31 (69%) endocrine disorder
Hill et al., (2021)	121	NR	Dodge I 12(9%), II 41(34%), III 68 (56.%)	Surgery + Chemo	GTR 4 (3%)	34 (50%) Improved	105 (87%) progressive	NR	10 (20%) Endocrine deficiency , 8 (16%) Cognitive difficulty
El Beltagy et al., (2016)	65	NR	Dodge I 18(27%), II 25(39%) III 22 (34%)	Surgery + Chemo	GTR 9 (14%)	5 (7%) improve, 41 (63%)stable	61 (94%) Stable	86% 4-yr OS	3 (5%) DI, 2 (3%) Seizures, 1(1%) pontine myelinolisis
Hidalgo et al., (2019)	82	NR	Dodge I 0(0%), II 7(9%), III 75 (91%)	Surgery + Chemo/RT	STR 82 (100%)	9 (11%) improved, 36 (44%) stable	NR	5-year PFS: 55% 10-year PFS: 46% 5-year OS: 87% 10-year OS: 78%	18 (22%) hormone deficit
Zipfel et al., (2022)	10	Category 3, 10 (100%)	NR	Surgery + Chemo/RT	GTR 7(70%)	NR	7 (70%) Stable	NR	2(20%) Enophthalmos, 2(20%) Ptosis
Yang et al., (2021)	86	Category 3, 86 (100%)	Dodge III 86(100%)	Microsurgery	debulking 86(100%)	NR	84 (98%) Stable	NR	67 (78%) Ptosis, 73 (85%) upward eye movement disorder,
Bin Abdulqader et al., (2019)	4	Category 1, 4 (100%)	Dodge III 4(100%)	endoscopic Surgery + RT	STR 4(100%)	4(100%) Stable	3(75%) Stable	NR	3(75%) Hydrocephalus, 2(50%) Hypopituitarism, 2(50%) meningitis 2 (15%) Endocrine
Li et al., (2025)	13	Category 1 13(100%)	Dodge I 0(0%), II 1(8%), III 12(92%)	Surgery	Biopsy 4 (31%), STR 9(69%)	improve 2(15%), stable 6(46%)	NR	NR	2 (15%) Endocrine
Menon et al., (2020)	20	Category 2 18(90%), Category 3 2(10%)	Dodge I 0(0%), III 4(20%)	Surgery + RT	2(10%)	15 (75%) Stable	9 45%) Stable, 11(55%) progressive	86% 3-yr OS	4(20%) Hydrocephalus, 3(15%) Infection
Li et al., (2024)	12	Category 3 12(100%)	Dodge I 12(100%), II(0%) , III 0(0%)	Surgery	12(100%)	12(100%) Stable	12(100%)Stable	NR	5(42%)Transient ptosis
Aihara et al., (2018)	14	Category 1 14(100%)	dodge III 14(100%)	Surgery	NR	10(71%) Stable	10(71%) Stable	NR	1(7%) Endocrine disorder
Liu et al., (2018)	125	NR	Dodge I 9(7%), II 72(58%), III 44(35%)	Surgery + RT	103 (82%)	NR	96(77%) Stable	84% 5-yr OS	56(45%) Transient Electrolyte disturbance, 16(13%) intracranial Infection

STR= Subtotal resection; GTR= Gross Total Resection; RT= Radiotherapy; PFS=Progression Free survival; OS= Overall Survival; NR= Not Replenishable

favorable five-year overall survival (84%). However, complications were notable, including electrolyte disturbances (45%) and intracranial infections (13%).

#### 4. DISCUSSION

Optic pathway glioma (OPG) is a rare neoplasm and a defining feature of neurofibromatosis type 1 (NF1), a tumor suppressor genetic disorder (18). OPG predominantly arises during childhood. The topographical classification of Dodge (19) can be used to describe the extension of OPG (grades I-III). Dodge I: tumor invasion is restricted to optic nerve, Dodge II: tumor invades the chiasm with or without invasion of the optic nerve(s), and Dodge III: tumor invades the optic tract with or without invasion of the hypothalamus (19). The modified Dodge classification helps clarify tumor location and predict clinical outcomes, including vision and hormonal dysfunction, especially in NF1-associated cases (20–22).

Optic pathway gliomas (OPGs) are managed using a multimodal approach that may include surgery, chemotherapy, radiotherapy, or combinations of these treatments, with some cases monitored without intervention as shown in **Table 2**. Treatment is complicated by the tumors' proximity to critical visual and brain structures. OPGs involving the optic chiasm are particularly prone to complications such as bitemporal vision loss and endocrine disorders like precocious puberty (20–22).

Surgery is indicated for removal of the tumor, also curative and was more frequently done previously, it is often impractical or discouraged because of the tumor's critical location and potential for significant complications. There is no doubt that surgical decompression is effective in certain circumstances: for large tumors, especially those causing hydrocephalus, for patients experiencing visual impairment due to compression of the visual pathway by tumors, and for individuals with endocrine dysfunction. In a cohort of young patients classified as high-risk due to poor prognosis, it has been observed that a positive treatment outcome can be attained through appropriate surgical decompression, also more effective with chemotherapy and/or radiotherapy. (5,23,24).

Radiation therapy is effective for optic pathway gliomas (OPGs) but is rarely used in clinical practice due to its severe side effects on vision, cognition, and hypothalamic functions. Positive outcomes have been shown in older children and adolescents, with 10-year progression-free survival rates of 69-89%, but it also led to long-term endocrine issues, cerebrovascular problems, poor visual

outcomes, secondary cancers, and cognitive impairments, particularly in younger patients with developing brains. Recent advancements in radiation techniques aim to minimize exposure to healthy tissues, including conformal treatment, fractionated stereotactic radiation therapy, proton beam therapy, and stereotactic radiosurgery. However, due to serious long-term side effects especially in younger children and those with NF1 it is reserved for select cases like unresectable tumors, low cognitive risk areas, or progressive disease unresponsive to chemotherapy (5,21,25). The combination chemotherapy of vincristine and carboplatin has emerged as the predominant first-line treatment for ONGs. In patients with NF1 receiving vincristine/carboplatin, the 3-year progression-free survival (PFS) rate stands at 77%. The treatment protocol is typically well accepted, although as many as 40% of patients may experience hypersensitivity reactions to carboplatin. An alternative treatment regimen that includes thioguanine, procarbazine, lomustine (CCNU), and vincristine (TPCV) demonstrated a nonsignificant trend towards enhanced event-free survival when compared to carboplatin/vincristine in patients with NF1. Nevertheless, individuals with NF1 have a higher susceptibility to leukemia, and there exists a risk of secondary leukemia associated with both CCNU and procarbazine. Therefore, while TPCV may be beneficial for patients with sporadic OPGs, it is advisable to avoid its use in those with NF1. The optimal treatment duration is unclear. While chemotherapy can slow tumor growth, it often does not lead to significant long-term recovery of visual function (2,5,25).

The relationship between Dodge classification and treatment approach is supported by several studies. Li (26) demonstrated that Dodge Grade I tumors could be effectively managed with surgery alone, achieving complete tumor control and visual stability. In contrast, studies focusing on Dodge Grade III tumors, such as Karbe (27), Liao (28), Hill (29), Hidalgo (30), and Yang (12), highlight the need for multimodal treatment combining surgery with chemotherapy and/or radiotherapy to improve outcomes. These Grade III cases often show mixed visual results, higher complication rates, and require more aggressive management. Other studies like El Beltagy (31) and Liu (32) on mixed Dodge grades also support the use of combined therapies for more advanced tumors.

The development of midline surgical approaches for optic pathway gliomas (OPGs) has evolved significantly over the past several decades, driven by the complex anatomical challenges these tumors present. Early in the evolution of

OPG surgery, most surgeons demonstrated a continued preference for medial approaches, likely due to the increased operating time and complexity required to manipulate the periorbital and lacrimal gland and to dissect through the fat compartment in the central surgical space (33). Contemporary data validates this historical preference, as evidenced by consistent adoption rates across multiple institutions: Liao (28) utilized midline approaches in 41/45 patients (91%), while Bin Abdulqader (34), Li (14), and Aihara (24) employed midline approaches exclusively in their respective cohorts of 4, 13, and 14 patients (100% each).

The anatomical rationale for midline approaches became increasingly clear as surgeons gained experience with OPG management. Winkler (35) provided early insights into the transcallosal interforaminal approach, demonstrating that this technique permitted definition of surgical approach pathways that preserve important anatomic structures, such as the motor strip, genu of the corpus callosum, fornical commissure (hippocampal commissure), anterior commissure, and fornical columns (35). However, these early studies also revealed significant limitations, as Winkler (35) reported that although the loss of verbal learning and recognition is difficult to quantify, it occurs in up to 25%–33% of patients after the transcallosal interforaminal approach. Modern clinical data corroborates these concerns, revealing that midline approaches are associated with endocrine complications in 15-76% of cases (including electrolyte imbalance and hypopituitarism), hydrocephalus in 20-75% of patients, and CNS infections in 15-50% of cases, highlighting the systemic morbidity profile that accompanies these techniques.

Building upon these foundational concepts, subsequent investigators refined the understanding of midline approach applications. The anterior interhemispheric translamina terminalis (AIHTL) approach was developed to address specific anatomical challenges, as Aihara (24) demonstrated that this technique enables surgeons to understand the anatomical relation between the tumor and hypothalamus, while acknowledging that the space under the optic nerves and chiasma remains blind (24). Notably, Aihara (24) clinical series of 14 patients with 100% Dodge Grade III tumors exclusively utilized midline approaches, demonstrating the preferential selection of this technique for high-grade, complex OPGs where hypothalamic preservation is paramount.

The application of midline approaches became more sophisticated with improved understanding of tumor growth patterns. (36) established that when tumors grow into the third ventricle, usually as an exophytic central

tumor component with hypothalamic tissue at the base and sides, the preferred approach to surgery is a midline transcallosal, interforaminal approach, to enter the third ventricle and visualize this exophytic tumor component within the third ventricle (36). This indication-specific approach represented a significant advancement in surgical planning and execution, moving beyond general preferences to evidence-based decision making that acknowledges the fundamental trade-off between visual and systemic complications.

Critical evidence supporting midline approaches emerged from comparative studies examining visual outcomes. Midline approaches, such as interhemispheric transcallosal and interhemispheric subfrontal approaches, may have advantages in preserving visual function, as the optic fibers are displaced lateral to OPGs (37). This finding was further substantiated by (38), which showed that without a midline approach, ipsilateral vision frequently deteriorates, while in their study of 34 tumor removal cases using midline approaches in 27 cases, deterioration of visual function after surgery occurred in only 3 cases Ahn (38). These findings align with contemporary understanding that midline approaches result in lower visual complications compared to orbital approaches, establishing a clear visual versus systemic trade-off where midline approaches accept higher endocrine and hypothalamic complications in exchange for preserved vision.

Samples provided a comprehensive analysis of the technical advantages of midline approaches, noting that the midline interhemispheric approach may be preferred when tumor debulking is focused on the third ventricle, as this approach facilitates identification of a plane between the tumor and the ventricular wall, which decreases the risk of hypothalamic injury. However, challenges associated with the interhemispheric approach include a relatively narrow operative corridor, risk of fornical injury, and difficulty visualizing/accessing inferior tumor, which is close to the optic pathway (39). Recent developments have introduced variations to traditional midline approaches. Mavridis (40) described how the anterior transcallosal transseptal interforaminal approach to the third ventricle, as a variation of the standard transcallosal interforaminal approach, has been considered applicable to other pathologies in the third ventricle or hypothalamic region and to be advantageous compared with standard transcallosal approach to the third ventricle (40). The understanding of approach angles, noting that a more medial and superior angle of attack can be achieved with this approach, allowing a panoramic view of the floor of the third ventricle, though the working distance of instruments is longer than in the trans-lamina

terminalis supra-tegmental approach (41). Modern literature acknowledges that the transcallosal interforaminal approach is associated with inherent complications, including cognitive deficits, emotional disturbances and short-term memory loss (41,42), confirming the contemporary clinical observation that midline approaches maintain visual function at the cost of higher endocrine and hypothalamic morbidity.

The evolution of lateral neurosurgical approaches demonstrates a complex interplay between technical innovation and clinical necessity spanning several decades. Goodden's early observations indicated that pterional approaches were strategically reserved for patients with significant lateral exophytic tumor components, establishing a precedent for selective application based on anatomical considerations rather than routine implementation (36).

As surgical techniques evolved, the trans-sylvian approach emerged as a refinement of lateral access methods. This approach provides access through a constrained surgical corridor bounded by the internal carotid artery, optic nerve, and infundibulum (43,44). This anatomical limitation fundamentally restricts visualization and access to medially positioned surgical targets, creating inherent technical challenges that influence surgical decision-making. The narrow working space identified by these authors correlates with the selective utilization patterns observed in contemporary series.

The morbidity profile associated with lateral approaches became more clearly defined through subsequent clinical studies. (45) research documented risk rates approaching 30% with trans-sylvian approaches, necessitating sacrifice of sylvian bridging veins. Uwaifo and Olli further characterized specific complications including increased rates of transient third nerve palsy, postoperative central diabetes insipidus, and hyperphagia. These findings provided objective data supporting the cautious application of lateral approaches observed in clinical practice.

Contemporary utilization patterns reflect this accumulated understanding of technical limitations and associated risks. Liao et al. (2020) demonstrated a conservative 9% utilization rate for lateral approaches, contrasting markedly with concurrent 90% utilization in the same year (46). This dramatic variance suggests significant institutional differences in case selection criteria or surgical philosophy rather than temporal evolution in technique.

Recent innovations continue to expand the applications of lateral approaches while acknowledging persistent limitations. Kondo's work on lateral approaches for optic nerve tumors demonstrated reduced hospitalization requirements compared to transcranial alternatives,

suggesting evolving clinical benefits (47). However, the narrow operative field constraints acknowledged by these authors highlight ongoing technical challenges that may influence surgeon preference. The systematic review findings of 20% hydrocephalus and 15% infection rates must be interpreted within this context of selective application and inherent technical complexity, suggesting that complication rates reflect the challenging nature of these procedures rather than inadequate technique.

The orbital and fronto-orbital approaches to optic pathway gliomas have undergone significant technical evolution, with contemporary data demonstrating their emergence as the predominant surgical strategy for specific tumor subtypes. Early descriptions of combined transcranial and orbital approaches, established the foundational concept of en bloc resection with preservation of the annulus of Zinn for debulking proptotic blind eyes (48).

The development of multiportal variants, as described by de Simone, represents a significant advancement in surgical sophistication. These approaches facilitate access to diverse anatomical territories including the middle cranial fossa, anterior cranial fossa, petrous apex, and cavernous sinus through orbital navigation. The transorbital endoscopic approach (ETOA) further refined these techniques by reducing temporal lobe retraction requirements and minimizing temporalis muscle mobilization, addressing previous limitations of extensive tissue manipulation (49).

Contemporary utilization patterns demonstrate remarkable consistency across multiple high-volume centers. Yang (50) series of 86 patients achieved 100% orbital approach utilization, representing the largest documented cohort. This pattern was replicated by Zipfel (51) (10/10 patients) and Li et al. (12/12 patients) respectively, suggesting widespread adoption of orbital approaches as the preferred technique (16). The notable exception in Menon (52) series (2/20 patients, 10%) likely reflects specific selection criteria or institutional preferences rather than temporal differences in technique availability.

The morbidity profile associated with orbital approaches reveals a distinct pattern of predominantly visual complications rather than systemic sequelae. Yang (53) comprehensive analysis documented ptosis in 77.9% of patients, with upward eye movement disorders affecting 84.9% of cases. Additional complications included downward movement disorders, abduction and adduction deficits (27.9% each), and conjunctival edema (29.1%). These findings align with the systematic review data demonstrating 78-85% rates of ptosis and eye movement disorders, establishing a consistent complication profile across multiple series.

The technical advantages of orbital approaches become apparent when considering their application to specific tumor characteristics. Supraorbital keyhole approaches for anterior skull base extensions demonstrate enhanced tissue collection capabilities compared to traditional stereotactic methods (54,55). Zipfel analysis revealed that while transorbital approaches with orbital rim removal provide adequate exposure for intraorbital tumor components, viewing angles remain insufficient for tumor removal extending from the conus into the optic canal (51).

The preferential use of orbital approaches for high-grade tumors, as identified in the systematic review, reflects the technical capability to achieve more extensive resections while maintaining acceptable morbidity profiles. The notably lower systemic complication rates (7-20%) compared to visual complications suggest that orbital approaches effectively minimize hypothalamic and vascular risks while accepting ocular morbidity as an acceptable trade-off for oncological control.

The management of pediatric optic pathway gliomas (OPGs) necessitates a careful consideration of post-surgical complications, which are significantly influenced by the extent of surgical intervention, tumor location (often correlated with Dodge classification), surgical technique, and specific tumor growth patterns. Evidence from the 13 studies included in this review indicates that more extensive resection surgeries are associated with a higher incidence of post-operative neurological deficits and complications impacting quality of life (6,7). These findings are supported by Goodden et al. (2014), who, while noting the potential efficacy of surgical debulking, reported a spectrum of surgical methods and associated risks, including a patient death from infective complications of a tumor biopsy and the frequent need for shunt insertion to manage hydrocephalus.

The anatomical location of the OPG plays a critical role in the type and likelihood of complications; tumors involving the optic chiasm and/or hypothalamus (Dodge types II and/or III) are associated with a higher risk of endocrine dysfunction, as detailed by (56), which corroborates the observations of Hill (29) regarding the exacerbation of pre-existing endocrine dysfunction following resection surgeries. Furthermore, complications such as hypopituitarism, meningitis, and CSF leak are specifically linked to approaches like the endoscopic transnasal method (13). The choice of surgical technique and the tumor's growth pattern also impact outcomes, with studies demonstrating lower morbidity with specific approaches like optic nerve sheath incision (12). Beyond these, a range of complications, including postoperative infection and visual

deterioration, often in the form of visual impairment changes or oculomotor nerve palsies resulting from optic nerve resection, are consistently reported (14,15,57). The high risk of vision loss from even diagnostic biopsies further underscores the critical balance between diagnostic certainty and the potential for iatrogenic damage to the visual pathway in OPG management (58). Collectively, these findings emphasize the complex decision-making process and the necessity for individualized treatment plans to mitigate post-surgical risks while maximizing therapeutic benefits in this vulnerable pediatric population.

In conclusion, the surgical management of OPGs in children is fraught with potential complications, spanning visual deficits, endocrine disturbances, and neurological issues. The complexity of the disease, its location, and the various treatment modalities all contribute to the variability in outcomes. Advances in surgical techniques (e.g., DTI guided surgery) and a thorough understanding of the tumor's characteristics and Dodge classification are crucial in mitigating these complications and improving patient outcomes. A multidisciplinary approach, as mentioned by Aihara (17), is vital to optimize treatment strategies and minimize long-term sequelae.

#### 4.1. Visual outcome

Our data suggests that combination of surgery and chemotherapy generally offers a favorable outlook for visual improvement. Karbe (6) observed a substantial 71% improvement in vision even with less extensive resections like debulking or biopsy. This finding is reinforced by Hill (29), who reported 50% improvement despite a low gross total resection (GTR) rate. This indicates that chemotherapy, in conjunction with surgical decompression, actively contributes to visual recovery. However, the efficacy can be variable. El Beltagy (31) found 63% stable visual outcomes with only 7% visual improvement, even 9 out of 65 patients undergoing gross total resection (GTR). This suggests that factors beyond the treatment type, such as initial nerve damage and tumor characteristics, may influence the degree of visual recovery (59). Similarly, Hidalgo (30), employing sub-total resection (STR) with chemotherapy or radiotherapy as adjuvants, noted a mix of improved (11%) and stable (44%) visual outcomes. This variability underscores that the precise chemotherapy regimen, tumor characteristics, and the initial state of visual impairment likely modulate the extent of visual recovery. Combination of surgery and radiotherapy presents a more heterogeneous range of visual outcomes. While Liao (28) reported improvements (25%) and stable visual outcomes (47%) with STR, a significant proportion (28%) also

experienced visual deterioration. This highlights the potential for radiation-induced optic neuropathy, which can counteract the benefits of tumor decompression. This risk often makes treating teams reluctant to employ radiotherapy, especially now that chemotherapy and surgery have also demonstrated efficacy (36). In contrast, Menon (52) achieved 75% stable vision, and Bin Abdulqader (34) reported 100% stable vision with endoscopic surgery and radiotherapy, both primarily involving STR. The differences observed likely stem from variations in specific radiation parameters, tumor location, and patient characteristics.

Surgery alone or microsurgery primarily leads to stable visual outcomes, suggesting a role in preventing further decline rather than active improvement. Li (16) and Aihara (24) reported 100% and 71% stable visual outcomes respectively with surgical intervention. Li (14) also showed a majority 46% with stable vision and some improvement (15%). This indicates that surgical decompression alone can effectively stabilize vision, and in some cases, lead to improvement, potentially by alleviating mass effect (36,60). However, in NF-1 patients, surgical excision can inevitably cause blindness on the affected side (61). The role of surgery to improve vision remains unproven unless it addresses critically raised intracranial pressure or direct compression of optic nerves by a cyst (36). While surgical debulking has been described to preserve vision in cases of exophytic growth patterns or when neoplastic infiltration primarily involves meninges (62). Surgical resection alone for optic nerve tumors is often favored, as tumors involving the chiasm and optic pathways present a more difficult challenge (60).

The relationship between the extent of resection (EOR) and visual outcomes is not always straightforward. GTR might be expected to yield superior visual results due to maximal tumor removal, but the available data does not consistently support this. For example, Hill (8) reported 50% improved vision with a very low GTR rate (3%). Meanwhile, El Beltagy (63) observed predominantly stable (63%) and limited improved (7%) visual outcomes with a higher GTR rate (14%). This suggests that achieving GTR may not be the sole determinant of visual success. Instead, factors such as the initial state of the optic nerve, surgical techniques, and the impact of adjuvant therapies appear to be more critical (60). Conversely, Subtotal Resection (STR), debulking, or biopsy often demonstrate significant visual improvement, particularly when integrated with adjuvant therapies. Karbe (27) achieved a remarkable 71% improved vision with biopsy or debulking combined with chemotherapy. These findings highlight that even partial tumor removal can effectively alleviate optic nerve compression, with

subsequent chemotherapy or radiotherapy contributing to visual recovery by targeting residual tumor (60). Liao (7), with STR with radiotherapy, reported a mixed picture of improvements and deteriorations, underscoring the potential for radiation-related side effects. Similarly, Hidalgo (10), employing STR with chemotherapy/radiotherapy observed a combination of improved and stable outcomes. This emphasizes that even limited surgical intervention can initiate visual recovery by reducing mass effect, with adjuvant therapies playing a crucial role in enhancing and sustaining these benefits.

In conclusion, the evidence suggests that visual outcomes in pediatric OPGs are influenced by a complex interplay of primary treatment modalities and the extent of resection. While combination therapies, particularly surgery with chemotherapy, show promise for visual improvement, surgery alone tends to stabilize vision. Radiotherapy, while effective, carries a risk of visual deterioration. The extent of resection, especially STR or debulking combined with adjuvant therapies, can lead to significant visual recovery. Ultimately, the preservation of visual acuity is the primary goal of treatment (59,64,65). A personalized, multidisciplinary approach, with careful consideration of initial visual function and the specific risks and benefits of each treatment component, is essential for optimizing visual outcomes in children with OPGs (18,36,66). Poor visual function at presentation is often a predictor of poor final visual outcome (36).

## 5. LIMITATION

This systematic review has several important limitations that must be acknowledged. The included studies demonstrated significant heterogeneity in data reporting, with limited and inconsistent information on key variables such as optic pathway glioma grading systems, as not all studies consistently employed standardized tumor classification schemes. Variations in operator technique and surgical experience across different centers introduced potential confounding factors that may influence outcomes interpretation. Therefore, further studies are needed to discuss the relationship between surgical techniques used in OPG patients and postoperative visual outcomes. Future research should aim to distinguish between outcomes of patients with NF1 and those without NF1.

## 6. CONCLUSION

Surgical intervention in OPGs serves both diagnostic and therapeutic purposes but carries a risk of significant morbidity. Patient selection, tumor location, and surgical

approach are critical in optimizing outcomes. Multimodal management and individualized treatment planning remain essential. Further prospective, standardized studies are necessary to establish definitive guidelines.

#### Acknowledgment

The authors express their sincere gratitude to colleagues who provided valuable insights and constructive feedback throughout this research, and acknowledge the generous support of our respective institutions and the anonymous reviewers whose thoughtful comments strengthened this manuscript.

#### Conflict of interest

The authors declared no conflict of interest.

#### Funding

This study received no external funding

#### Ethical statement

This research did not involve ethical considerations.

#### References

- Huang M, Patel J, Gasalberti DP, Patel BC. Optic Nerve Glioma [Internet]. Vol. Updated 2024 Mar 26. StatPearls Publishing; 2024. Available from: <https://www.ncbi.nlm.nih.gov/books/NBK557878/>
- Walker DA, Aquilina K, Spoudeas H, Pilotto C, Gan HW, Meijer L. A new era for optic pathway glioma: A developmental brain tumor with life-long health consequences. *Front Pediatr*. 2023 Mar 24;11:1038937.
- Modrzejewska M, Olejnik-Wojciechowska J, Roszyk A, Szychot E, Konczak TD, Szemitzko M, et al. Optic Pathway Gliomas in Pediatric Population—Current Approach in Diagnosis and Management: Literature Review. *J Clin Med*. 2023 Oct 24;12(21):6709.
- Albalkhi I, Shafqat A, Bin-Alamer O, Mallela AN, Gersey ZC, Fernandes Cabral D, et al. Complications and visual outcomes following surgical resection of pediatric optic pathway/hypothalamic gliomas: a systematic review and meta-analysis. *Childs Nerv Syst*. 2024 Jul;40(7):2033–42.
- Yousefi O, Azami P, Sabahi M, Dabecco R, Adada B, Borghei-Razavi H. Management of Optic Pathway Glioma: A Systematic Review and Meta-Analysis. *Cancers*. 2022 Sep 30;14(19):4781.
- Karbe AG, Gorodezki D, Schulz M, Tietze A, Gruen A, Driever PH, et al. Surgical options of chiasmatic hypothalamic glioma—a relevant part of therapy in an interdisciplinary approach for tumor control. *Childs Nerv Syst*. 2024 Oct;40(10):3065–74.
- Liao C, Zhang H, Liu Z, Han Z, Li C, Gong J, et al. The Visual Acuity Outcome and Relevant Factors Affecting Visual Improvement in Pediatric Sporadic Chiasmatic-Hypothalamic Glioma Patients Who Received Surgery. *Front Neurol* [Internet]. 2020 Aug 19 [cited 2025 Jun 6];11. Available from: <https://www.frontiersin.org/journals/neurology/articles/10.3389/fneur.2020.00766/full>
- Hill CS, Khan M, Phipps K, Green K, Hargrave D, Aquilina K. Neurosurgical experience of managing optic pathway gliomas. *Childs Nerv Syst ChNS Off J Int Soc Pediatr Neurosurg*. 2021 Jun;37(6):1917–29.
- El Beltagy MA, Reda M, Enayet A, Zaghoul MS, Awad M, Zekri W, et al. Treatment and Outcome in 65 Children with Optic Pathway Gliomas. *World Neurosurg*. 2016 May;89:525–34.
- Hidalgo ET, Kvint S, Orillac C, North E, Dastagirzada Y, Chang JC, et al. Long-term clinical and visual outcomes after surgical resection of pediatric pilocytic/pilomyxoid optic pathway gliomas. *J Neurosurg Pediatr*. 2019 Aug;24(2):166–73.
- Zipfel J, Tellermann J, Besch D, Bertelmann E, Ebinger M, Driever PH, et al. Surgical Management of Pre-Chiasmatic Intraorbital Optic Nerve Gliomas in Children after Loss of Visual Function—Resection from Bulbus to Chiasm. *Children*. 2022 Apr;9(4):459.
- Yang P, Liu HC, Qiu E, Wang W, Zhang JL, Jiang LB, et al. Comparison of two surgical methods for the treatment of optic pathway gliomas in the intraorbital segment: an analysis of long-term clinical follow-up, which evaluates the surgical outcomes. *Transl Pediatr*. 2021 Jun;10(6):1586–97.
- Bin Abdulqader S, Al-Ajlan Z, Albakr A, Issawi W, Al-Bar M, Recinos PF, et al. Endoscopic transnasal resection of optic pathway pilocytic astrocytoma. *Childs Nerv Syst ChNS Off J Int Soc Pediatr Neurosurg*. 2019 Jan;35(1):73–81.
- Li S, Xiao W, Tong Z, Li L, Zhang Y. The Use of Diffusion Tensor Imaging in the Differentiation and Surgical Planning of Suprasellar Hypothalamic-Opticohiasmatic Glioma and Craniopharyngioma in Children. *World Neurosurg*. 2025 Jan;193:474–82.
- Menon S, Menon G, Vyjayanth R, George N, Jagdish V. Clinical presentation and outcome of patients with optic pathway gliomas: A series of twenty patients. *Kerala J Ophthalmol*. 2020;32(3):271.
- Li W, Li M, Luo L, Hu Y, Liu X, Yang H, et al. Prechiasmatic Transection of the Unilateral Dodge Class I Optic Pathway Glioma without Neurofibromatosis Type 1: Technical Description and Clinical Prognosis. *World Neurosurg*. 2024 Jan;181:e648–54.
- Aihara Y, Chiba K, Eguchi S, Amano K, Kawamata T. Pediatric Optic Pathway/Hypothalamic Glioma. *Neurol Med Chir (Tokyo)*. 2018;58(1):1–9.
- Friedrich RE, Nuding MA. Optic Pathway Glioma and Cerebral Focal Abnormal Signal Intensity in Patients with Neurofibromatosis Type 1: Characteristics, Treatment Choices and Follow-up in 134 Affected Individuals and a Brief Review of the Literature. *ANTICANCER RES*. 2016;
- DODGE HW, Love JG, CRAIG WM, DOCKERTY MB, KEARNS TP, HOLMAN CB, et al. Gliomas of the optic nerves. *AMA Arch Neurol Psychiatry*. 1958;79(6):607–21.
- Hill CS, Khan M, Phipps K, Green K, Hargrave D, Aquilina K. Neurosurgical experience of managing optic pathway gliomas. *Childs Nerv Syst*. 2021 Jun;37(6):1917–29.
- Kebudi R, Yildirim UM, İribaş A, Tuncer S. Optic pathway gliomas in children: Clinical characteristics, treatment, and outcome of 95 patients in a single center over a 31-year period. Can we avoid radiotherapy? *Pediatr Blood Cancer*. 2024 Dec;71(12):e31337.
- Tang Y, Gutmann DH. Neurofibromatosis Type 1-Associated Optic Pathway Gliomas: Current Challenges and Future Prospects. *Cancer Manag Res*. 2023 Jul;Volume 15:667–81.
- Kebudi R, Yildirim UMM, Iribas A, Yaman Agaoglu F, Zulfikar OB. Diffuse midline gliomas in children: Does changing strategies change results? 2024;
- Aihara Y, Chiba K, Eguchi S, Amano K, Kawamata T. Pediatric optic pathway/hypothalamic glioma. *Neurol Med Chir (Tokyo)*. 2018;58(1):1–9.
- Farazdaghi MK, Katowitz WR, Avery RA. Current treatment of optic nerve gliomas. *Curr Opin Ophthalmol*. 2019;30(5):356–63.

26. Li W, Li M, Luo L, Hu Y, Liu X, Yang H, et al. Prechiasmatic Transection of the Unilateral Dodge Class I Optic Pathway Glioma without Neurofibromatosis Type 1: Technical Description and Clinical Prognosis. *World Neurosurg*. 2024 Jan;181:e648–54.
27. Karbe AG, Gorodezki D, Schulz M, Tietze A. Surgical options of chiasmatic hypothalamic glioma—a relevant part of therapy in an interdisciplinary approach for tumor control | *Child's Nervous System* [Internet]. 2024 [cited 2025 Jun 6]. Available from: <https://link.springer.com/article/10.1007/s00381-024-06498-2>
28. Liao C, Zhang H, Liu Z, Han Z, Li C, Gong J, et al. The Visual Acuity Outcome and Relevant Factors Affecting Visual Improvement in Pediatric Sporadic Chiasmatic–Hypothalamic Glioma Patients Who Received Surgery. *Front Neurol* [Internet]. 2020 Aug 19 [cited 2025 Jun 6];11. Available from: <https://www.frontiersin.org/journals/neurology/articles/10.3389/fneur.2020.00766/full>
29. Hill CS, Khan M, Phipps K, Green K, Hargrave D, Aquilina K. Neurosurgical experience of managing optic pathway gliomas. *Childs Nerv Syst*. 2021 Jun 1;37(6):1917–29.
30. Hidalgo ET, Kvint S, Orillac C, North E, Dastagirzada Y, Chang JC, et al. Long-term clinical and visual outcomes after surgical resection of pediatric pilocytic/pilomyxoid optic pathway gliomas. *J Neurosurg Pediatr*. 2019;24(2):166–73.
31. El Beltagy MA, Reda M, Enayet A, Zaghoul MS, Awad M, Zekri W, et al. Treatment and Outcome in 65 Children with Optic Pathway Gliomas. *World Neurosurg*. 2016 May;89:525–34.
32. Liu W, Liu R, Ma Z, Li C. Transcallosal Anterior Interformiceal Approach for Removal of Superior Midbrain Cavernous Malformations in Children: A Retrospective Series of 10 Cases in a Single Center. *World Neurosurg*. 2018 Oct 1;118:e188–94.
33. Blessing NW, and Tse DT. Optic nerve sheath fenestration: a revised lateral approach for nerve access. *Orbit*. 2019 Mar 4;38(2):137–43.
34. Bin Abdulqader S, Al-Ajlan Z, Albakr A, Issawi W, Al-Bar M, Recinos PF, et al. Endoscopic transnasal resection of optic pathway pilocytic astrocytoma. *Childs Nerv Syst ChNS Off J Int Soc Pediatr Neurosurg*. 2019 Jan;35(1):73–81.
35. Winkler PA, Weis S, Büttner A, Raabe A, Amiridze N, Reulen HJ. The Transcallosal Interformiceal Approach to the Third Ventricle: Anatomic and Microsurgical Aspects. *Neurosurgery*. 1997 May;40(5):973.
36. Goodden J, Pizer B, Pettorini B, Williams D, Blair J, Didi M, et al. The role of surgery in optic pathway/hypothalamic gliomas in children. *J Neurosurg Pediatr*. 2014;13(1):1–12.
37. Kim JW, Kim SK. The role of surgery for optic pathway gliomas in the era of precision medicine. *Childs Nerv Syst*. 2024 Oct 1;40(10):3075–83.
38. Ahn Y, Cho BK, Kim SK, Chung YN, Lee CS, Kim IH, et al. Optic pathway glioma: outcome and prognostic factors in a surgical series. *Childs Nerv Syst*. 2006 Sep 1;22(9):1136–42.
39. Samples DC, Mulcahy Levy JM, Hankinson TC. Neurosurgery for optic pathway glioma: optimizing multidisciplinary management. *Front Surg*. 2022;9:884250.
40. Mavridis I, Anagnostopoulou S. Stereotactic Localization of the Monro Foramen and the Safest Stereotactic Interformiceal Approach to the Third Ventricle: A Neuroanatomical Study. *J Neurol Surg Part Cent Eur Neurosurg*. 2015 Oct 28;77(02):102–10.
41. Kong L, Xiao X, Pan C, Zhang L. Trans-lamina terminalis supratentorial approach for ventral midbrain lesions: Technical note. *J Clin Neurosci*. 2021 Jan 1;83:25–30.
42. Liu J, Wang P, Tang C, Jiang HT, Zhang G, Wu N. Endoscopic endonasal transsphenoidal approach for craniopharyngioma: A case report. *Exp Ther Med*. 2023;25(3):114.
43. Bulsara KR, Knopf J, Calafiore R, Moskalik AD. Neurosurgical Aspects of Hypothalamic Disease. *Hum Hypothal Anat Dysfunct Dis Manag*. 2021;171–80.
44. Uwaifo GI, editor. *The Human Hypothalamus: Anatomy, Dysfunction and Disease Management* [Internet]. Cham: Springer International Publishing; 2021 [cited 2025 Jun 6]. (Contemporary Endocrinology). Available from: <https://link.springer.com/10.1007/978-3-030-62187-2>
45. Ahmed M.A. Alselsly, M.D. ATM MD; Mohamed. Impact of Extent of Resection and Surgical Approach on Outcomes of Insular Gliomas. *Med J Cairo Univ*. 2023 Mar 1;91(03):297–304.
46. Menon S, Reddy V, Poduval AR, Menon G. Optimising surgical approaches to the orbit—a retrospective analysis of a series of forty orbital tumours. *Ophthalmol J*. 2021;6:124–36.
47. Kondo A, Akiyama O, Suzuki M, Arai H. A novel surgical approach for intraorbital optic nerve tumors. *J Clin Neurosci*. 2019 Jan 1;59:362–6.
48. Shriver EM, Ragheb J, Tse DT. Combined transcranial-orbital approach for resection of optic nerve gliomas: a clinical and anatomical study. *Ophthal Plast Reconstr Surg*. 2012;28(3):184–91.
49. Xie B, Qin C, Zhang S, Zhang C, He Y, Tang G, et al. A novel classification for guiding the surgical approach for cranio-orbital lesions: a single institution case series of 45 cases and a literature review. *Neurosurg Rev*. 2024;47(1):71.
50. Yang D, Xu Z, Qian Z, Wang L, Nie Q, Ge J, et al. Chordoid glioma: a neoplasm found in the anterior part of the third ventricle. *J Craniofac Surg*. 2021;32(3):e311–3.
51. Zipfel J, Tellermann J, Besch D, Bertelmann E, Ebinger M, Driever PH, et al. Surgical management of pre-chiasmatic intraorbital optic nerve gliomas in children after loss of visual function—resection from bulbus to chiasm. *Children*. 2022;9(4):459.
52. Menon S, Menon G, Vyjayanth R, George N, Jagdish V. Clinical presentation and outcome of patients with optic pathway gliomas: A series of twenty patients. *Kerala J Ophthalmol*. 2020;32(3):271–7.
53. Yang P, Liu HC, Qiu E, Wang W, Zhang JL, Jiang LB, et al. Comparison of two surgical methods for the treatment of optic pathway gliomas in the intraorbital segment: an analysis of long-term clinical follow-up, which evaluates the surgical outcomes. *Transl Pediatr*. 2021 Jun;10(6):1586–97.
54. Cho WS, Kim JE, Kang HS, Son YJ, Bang JS, Oh CW. Keyhole Approach and Neuroendoscopy for Cerebral Aneurysms. *J Korean Neurosurg Soc*. 2017 May;60(3):275–81.
55. Whan Kim J. Optic pathway glioma: outcome and prognostic factors in a surgical series | *Child's Nervous System* [Internet]. [cited 2025 Jun 4]. Available from: <https://link.springer.com/article/10.1007/s00381-006-0086-7>
56. Santoro C, Perrotta S, Picariello S, Scilipoti M, Cirillo M, Quaglietta L, et al. Pretreatment Endocrine Disorders Due to Optic Pathway Gliomas in Pediatric Neurofibromatosis Type 1: Multicenter Study. *J Clin Endocrinol Metab*. 2020 Jun 1;105(6):e2214–21.
57. Parness-Yossifon R, Listernick R, Charrow J, Barto H, Zeid JL. Strabismus in patients with neurofibromatosis type 1—associated optic pathway glioma. *J Am Assoc Pediatr Ophthalmol Strabismus*. 2015 Oct;19(5):422–5.
58. Beres SJ, Avery RA. Optic Pathway Gliomas Secondary to Neurofibromatosis Type 1. *Semin Pediatr Neurol*. 2017 May;24(2):92–9.

59. Azizi AA, walker david, Liu JF, Sehested A, Jaspan T. NF1 optic pathway glioma: analyzing risk factors... - Google Scholar [Internet]. 2021 [cited 2025 Jun 26]. Available from: [https://scholar.google.com/scholar?hl=id&as\\_sdt=0%2C5&q=NF1+optic+pathway+glioma%3A+analyzing+risk+factors+for+visual+outcome+and+indications+to+treat&btnC=](https://scholar.google.com/scholar?hl=id&as_sdt=0%2C5&q=NF1+optic+pathway+glioma%3A+analyzing+risk+factors+for+visual+outcome+and+indications+to+treat&btnC=)
60. Awdeh RM, Kiehna EN, Drewry RD, Kerr NC, Haik BG, Wu S, et al. Visual Outcomes in Pediatric Optic Pathway Glioma After Conformal Radiation Therapy. *Int J Radiat Oncol*. 2012 Sep 1;84(1):46–51.
61. Park ES, Park JB, Ra YS. Pediatric Glioma at the Optic Pathway and Thalamus. *J Korean Neurosurg Soc*. 2018 May;61(3):352–62.
62. Chen A, Yoon MK, Haugh S, Phan LT, Song J, McCulley TJ. Surgical management of an optic nerve glioma with perineural arachnoidal gliomatosis growth pattern. *J Neuro-Ophthalmol Off J North Am Neuro-Ophthalmol Soc*. 2013 Mar;33(1):51–3.
63. El Beltagy MA, Reda M, Enayet A, Zaghoul MS, Awad M, Zekri W, et al. Treatment and Outcome in 65 Children with Optic Pathway Gliomas. *World Neurosurg*. 2016 May;89:525–34.
64. Beres SJ, Avery RA. Optic Pathway Gliomas Secondary to Neurofibromatosis Type 1. *Semin Pediatr Neurol*. 2017 May 1;24(2):92–9.
65. Siwá A, Aufrata Ru, Vejmelková K, Pavelka Z, Zitterbart P. Neurofibromatosis Type 1 and Optic Pathway Glioma. *Czech Slovak Ophthalmol*. 2019 Jul 8;75(4):200–8.
66. Santoro C, Perrotta S, Picariello S, Scilipoti M, Cirillo M, Quaglietta L, et al. Pretreatment Endocrine Disorders Due to Optic Pathway Gliomas in Pediatric Neurofibromatosis Type 1: Multicenter Study. *J Clin Endocrinol Metab*. 2020 Jun 1;105(6):e2214–21.