

ALK- negative Anaplastic Large Cell Lymphoma of Bone

Soheila Zareifar 1 , Ahmad Monabati 2

1. Hematology Research Center, Namazee Hospital, Shiraz, Iran.

2. Department of pathology, Shiraz University of Medical Sciences, Shiraz, Iran.

Corresponding author: Soheila Zareifar, Hematology Research Center, Namazee Hospital, Shiraz, Iran. (Phone/Fax: (+98 711) 647 42 98, E-mail: zareifars@sums.ac.ir)

Keywords: Anaplastic Large Cell Lymphoma, Bone.

Introduction

Primary bone lymphoma (PBL) is a rare disease that was first described by Oberling in 1928.¹ The vast majority of PBL cases are non-Hodgkin lymphoma (NHL), whereas primary Hodgkin lymphoma (HL) of bone is extremely rare. PBL constitutes 7% of all malignant bone tumors, 4-5% of all extranodal NHL, and less than 1% of all malignant lymphomas.²⁻⁵ Patients with primary NHL of bone commonly present with local bone pain, soft tissue swelling, and a mass or pathological fracture. Osteomyelitis may imitate primary bone lymphomas.⁶ PBL can occur at any age, although there is particular tendency to affect older adults who are over 45-50 years of age. There is also a slight male predominance. Primary NHL of bone can arise in any part of the skeleton, but long bones (femur, tibia) are the most common sites of presentation.^{2,7}

According to the World Health Organization (WHO) classification, lymphomas involving bone are classified into four groups including Group I, lymphoma with a single bone involvement with or without any regional lymph node involvement; Group II, lymphoma with multiple bone sites, but no visceral or lymph node involvement; Group III, bone tumor with involvement of other visceral sites or lymph nodes at multiple sites; and Group IV, lymphoma involving any other sites and found on bone biopsy done to rule out possible involvement.³ Most cases of primary bone lymphomas (PBLs) are classified as diffuse large B-cell lymphomas (DLBCLs) in the WHO classification of

hematological malignancies. Bone scintigraphy is a valuable tool in staging of PBL. It detects multifocal involvement, which may alter prognosis and possibly the treatment. Moreover, clinically silent involvement of weight-bearing sites may be detected allowing for prophylactic treatment.⁹ Pediatric PBL-DLBCL has a favorable prognosis but remains poorly characterized.

Cases

Case 1

A 10 year-old boy was referred to our hospital with a history of left hip pain, fever, and limping for a few weeks. In physical examination, lymphadenopathy or hepatosplenomegaly was not detected, but he had a low grade fever. Laboratory data including complete blood counts, serum level of uric acid, calcium, phosphorous, alkaline phosphatase, and kidney and liver function tests were in the normal ranges, with elevated erythrocyte sedimentation rate (ESR, 75 mm/hr), and raised lactate dehydrogenase (560 U/L). His cerebrospinal fluid (CSF) aspiration, and bone marrow aspiration and biopsy were negative for any malignancy. The Tc⁹⁹ bone scan revealed multicentric active bone lesions in T4 vertebra, sacrum, and left acetabulum roof. In abdominal computed tomography (CT) scan, there were two well defined masses measured about 15, and 12 mm in inferior portion of inferior vena cava suggesting the possibility of lymphadenopathy. Biopsies of bone and abdominal lymph nodes were in favor of anaplastic

large cell lymphoma and null cell phenotype, composed of sheets of anaplastic cells arranged cohesive to each other. The individual cells were large with conspicuous nuclei, clumping of chromatin and variable amounts of cytoplasm. In immunohistochemical study, malignant cells were negative for CD3, CD5, CD7, CD43, CD15, CD20, CD79a, CD68 (KP1), CD138, CD296, anaplastic lymphoma kinase (ALK1), and neuron specific enolase (NSE), but positive for CD30 (Ber-H2), and EMA (E29). The patient was treated as a case of anaplastic large cell lymphoma (ALCL) according to BFM 90 protocol. At the end of treatment, he had normal LDH level (195 U/L), normal ESR (12 mm/hr), and normal abdomino-pelvic and chest CT scans, with resolution of bony defects in Tc⁹⁹ bone scan. The patient has been followed up since about 34 months ago.

Case 2

A 13 year-old boy was referred with history of right facial swelling for two months. He was treated as a case of dental abscess with no improvement. In physical examination, there was right maxillary swelling with a mobile tooth, and tenderness over proximal part of his right leg. Other examinations were unremarkable. The laboratory data including complete blood counts, biochemical studies, liver and kidney function tests, and lactate dehydrogenase level were normal except for high ESR (34 mm/hr). Radiography showed rarefaction in the right side of maxilla, loss of definition of lamina

dura around the teeth in that quadrant, and a bony defect between left upper fifth and sixth teeth. Bone marrow aspiration and biopsy, chest x-ray, abdomino-pelvic ultrasonography, chest and abdominal CT-scans were all normal. Computed tomography of jaw showed large lesion in the right maxilla (figure 1). Bone scan revealed foci of increased activity in the right tibia and maxilla (figure 2). Maxillary bone biopsy was in favor of ALCL, null cell type, with submucosal atypical infiltrate comprised of large atypical cells with irregular nuclei and prominent nucleoli (figure 3). Some atypical cells had indented atypical infiltrate which were positive for CD30 and admixed histiocytes were positive for CD68, but negative for T and B-cell markers CD3, CD5, CD7, CD43, CD20, CD79a, ALK, CD138, cytokeratin, and NSE (figures 4, 5).

He was also treated as a case of ALCL (BFM90 protocol). He had normal complete blood counts, liver and kidney function tests, LDH (258U/L), and ESR (21 mm/hr) at the end of chemotherapy. The Tc⁹⁹ bone scan revealed no active bone lesion in the right maxilla and tibia. He was disease free after 27 months at the last follow up.

Discussion

Anaplastic large cell lymphoma (ALCL) presenting as bone lesions is exceedingly rare.¹¹ ALCL represents approximately 2% of all NHLs according to the recent NHL classification project.¹² It is a distinct entity of NHL, characterized by a proliferation of

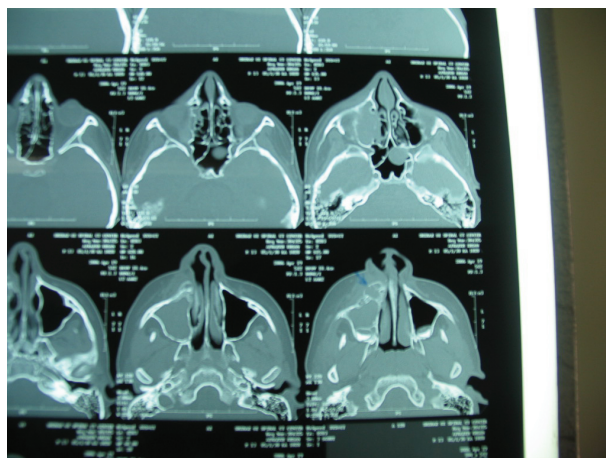


Figure 1. Maxillary views from CT scan of case No. 2 shows large lesion in right maxillary bone.

pleomorphic large lymphoid cells that express CD30, and classically is considered a clinicopathological entity separate from other nodal mature T-cell lymphomas (TCL).¹¹⁻¹⁴ ALCL commonly involves nodal as well as a wide variety of extra nodal sites, although primary or secondary involvement of bone is rare.¹² So, anaplastic large cell lymphoma should be considered a diagnostic possibility when evaluating neoplastic bone lesions in

children.¹⁴ EBV is likely unrelated to pathogenesis of this type of lymphoma.²¹ As defined in the revised European-American classification of lymphoid neoplasm (REAL), ALCL is a neoplasm of T-cell or null cell lineage; 20% to 60% of cases are associated with the translocation (2; 5) (p23, q35), resulting in a chimeric anaplastic lymphoma kinase (ALK) protein.¹²⁻¹⁶ In ALCLs positive for ALK protein, the ALK gene is most commonly fused to

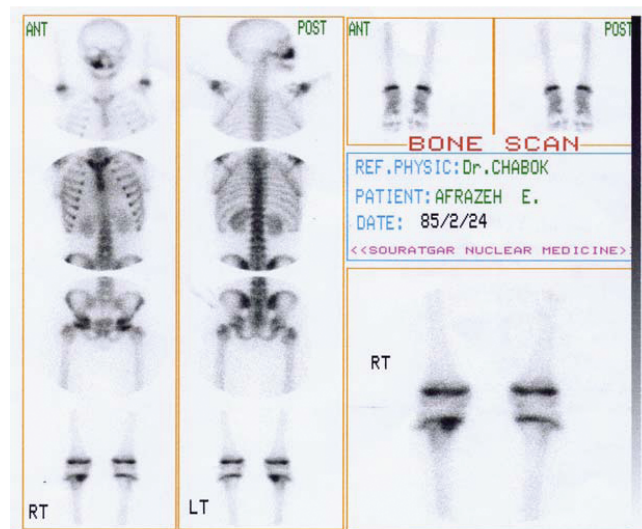


Figure 2. Tc 99 Bone scans of case No. 2 shows foci of increased activity in right tibia and maxilla.

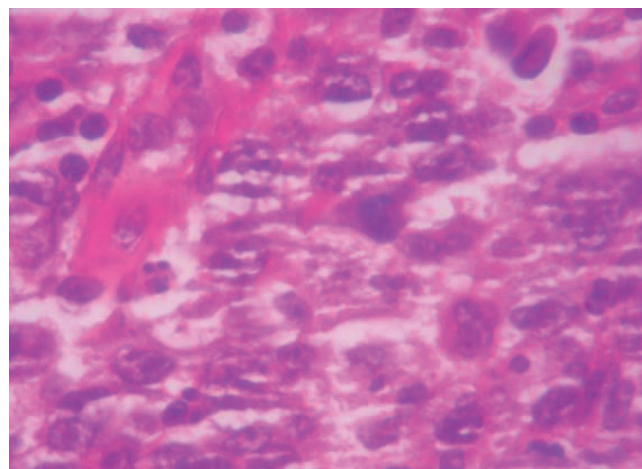


Figure 3. Anaplastic lymphoma: high power view of maxillary bone biopsy. Sheet of large atypical cells with irregular nuclei and prominent nucleoli.

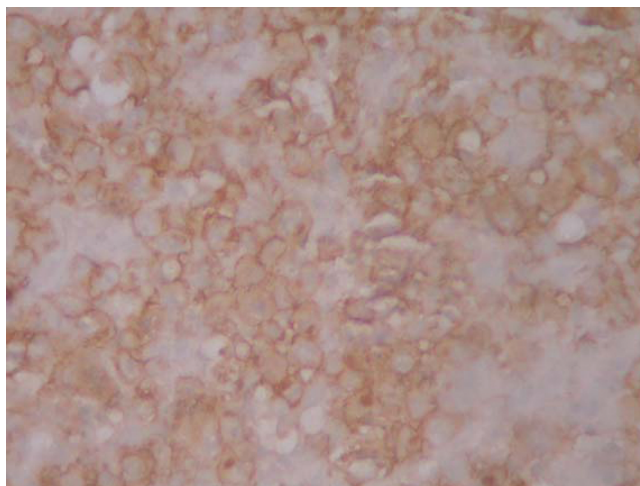


Figure 4. Immunohistochemical staining of bone biopsy for CD 30 (Ki-1). Anaplastic cells have positive reaction on surfaces and in the cytoplasm. X 400.

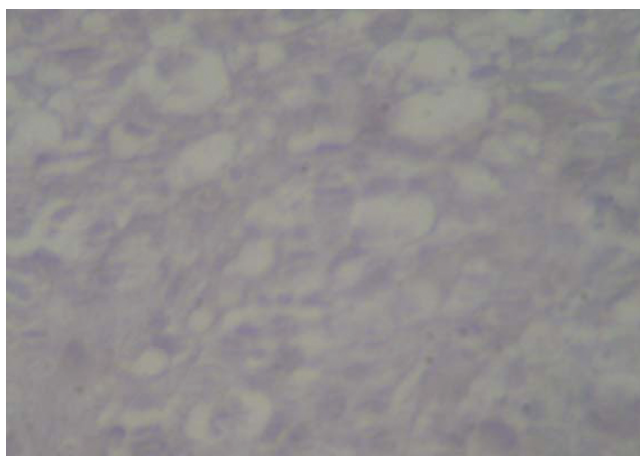


Figure 5. Immunostaining of maxillary bone biopsy shows no evidence of ALK antigen in tumor cells.

the NPM gene, and less commonly to TPM3, TFG, ATIC, and other rare genes.¹¹ Although this lymphoma is generally associated with a favorable clinical outcome, 25% of the patients die of the disease within five years.¹⁴⁻¹⁷ In a study, the monoclonal antibody ALKc (directed against the cytoplasmic portion of ALK) was used to detect expression of the ALK portion in paraffin-embedded biopsies from primary, systemic T/null cell anaplastic large-cell lymphomas, and the ALK staining pattern was correlated with morphological features, clinical findings, risk factors (as defined by the international prognostic index), and outcomes in most

patients.¹⁸ In a study by Glotzbecker et al on 15 cases with primary non-Hodgkin's lymphoma of bone, the most presenting complaint was pain and most patients had swelling and/or tenderness on physical examination. In this study, the femur and pelvis were the most frequently involved bones.⁸ Another study by Zhao et al showed that pediatric and adult PBL DLBCLs are distinct entities. He reported 10 pediatric cases with painful bone lesions, which were diagnosed often after months to years of symptoms, suggesting an indolent course.¹⁰ Gianelli et al examined 28 cases of primary bone

lymphomas and 26 cases of systemic lymphomas involving bone. They reported 3 cases of ALCL with null/T phenotype with ALK-1 expression.¹⁹ In another report of three cases of anaplastic large cell lymphoma of bone by Bakhshi et al, all cases showed unusually strong expression of NSE in addition to ALK.¹⁵

Maruyama et al, during a 10 years period, analyzed 28 consecutive patients diagnosed with PBL, who underwent chemotherapy and half received radiotherapy as their initial treatment. In their study, the most histopathological subtype was DLBCL, and they reported two cases of anaplastic large cell lymphoma too. The pelvis was the most frequently involved site (54%), and 68% of patients had stage IV of the disease. The histopathological subtypes and response to initial treatment were factors significantly affecting overall survival. The 3-year overall and progression-free survival rates were 84% and 77%, respectively.²⁰ A study by Zhouzy et al revealed that the clinical outcome of primary non-Hodgkin lymphoma of bone was relatively favorable and international prognostic indicators (IPI) and bcl-2 expression may serve as useful prognostic indicators. A further review of 11 ALCL cases with bony involvement treated in UK since 1990, including two cases with primary bone disease, did not suggest an unfavorable treatment outcome.²²

On the basis of comprehensive review of similar series in the literature involving patients with primary bone lymphoma, it appears that a younger age, advanced-stage of disease, multiple bone involvement, and non-large cell histology are associated with decreased survival as compared with an older age, localized disease, single bone involvement, and large cell histology, respectively.^{8,22} This finding will need to be confirmed by further studies on a larger cohort sample size with primary bone ALCL.

We identified only 12 reported cases of T and null-cell ALCL arising in bone while few of them involved a single bone site. Most of them were ALCL of the classic type, but our two cases are unique to our knowledge, because ALCL were localized to bone, tumor cells were negative for B or T-cell markers, and ALK did not contain the (2; 5) (p 23; q 35) translocation, with remarkable response to the treatment.

Acknowledgment

The authors would like to thank Dr. Elaine S. Jaffe for reviewing the submitted immunohistochemical stains, and the office of Vice Chancellor for Research of Shiraz University of Medical Sciences for financial support of this study and Dr. Davood Mehrabani at Centre for Development of Clinical Research of Nemazee Hospital for editorial assistance.

References

1. Oberling C. Les Reticulosarcomes et les reticuloendotheliosarcomes de la moelle osseuse (sarcomas d'Ewing). *Bull Assoc Fr Etude Cancer*. 1928; 17: 259-96.
2. Kitsoulis P, Vlychou M, Papoudou-Bai A, Karatzias G, Charchanti A, Agnantis NJ, et al. Primary lymphoma of bone. *Anticancer Res*. 2006; 26: 325-37.
3. Feltcher C, Unni K, Mertens F. Pathology and Genetics of tumors of soft tissue and bone: World Health Organization classification of tumors. Lyon, France: International agency for research on cancer; 2002. p. 306-8.
4. Freeman C, Berg J, Culter S. Occurrence and prognosis of extra nodal lymphomas. *Cancer*. 1972; 29: 252-60.
5. Isaacson P, Norton A. Extra nodal lymphoma in miscellaneous sites. In: Isaacson P, Norton A, editors. *Extra nodal lymphomas*. New York: Chirchill Livingstone; 1994. p. 289-98.
6. Hsich TC, Kao CH, Yen KY, Sun SS. Osteomyelitis –mimicking primary bone lymphoma at hip prosthetic site. *Clin Nucl Med*. 2007; 32: 543-4.
7. Maruyama D, Watanabe T, Beppu Y, Kobayashi Y, Kim SW, Tanimoto K, et al. Primary bone lymphoma: A new and detailed characterization of 28 patients in a single Institution study. *Jpn J Clin Oncol*. 2007; 37: 216-23.
8. Goltzbecker MP, Kersun LS, Choi JK, Wills BP, Schoffer AA, Dormans JP. Primary non-Hodgkin's lymphoma of bone in children. *J Bone Joint Surg*. 2006; 88: 583-94.
9. O'Connor AR, Birchall JD, O'Connor SR, Bessell E. The value of 99mTc-MDP bone scintigraphy in staging primary lymphoma of bone. *Nucl Med Commun*. 2007; 28: 529-31.
10. Zhao XF, Young KH, Frank D, Goradia A, Glotzbecker MP, Pan W, et al. Pediatric primary bone

lymphoma-diffuse large B-cell lymphoma: morphologic and immunohistochemical characteristics of 10 cases. *Am J Clin Pathol*. 2007; 127: 47-54.

11. Nagasaka T, Nakamura S, Medeiros LJ, Juco J, Lai R. Anaplastic large cell lymphomas presented as bone lesions. A clinicopathologic study of six cases and review of the literature. *Mod Pathol*. 2000; 13: 1143-9.

12. Lones MA, Sanger W, Perkins SL, Medeiros LJ. Anaplastic large cell lymphoma arising in bone: report of the monomorphic variant with the t (2, 5) (p23; q 35) translocation. *Arch Patol Lab Med*. 2000; 124: 1339-43.

13. Suzuki R, Kagami Y, Takeuchi K, Kami m, Okamoto M, Ichinohasama R, et al. Prognostic significance of CD56 expression for ALK- positive and ALK- negative anaplastic large cell lymphoma of T/null cell phenotype. *Blood*. 2000; 96: 2993-3000.

14. Li C, Takino H, Eimoto T, Ishida T, Inagaki A, Ueda R, et al. Prognostic significance of NPM- ALK fusion transcript over expression in ALK- positive anaplastic large cell lymphoma. *Mod Pathol*. 2007.

15. Bakhshi NA, Ross CW, Finn WG, Valdez R, Ruiz R, Koujok K, Schitzer B. ALK positive anaplastic large cell lymphoma with primary bone involvement in children. *Am J Clin Pathol*. 2006; 125: 57-63.

16. ten Berge RL, de Bruin PC, Oudejans JJ, Ossenkoppele GJ, Van der Valk P, Meijer CJ. ALK-negative anaplastic large cell lymphoma

demonstrates similar poor prognosis to peripheral T-cell lymphoma, unspecified. *Histopathology*. 2003; 43: 462-9.

17. Sherman CG, Zielenska M, Lorenzana AN, Pulford KA, Mason DY, Hutchison, RE, et al. Morphological and phenotypic features in pediatric large cell lymphoma and their correlation with ALK expression and the t(2,5) (p23;q35) translocation. *Pediatr.Deu Pathol*. 2001; 4: 129-37.

18. Falini B, Pileri S, Zinzani PL, Carbone A, Zagonel V, Wolf-Peeters C, et al. ALK+ lymphoma: Clinico-pathological findings and outcome. *Blood*. 1999; 93: 2697-706.

19. Gianelli U, Patriarca C, Moro A, Ponzoni M, Giardini R, Massimino M, et al. Lymphomas of the bone: a pathological and clinical study of 54 cases. *Int J Surg Pathol*. 2002; 10: 257 -66.

20. Maruyama D, Watanabe T, Beppu Y, Kobayashi Y, Kim SW, Tanimoto K, et al. Primary bone lymphoma: a new and detailed characterization of 28 patients in a single- institution study. *Jpn J Clin Oncol*. 2007; 37: 216-23.

21. Zhou ZY, Shi QL, Zou XJ, Lan JY, Wang JD, Huang WB, et al. Clinicopathologic features, prognosis and etiology of primary non-Hodgkin's lymphoma of bone. *Zhonghua Bing Li Xue Za Zhi*. 2007; 39: 90-3.

22. Ng A, Hobson R, Williams D, Morland B. Anaplastic large cell lymphoma of bone. Is it a bad tumor? *Pediatr Blood Cancer*. 2007; 48: 473-6.