

A Case of Hairy Cell Leukemia Associated with Hepatitis B Surface (HBs) Antigenemia and Concurrent Hepatitis C Virus (HCV) Seropositivity

Valizadeh N^{1*}, Rezaei Y¹

1-Urmia University of Medical Sciences, Urmia, Iran

*Corresponding Author: Valizadeh N, Email:Nsedaha0@gmail.com

Submitted: 29-09-2011, Accepted: 15-3-2012

Abstract

Literature review shows that hepatitis C infection may increase the risk of non-hodgkin lymphoma. Reactivation of hepatitis B infection has been reported in patients with hairy cell leukemia after chemotherapy and/or splenectomy. We present hepatitis B surface (HBs) antigenemia and concurrent hepatitis C virus (HCV) seropositivity in a case of hairy cell leukemia.

Key Words: Hairy cell leukemia, HBs antigen, HCV infection

Introduction

Hairy cell leukemia is a type of B-cell lymphoproliferative disorder. Literature review shows that the prevalence of HCV infection is higher in patients with B-cell non-hodgkin lymphoma than in control group ^{1,2,3} Spontaneous hematologic remission of hairy cell leukemia has been reported in the course of transfusion associated viral hepatitis and chronic hepatitis C infection due to endogenous interferon production ^{4,5}.

Some studeis show association between B-cell non-hodgkin lymphoma and HBV infection that suggest a possible role of HBV in the pathogenesis of non-hodgkin lymphoma ^{6,7}.

We present a case of hairy cell leukemia associated with HBs antigenemia and concurrent seropositivity for HCV antibody.

Report of the case

A 50 y/o male was admitted with huge splenomegaly and pancytopenia. Aspartate aminotransferase (AST), Alanine aminotransferase (ALT), Alkaline phosphatase (ALP), blood urea nitrogen (BUN), creatinine (Cr), albumin, prothrombin time (PT) and partial thromboplastin time (PTT), all were normal. Both HCV antibody and HBs Antigen were positive. Hepatitis B e antigen (HBe Ag) was negative.

White blood cell count was 3,800/ μ l, hemoglobin

level was 8.7gr/dl and platelet count was 41,000/ μ l. Abdominal sonography revealed massive splenomegaly. Peripheral blood smear showed many lymphocytes with cytoplasmic hairy projections (figure 1).

Findings of bone marrow aspiration (figure 2) and biopsy were compatible with hairy cell leukemia. We sent the bone marrow biopsy to another center for immunohistochemistry (IHC) staining for DBA44 which is specific for hairy cell leukemia and the IHC result was compatible with hairy cell leukemia. We started lamivudine for prophylaxis of hepatitis B virus activation and sent his blood sample for HCV

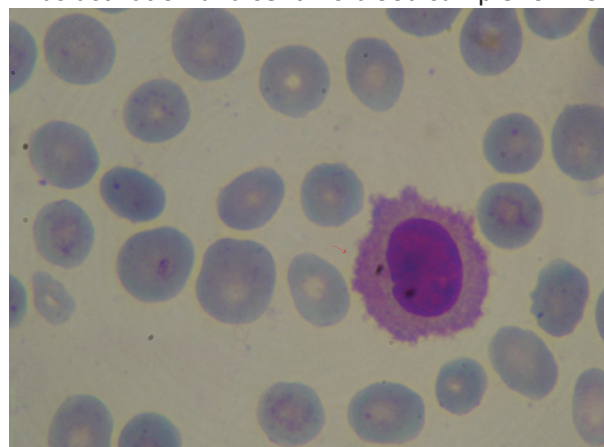


Figure 1: Peripheral blood smear shows many lymphocytes with cytoplasmic hairy projections

RNA before systemic chemotherapy. The result of HCV RNA with polymerase chain reaction (PCR) method was negative thus, we started systemic chemotherapy with 2-Chlorodeoxyadenosine (2-CDA). We found both HBs antigenemia and HCV Ab seropositivity in this case with Hairy cell leukemia.

Discussion

Hairy cell leukemia is a low grade B-cell lymphoproliferative disorder. Some studies show that the prevalence of HCV infection is higher in patients with B-cell non-hodgkin lymphoma than in control group ^{1,2,3} while, other studies show an association between HBV infection and B-cell lymphomas. Interferon alfa is approved by FDA in treatment of hairy cell leukemia, chronic hepatitis C infection and AIDS-related Kaposi's sarcoma and genital warts. There are multiple options in treatment of hairy cell leukemia. Purine nucleoside analogs including cladribine and pentostatin are the drugs of choice. Other effective agents include: interferon ⁸, rituximab as well as splenectomy ⁹. Severe reactivation of hepatitis B virus infection has been reported in patients with hairy cell leukemia after chemotherapy and/or splenectomy and in patients with cancer after chemotherapy ^{10, 11}. Prophylaxis of HBV reactivation with lamivudine is an effective strategy in patients with cancer taking chemotherapy ^{12, 13}. Prophylaxis with lamivudine significantly diminishes the risk of HBV reactivation and the overall morbidity of cancer patients undergoing chemotherapy ^{14, 15}.

Finding association between hairy cell leukemia

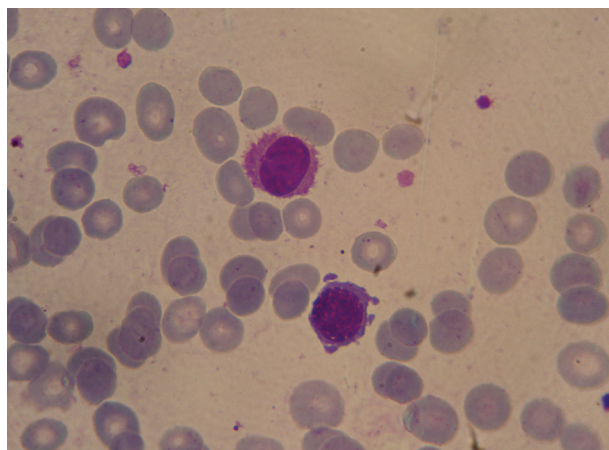


Figure 2: Findings of bone marrow aspiration

and HBs antigenemia suggests the possible role of hepatitis B virus in pathogenesis of hairy cell leukemia. Since, chemotherapy for hairy cell leukemia leads to viral replication in patients with HBs antigenemia thus; we should consider an efficient antiviral drug such as lamivudine for prophylaxis of hepatitis B reactivation in these patients and continue it until 6 months after chemotherapy. All patients with hairy cell leukemia and HCV seropositivity should be checked for HCV RNA. In patients with hairy cell leukemia and detectable HCV RNA copies and/or chronic hepatitis C infection, interferon alfa may be the drug of choice since it is effective against both hairy cell leukemia and hepatitis C infection.

References:

1. Zuckerman E, Zuckerman T, Levine AM, Douer D, Gutekunst K, Mizokami M, et al. Hepatitis C virus infection in patients with B-cell non-Hodgkin lymphoma. *Ann Intern Med.* 1997 15;127(6):423-8.
2. Mizorogi F, Hiramoto J, Nozato A, Takekuma Y, Nagayama K, Tanaka T, et al. Hepatitis C virus infection in patients with B-cell non-Hodgkin's lymphoma. *Intern Med* 2000;39(2):112-7.
3. Harakati MS, Abualkhair OA, Al-Knawy BA. Hepatitis C Virus infection in Saudi Arab patients with B-cell non-Hodgkin's lymphoma. *Saudi Med J.* 2000 ; 21(8):755-8.
4. Keefer MJ, Weber MJ, Bottomley SS, Solanki DL, Hosty TA. Peripheral blood remission of hairy cell leukemia after transfusion hepatitis. *Am J Hematol.* 1987; 25(3):277-84.
5. Morant R, Thürlimann B, Jungi WF, Schmid L, Holdener E, Schmid U, et al. Peripheral spontaneous remission of hairy cell leukemia following transfusion-associated hepatitis C. *Schweiz Med Wochenschr.* 1991; 121(10):344-6.
6. Park SC, Jeong SH, Kim J, Han CJ, Kim YC, Choi KS, et al. High prevalence of hepatitis B virus infection in patients with B-cell non-Hodgkin's lymphoma in Korea. *J Med Virol.* 2008; 80(6):960-6.
7. Kim JH, Bang YJ, Park BJ, Yoo T, Kim CW, Kim TY, et al. Hepatitis B virus infection and B-cell non-Hodgkin's lymphoma in a hepatitis B endemic area: a case-control study. *Jpn J Cancer Res.* 2002; 93(5):471-7.
8. Benz R, Stussi G, Fehr J. Interferon as an alternative to purine analogues in the treatment of hairy cell leukaemia. *Br J Haematol.* 2010; 148(4):664-5
9. Vosganian GS, Sigal DS, Saven A. Hairy cell leukemia:

current therapies and future directions. *Expert Rev Hematol.* 2010;3 (6):679-83.

10. Orlando R, Tosone G, Tiseo D, Piazza M, Portella G, Ciancia R, et al. Severe Reactivation of Hepatitis B Virus Infection in a Patient with Hairy Cell Leukemia: Should Lamivudine Prophylaxis be Recommended to HBsAg-Negative, Anti-HBc-Positive Patients? *Infection*, 2006, 34(5): 282-284
11. Lau GK. Hepatitis B reactivation after chemotherapy: two decades of clinical research. *Hepatol Inter*, 2008; 2 (2): 152-162
12. Ziakas PD, Karsaliakos P, Mylonakis E. Effect of prophylactic lamivudine for chemotherapy-associated hepatitis B reactivation in lymphoma: a meta-analysis of published clinical trials and a decision tree addressing prolonged prophylaxis and maintenance. *Haematologica*. 2009; 94(7):998-1005.
13. Martyak LA, Taqavi E, Saab S. Lamivudine prophylaxis is effective in reducing hepatitis B reactivation and reactivation-related mortality in chemotherapy patients: a meta-analysis. *Liver Int.* 2008; 28(1):28-38.
14. Yeo W, Chan PK, Ho WM, Zee B, Lam KC, Lei KI, et al. Lamivudine for the prevention of hepatitis B virus reactivation in hepatitis B s-antigen seropositive cancer patients undergoing cytotoxic chemotherapy. *J Clin Oncol.* 2004 ; 22(5):927-34
15. Yeo W, Ho WM, Hui P, Chan PK, Lam KC, Lee JJ, Johnson PJ. Use of lamivudine to prevent hepatitis B virus reactivation during chemotherapy in breast cancer patients. *Breast Cancer Res Treat.* 2004; 88(3):209-15.