

# Metronomic Capecitabine for Elderly Advanced Gastric Carcinoma Patients Pretreated With One or Two Systemic Chemotherapy Lines

Halim A<sup>1\*</sup>

1. Department of Clinical Oncology and Nuclear Medicine, Faculty of Medicine, Mansoura University, Egypt.

**\*Corresponding Author:** Halim A , amalsalahm@yahoo.com

Submitted: 10-07-2012 , Accepted: 14-10-2012

## Abstract

**Background:** The aim of this study was to investigate the efficacy and safety of metronomic capecitabine chemotherapy in pretreated elderly patients with advanced gastric carcinoma.

**Patients and Methods:** Eligible patients were treated with capecitabine at a fixed dose of 1000mg daily until disease progression or toxicity. Endpoints were overall response rate, safety, progression-free survival and overall survival.

**Results:** Thirty eight patients were enrolled (June 2004 to October 2011) with a median age of 69 years. Two patients refused continuation due to deterioration of general condition; consequently, 36 out of 38 patients were assessed for response. No complete response was observed while 6 patients out of 36 patients (16.7%) achieved partial response, 13 (36.1%) showed stable disease and 17 (47.2%) showed progression of disease. The disease control rate (response rate + stability rate) was 52.8%. The most common hematologic adverse effects were neutropenia in 3 (8.3%), followed by mucositis in 2 (5.6%) patients. There was one reported case of neutropenic fever. The reported hand-foot syndrome cases were all lower than grade 3. There were no treatment-related deaths and treatment delays were observed in 8 patients. Symptomatic improvement was evident in 18 patients (50 %). Median follow-up period was 6.5 months. Median time to progression was 3 months (range: 0 to 7 months), while the median overall survival was 7 months (range: 3 to 15 months).

**Conclusion:** Metronomic capecitabine may be considered an effective and tolerable treatment option in elderly patients with pretreated advanced gastric cancer after the failure of previous lines of chemotherapy.

**Key words:** Metronomic, capecitabine, gastric, cancer, elderly.

## Introduction

Several randomized clinical trials have established the role of chemotherapy in treatment of patients with advanced gastric cancer (AGC). In the nineties of the previous century trials that compared chemotherapy plus best supportive care with best supportive care alone reported statistically significant longer survival in the former<sup>1,2</sup>. Moreover, the quality of life was proved to be statistically superior in the chemotherapy-treated group over the best supportive care alone<sup>3</sup>.

Metronomic chemotherapy refers to the frequent administration of chemotherapeutics at doses significantly less than the maximum-tolerated dose, with no prolonged drug-free breaks<sup>4</sup>. Antiangiogenic activity is more prominent

with exposure to low doses of chemotherapeutics when compared to their cyclic administration at the maximum-tolerated dose<sup>5</sup>. Capecitabine is an oral fluoropyrimidine which is enzymatically converted to 5-fluorouracil (5-FU), when absorbed from the gastrointestinal tract to be generated preferentially at the tumor site<sup>6</sup>. Metronomic capecitabine has been used as a single agent for several advanced tumors like gastrointestinal tract tumors and breast cancer after prior treatment failure<sup>7,8</sup>. This study aimed at investigating the efficacy and safety of metronomic capecitabine in elderly patients with AGC after failure of one or more chemotherapy regimens.

## Patients and Methods

This was a prospective, multicenter phase II trial. Patients above 65 years of age with histologically proven AGC were eligible to enter the study after failure of the first or second lines of treatment. Thirty eight patients were enrolled (June 2004 to October 2011). Two patients refused continuation due to deterioration of general condition; consequently, 36 out of 38 patients were assessed for response. All patients had at least one measurable lesion. Other eligibility criteria were: at least 4 weeks time elapsed since the prior chemotherapy or radiation therapy, life expectancy greater than 3 months, Eastern Cooperative Oncology Group (ECOG) performance status  $\leq 2$ , normal marrow and organ function (leukocytes  $\geq 3,000/\mu\text{L}$ , absolute neutrophil count  $\geq 1,500/\mu\text{L}$ , platelets count  $\geq 100,000/\mu\text{L}$ , total bilirubin within normal institutional limits, AST/ALT  $\leq 2 \times$  institutional upper limit of normal, creatinine within normal institutional limits). Cases with only

brain metastasis were excluded. The trial was approved by the local ethics committee. Written informed consent was required for all patients entering the study.

### Study Schedule

Before treatment, each patient had thorough medical history and physical examination performed. Also complete blood count, liver and renal function tests and electrolytes assessment, ECG, chest radiograph, computed tomography (CT) scanning of the abdomen and pelvis, and if indicated a bone scan were performed. Metronomic capecitabine was administered orally at a dose of 1000mg daily continuously until disease progression or toxicity. Biweekly Evaluation during treatment included physical examination, assessment of performance status, and complete laboratory profile. Treatment was interrupted in patients with grade III or IV toxicity. Growth factors were given if indicated and

**Table 1:** Baseline clinicopathological characteristics for enrolled patients (n = 38)

Variable	No.	%
Median age	69 (range:67-75)	
Gender		
Male	28	73.7
Female	10	26.3
ECOG performance status		
0/1	21	55.3
2	17	44.7
Histology		
Adenocarcinoma, well differentiated	1	2.6
Adenocarcinoma, moderately differentiated	7	18.4
Adenocarcinoma, poorly differentiated	22	57.9
Signet ring cell carcinoma	8	21.1
No. of metastatic sites		
1	10	26.3
2	17	44.7
$\geq 3$	11	28.9
Organs involved		
Lymph nodes	14	36.8
Liver	6	15.8
Peritoneum	7	18.4
Lung	5	13.2
Bone	3	7.9
Abdominopelvic mass	7	18.4

**NB:** ECOG, Eastern Cooperative Oncology Group; PS, performance status; 5-FU, 5 fluorouracil.

not prophylactically. The study was continued until disease progression, unacceptable toxicity, or if the patients desired discontinuation of treatment.

### Response Evaluations

Response to treatment was evaluated every 8 weeks using the Response Evaluation Criteria in Solid Tumors<sup>9</sup>. Responses were required to last longer than 4 weeks. Toxicities were graded using the National Cancer Institute Common Terminology Criteria of Adverse Events version 3<sup>10</sup>. The end points of this study included clinical tumor response, treatment toxicity, and survival. Post-treatment toxicities were coded as the worst grade observed after the start of treatment. Symptomatic improvement was defined as subjective improvement of at least one tumor-related symptom (e.g., dysphagia, weight loss, loss of appetite and pain) without worsening of any other symptom or appearance of any new tumor-related symptom.

### Statistical Analysis

Patient characteristics and adverse events were presented as percentages or median values

with ranges. The Kaplan-Meier method was used to generate progression-free and overall survival curves. Progression-free survival was measured from the date of entry into the study until the date of progression or death. Overall survival was measured from the date of entry into the study until the date of death. The Log rank test was used to determine the statistical significance of difference between survival curves. Statistical analysis was performed using SPSS Software (Version 13.0, SPSS Co, Chicago, IL, USA).

## Results

### Patient characteristics

Thirty-eight eligible patients were enrolled during the predetermined period of study (from June 2004 to October 2011). Tables 1 and 2 list the baseline characteristics and previous treatments received respectively. Median age was 69 years (range:67 to 75 years).The majority of patients were male (28 patients representing 73.7% of the 38 patients entering the study).The most common site of disease was lymph nodes (37% ).The most common regimens used were 5FU –based regimens. First-line regimens were received by all

**Table 2:** Prior treatment of enrolled patients (n = 38)

<b>Surgery</b>	20(52.6)
Preoperative chemoradiotherapy(5-FU/cisplatin)	6 (15.8)
Postoperative chemoradiotherapy(5-FU/leucovorin)	4 (10.5)
Perioperative chemotherapy(epirubicin/cisplatin/5-FU)	5 (13.2)
First-line (epirubicin/cisplatin/5-FU)	9 (23.7)
First-line (paclitaxel/cisplatin)	9 (23.7)
First-line (5-FU /oxaliplatin )	6 (15.8)
First-line (paclitaxel/carboplatin)	7 (18.4)
First-line single agent paclitaxel	7 (18.4)
Second-line (irinotecan/5FU)	4 (10.5)
Second –line(irinotecan/cisplatin)	4 (10.5)

**Table 3:** Best overall response among 36 patients with measurable disease.

Response	No. patients	%
Complete response	0	0.0
Partial response	6	16.7
Stable disease	13	36.1
Progressive disease	17	47.2

cases while second-line regimens were received by 8 patients. Median time to tumor progression while on the preceding line received was 10 months.

#### Compliance and Response

Toxicity was assessed in all patients. However, 2 patients received just 2 weeks of treatment and then refused continuation due to worsening of their clinical condition. Consequently, 36 out of 38 patients were assessed for response. No complete response was observed while 6 patients (16.7%) achieved partial response. Thirteen patients (36.1%) showed stable disease and 17 patients (47.2%) showed progression of disease during treatment (Table 3). The disease control rate (response rate+stability rate) was 52.8%.

#### Tolerability

Treatment was well tolerated. Adverse effects are listed in Table 4. The most common hematologic grade 3 or 4 adverse effects were neutropenia in 3 patients (7.9%) followed by mucositis in 2 patients (5.3%). There was one reported case of neutropenic fever. The reported hand-foot syndrome cases were all of grade 1. No treatment-related death existed. Treatment delays were observed in 8 patients. Progression of disease was the cause of stopping treatment in 36 patients.

#### Symptomatic improvement and survival

Symptomatic improvement was evident in 18 of 36 patients (50 %). The median follow up period was 6.5 months. The median progression-

**Table 4:** Toxicities in 38 patients entering the study.

Toxicity type	Toxicity Grades			
	Grade1 n (%)	Grade2 n (%)	Grade3 n (%)	Grade4 n (%)
Neutropenia	10(26.3)	4 (10.5)	2 (5.3)	1(2.6 )
Anemia	6 (15.8)	2 (5.2)	1(2.6)	—
Thrombocytopenia	6 (15.8)	1 (2.6)	—	—
Anorexia	10 (26.3)	5 (13.2)	1 (2.6)	—
Neusea	5 (13.2)	1 (2.6)	—	—
Vomiting	3(7.9)	—	—	—
Abdominal pain	2 (5.3)	2(5.3)	—	—
Mucositis	6 (15.8)	4(10.5)	2(5.3)	—
Diarrhea	6 (15.8)	2(5.3)	1(2.6)	—
Hand -foot syndrome	6(15.8)	—	—	—
Liver	2 (5.3)	—	—	—
Sensory neuropathy	2 (5.3)	—	—	—
Fatigue	5 (13.2)	5(13.2)	1(2.6)	—

free and overall survivals were 3 months (range: 0 to 7 months) and 7 months (range 3 to 15 months) respectively.

## Discussion

During the 1980s, the reference treatment for advanced gastric carcinoma was the combination of 5-FU, doxorubicin and mitomycin C (FAM). In 1991, a randomized European Organization for Research and Treatment of Cancer (EORTC) clinical trial found that the 5-FU, doxorubicin and methotrexate combination (FAMTX) was superior to FAM<sup>11</sup>. In 1994, a similar randomized clinical trial found that the same was true of PELF regimen (cisplatin, epirubicin, leucovorin, 5-FU) designed by the Italian Oncology Group for Clinical Research (GOIRC)<sup>12</sup>. A number of relatively new agents (particularly the taxanes, irinotecan and oxaliplatin) have also been found to have significant activity in treatment of advanced gastric carcinoma<sup>13</sup>. As a consequence, a number of phase II and a few phase III trials have been conducted combining paclitaxel, docetaxel or irinotecan with 5-FU (plus or minus leucovorin), cisplatin or both<sup>14-16</sup>, and other phase II studies have combined oxaliplatin with 5-FU and leucovorin<sup>17</sup>.

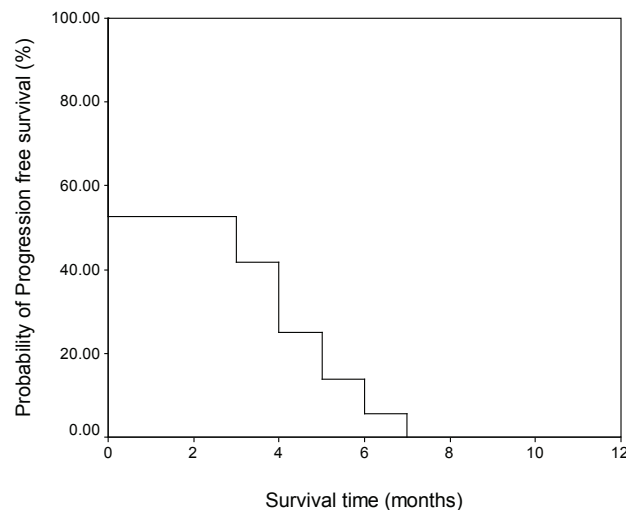
Long term administration of low doses of chemotherapy agents using more frequent administration schedules of cytotoxics and without breaks called metronomic delivery, has been used among patients to optimize the antiangiogenic effects of chemotherapy drugs and minimize their

toxicity<sup>18,19</sup>. This method is recognized as a tool for the treatment of different cancer types like breast cancer<sup>20</sup> prostate cancer<sup>21</sup>, vascular tumors<sup>22</sup>, melanoma<sup>23</sup>, and ovarian cancer<sup>24</sup>.

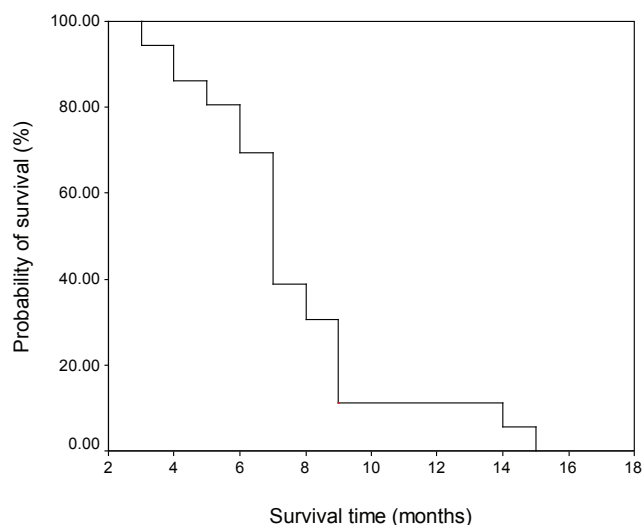
The results of the present study indicated that a clinically relevant fraction of AGC patients (52.8%) achieved disease control (response rate + stability rate). Our results are in line with the results of He et al.<sup>25</sup>. They evaluated metronomic capecitabine in 45 pretreated elderly AGC patients. The disease control rate was 51% and the median progression-free and overall survival times were 3.6 and 7.6 months respectively. In the absence of a control arm, it may be difficult to discriminate whether a stable disease is attributable to the treatment efficacy or an indolent behavior of the disease. However, all patients enrolled in this trial had a documented disease progression to previous treatment regimens before being registered.

The limited grade III and IV toxicities in the present study agrees with other trials using metronomic capecitabine alone like that of Ballardini et al.<sup>26</sup> who evaluated metronomic capecitabine at a dose of 1000mg daily in metastatic hepatocellular carcinoma associated with Child-Pugh class B cirrhosis and Fedele et al.<sup>27</sup> who evaluated metronomic capecitabine at a dose of 1500mg daily in 60 heavily pretreated patients with metastatic breast carcinoma.

Hand-foot syndrome is a relatively common, not life-threatening, toxic reaction to certain anticancer therapies, which can reduce patients' quality of life.



**Figure 1:** Progression –free survival of 36 patients



**Figure 2:** Overall survival of 36 patients finishing the study.

Dose modification of the inciting agent serves as the most effective management for this complication<sup>28</sup>. Phase II and III trials have shown that the incidence of grade 1 to 3 hand and foot syndrome with capecitabine treatment is generally in the range of 43% to 71% and the incidence of grade 3 has been observed in 5% to 24% of these patients<sup>29,30</sup>. In the present study we just observed grade one hand and foot syndrome with good response to topical emollients and oral systemic corticosteroids. No patients withdrew from treatment because of this toxic reaction.

An attractive extension of the present work could be testing the application of metronomic capecitabine combined with biological agents, in particular antiangiogenic drugs. Such combination is particularly appealing because high local concentration of vascular endothelial growth factor (VEGF) in the tumor environment has been found to promote multidrug resistance in tumor endothelium<sup>4,32,33</sup>. Hurwitz et al.<sup>34</sup> have reported a large study in which bevacizumab (humanized monoclonal antibody against VEGF) combined with standard chemotherapy regimens significantly improved survival for patients with advanced-stage metastatic colorectal carcinoma. These benefits may extend to the combination of antiangiogenic agents with metronomic regimens of cytotoxic agents aiming at a more tolerable toxicity profile. Combined therapy of continuous low dose capecitabine and high dose celecoxib targeting angiogenesis has been used in a phase II trial to

treat advanced cancer patients with different types of tumors<sup>35</sup>. Dynamic contrast-enhanced magnetic resonance imaging demonstrated a reduction of tumor vessel permeability and blood flow in patients who reached stable disease or some minor regression<sup>35</sup>. In another study forty six patients with advanced breast cancer were candidates to receive metronomic oral capecitabine, cyclophosphamide and bevacizumab. Overall response rate was 48% and the median time to progression was 42 weeks with generally mild toxicity<sup>37</sup>. Such extension of the present study should be in the form of a phase III study to be able to evaluate the real benefit of using biological agents.

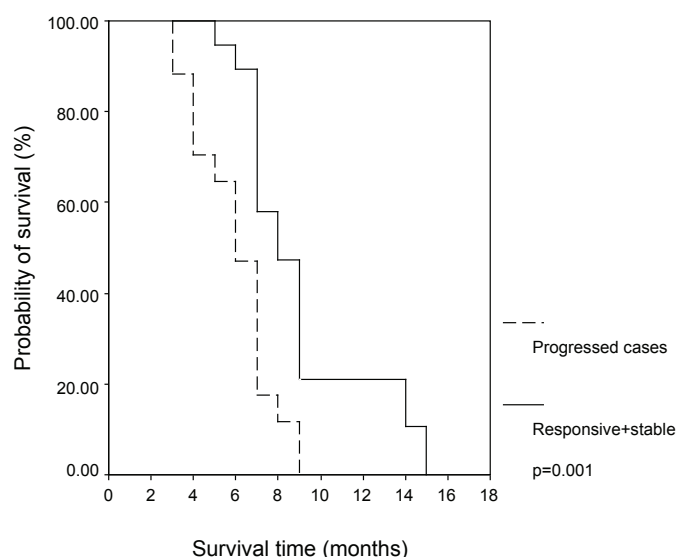
The median overall survival in the present study was 7 months a figure higher than that reported in relatively recent phase III trials of AGC<sup>37,38</sup>.

## Conclusion

Metronomic capecitabine may be considered an effective and tolerable treatment option in elderly patients with pretreated advanced gastric cancer after the failure of previous lines of chemotherapy. Nevertheless, further clinical studies, as well as a greater clinical experience are required in order to better define the role of the metronomic treatment strategy in medical oncology.

## Acknowledgments

We thank all patients participating in this study.



**Figure 3:** Overall survival of cases showing progression versus that of others.

## References

1. Murad AM, Santiago FF, Petroianu A, Rocha PR, Rodrigues MA, Rausch M. Modified therapy with 5-fluorouracil, doxorubicin, and methotrexate in advanced gastric cancer. *Cancer*. 1993;72(1):37-41.
2. Pyrhönen S, Kuitunen T, Nyandoto P, Kouri M. Randomised comparison of fluorouracil, epidoxorubicin and methotrexate (FEMTX) plus supportive care with supportive care alone in patients with non-resectable gastric cancer. *Br J Cancer*. 1995;71(3):587-91.
3. Glimelius B, Ekström K, Hoffman K, Graf W, Sjöden PO, Haglund U, et al. Randomized comparison between chemotherapy plus best supportive care with best supportive care in advanced gastric cancer. *Ann Oncol*. 1997;8(2):163-8.
4. Kerbel RS, Kamen BA. The anti-angiogenic basis of metronomic chemotherapy. *Nat Rev Cancer*. 2004;4(6):423-36.
5. Bocci G, Nicolaou KC, Kerbel RS. Protracted low-dose effects on human endothelial cell proliferation and survival in vitro reveal a selective antiangiogenic window for various chemotherapeutic drugs. *Cancer Res*. 2002;62(23):6938-43.
6. Miwa M, Ura M, Nishida M, Sawada N, Ishikawa T, Mori K, et al. Design of a novel oral fluoropyrimidine carbamate, capecitabine, which generates 5-fluorouracil selectively in tumours by enzymes concentrated in human liver and cancer tissue. *Eur J Cancer*. 1998;34(8):1274-81.
7. Petrioli R, Pascucci A, Francini E, Marsili S, Fiaschi AI, Civitelli S, et al. Continuous oral capecitabine at fixed dose in patients older than 75 years with metastatic colorectal and gastric cancer: a study of the Multidisciplinary Oncology Group on Gastrointestinal Tumors. *Anticancer Drugs*. 2008;19(1):91-6.
8. Taguchi T, Nakayama T, Masuda N, Yoshidome K, Akagi K, Nishida Y, et al. Study of low-dose capecitabine monotherapy for metastatic breast cancer. *Chemotherapy*. 2010;56(2):166-70.
9. Therasse P, Arbuck SG, Eisenhauer EA, Wanders J, Kaplan RS, Rubinstein L, et al. New guidelines to evaluate the response to treatment in solid tumors. European Organization for Research and Treatment of Cancer, National Cancer Institute of the United States, National Cancer Institute of Canada. *J Natl Cancer Inst*. 2000;92(3):205-16.
10. Trotti A, Colevas AD, Setser A, Rusch V, Jaques D, Budach V, et al. CTCAE v3.0: development of a comprehensive grading system for the adverse effects of cancer treatment. *Semin Radiat Oncol*. 2003;13(3):176-81.
11. Wils JA, Klein HO, Wagener DJ, Bleiberg H, Reis H, Korsten F, et al. Sequential high-dose methotrexate and fluorouracil combined with doxorubicin--a step ahead in the treatment of advanced gastric cancer: a trial of the European Organization for Research and Treatment of Cancer Gastrointestinal Tract Cooperative Group. *J Clin Oncol*. 1991;9(5):827-31.



12. Cocconi G, Bella M, Zironi S, Algeri R, Di Costanzo F, De Lisi V, et al. Fluorouracil, doxorubicin, and mitomycin combination versus PELF chemotherapy in advanced gastric cancer: a prospective randomized trial of the Italian Oncology Group for Clinical Research. *J Clin Oncol*. 1994;12(12):2687-93.
13. Hasham-Jiwa N, Kasakura Y, Ajani JA. Brief review of advances in the treatment of gastric carcinoma in North America and Europe, 1995-2001. *Int J Clin Oncol*. 2002;7(4):219-24.
14. Kim YH, Shin SW, Kim BS, Kim JH, Kim JG, Mok YJ, et al. Paclitaxel, 5-fluorouracil, and cisplatin combination chemotherapy for the treatment of advanced gastric carcinoma. *Cancer*. 1999;85(2):295-301.
15. Roth AD, Maibach R, Martinelli G, Fazio N, Apro MS, Pagani O, et al. Docetaxel (Taxotere)-cisplatin (TC): an effective drug combination in gastric carcinoma. Swiss Group for Clinical Cancer Research (SAKK), and the European Institute of Oncology (EIO). *Ann Oncol*. 2000;11(3):301-6.
16. Pozzo C, Barone C, Szanto J, Padi E, Peschel C, Bükki J, et al. Irinotecan in combination with 5-fluorouracil and folinic acid or with cisplatin in patients with advanced gastric or esophageal-gastric junction adenocarcinoma: results of a randomized phase II study. *Ann Oncol*. 2004;15(12):1773-81.
17. Louvet C, André T, Tigaud JM, Gamelin E, Douillard JY, Brunet R, et al. Phase II study of oxaliplatin, fluorouracil, and folinic acid in locally advanced or metastatic gastric cancer patients. *J Clin Oncol*. 2002;20(23):4543-8.
18. Man S, Bocci G, Francia G, Green SK, Jothy S, Hanahan D, et al. Antitumor effects in mice of low-dose (metronomic) cyclophosphamide administered continuously through the drinking water. *Cancer Res*. 2002;62(10):2731-5.
19. Bocci G, Francia G, Man S, Lawler J, Kerbel RS. Thrombospondin 1, a mediator of the antiangiogenic effects of low-dose metronomic chemotherapy. *Proc Natl Acad Sci U S A*. 2003;100(22):12917-22.
20. Orlando L, Cardillo A, Rocca A, Balduzzi A, Ghisini R, Peruzzotti G, et al. Prolonged clinical benefit with metronomic chemotherapy in patients with metastatic breast cancer. *Anticancer Drugs*. 2006;17(8):961-7.
21. Glode LM, Barqawi A, Crighton F, Crawford ED, Kerbel R. Metronomic therapy with cyclophosphamide and dexamethasone for prostate carcinoma. *Cancer*. 2003;98(8):1643-8.
22. Vogt T, Hafner C, Bross K, Bataille F, Jauch KW, Berand A, et al. Antiangiogenic therapy with pioglitazone, rofecoxib, and metronomic trofosfamide in patients with advanced malignant vascular tumors. *Cancer*. 2003;98(10):2251-6.
23. Spieth K, Kaufmann R, Gille J. Metronomic oral low-dose treosulfan chemotherapy combined with cyclooxygenase-2 inhibitor in pretreated advanced melanoma: a pilot study. *Cancer Chemother Pharmacol*. 2003;52(5):377-82.
24. Garcia AA, Hirte H, Fleming G, Yang D, Tsao-Wei DD, Roman L, et al. Phase II clinical trial of bevacizumab and low-dose metronomic oral cyclophosphamide in recurrent ovarian cancer: a trial of the California, Chicago, and Princess Margaret Hospital phase II consortia. *J Clin Oncol*. 2008;26(1):76-82.
25. He S, Shen J, Hong L, Niu L, Niu D. Capecitabine "metronomic" chemotherapy for palliative treatment of elderly patients with advanced gastric cancer after fluoropyrimidine-based chemotherapy. *Med Oncol*. 2012;29(1):100-6.
26. Ballardini P, Marri I, Margutti G, Aliberti C, Benea G, Manfredini R. Long-lasting response with metronomic capecitabine in advanced hepatocellular carcinoma. *Tumori*. 2010;96(5):768-70.
27. Fedele P, Marino A, Orlando L, Schiavone P, Nacci A, Sponziello F, et al. Efficacy and safety of low-dose metronomic chemotherapy with capecitabine in heavily pretreated patients with metastatic breast cancer. *Eur J Cancer*. 2012;48(1):24-9.
28. Hoesly FJ, Baker SG, Gunawardane ND, Cotliar JA. Capecitabine-induced hand-foot syndrome complicated by pseudomonal superinfection resulting in bacterial sepsis and death: case report and review of the literature. *Arch Dermatol*. 2011;147(12):1418-23.
29. Blum JL, Dieras V, Lo Russo PM, Horton J, Rutman O, Buzdar A, et al. Multicenter, Phase II study of capecitabine in taxane-pretreated metastatic breast carcinoma patients. *Cancer*. 2001;92(7):1759-68.
30. Schmoll HJ, Cartwright T, Tabernero J, Nowacki MP, Figer A, Maroun J, et al. Phase III trial of capecitabine plus oxaliplatin as adjuvant therapy for stage III colon cancer: a planned safety analysis in 1,864 patients. *J Clin Oncol*. 2007;25(1):102-9.
31. Sperone P, Ferrero A, Daffara F, Priola A, Zaggia B, Volante M, et al. Gemcitabine plus metronomic 5-fluorouracil or capecitabine as a second-/third-line chemotherapy in advanced adrenocortical carcinoma: a multicenter phase II study. *Endocr Relat Cancer*. 2010;17(2):445-53.



32. Kerbel RS. Inhibition of tumor angiogenesis as a strategy to circumvent acquired resistance to anti-cancer therapeutic agents. *Bioessays*. 1991;13(1):31-6.
33. Castilla MA, Caramelo C, Gazapo RM, Martín O, González-Pacheco FR, Tejedor A, et al. Role of vascular endothelial growth factor (VEGF) in endothelial cell protection against cytotoxic agents. *Life Sci*. 2000;67(9):1003-13.
34. Hurwitz H, Fehrenbacher L, Novotny W, Cartwright T, Hainsworth J, Heim W, et al. Bevacizumab plus irinotecan, fluorouracil, and leucovorin for metastatic colorectal cancer. *N Engl J Med*. 2004;350(23):2335-42.
35. Steinbild S, Arends J, Medinger M, Häring B, Frost A, Dreys J, et al. Metronomic antiangiogenic therapy with capecitabine and celecoxib in advanced tumor patients--results of a phase II study. *Onkologie*. 2007;30(12):629-35.
36. Dellapasqua S, Bertolini F, Bagnardi V, Campagnoli E, Scarano E, Torrisi R, et al. Metronomic cyclophosphamide and capecitabine combined with bevacizumab in advanced breast cancer. *J Clin Oncol*. 2008;26(30):4899-905.
37. Thuss-Patience PC, Kretzschmar A, Bichev D, Deist T, Hinke A, Breithaupt K, et al. Survival advantage for irinotecan versus best supportive care as second-line chemotherapy in gastric cancer--a randomised phase III study of the Arbeitsgemeinschaft Internistische Onkologie (AIO). *Eur J Cancer*. 2011;47(15):2306-14.
38. Kang JH, Lee SI, Lim do H, Park KW, Oh SY, Kwon HC, et al. Salvage chemotherapy for pretreated gastric cancer: a randomized phase III trial comparing chemotherapy plus best supportive care with best supportive care alone. *J Clin Oncol*. 2012;30(13):1513-8.