

Eye Lymphoma: a Case Report

Arabi A^{1*}, Boukerche A², Bey M¹, Bouchama S¹, Charef L¹, Bekadja MA¹

1. Department of hematology and bone marrow transplantation, November 1st 1954 University Hospital, Oran, Algeria.

2. Radiotherapy Department, November 1st 1954 University Hospital, Oran, Algeria.

***Corresponding Author:** Arabi A, Email: abdessamed.arabi@gmail.com

Submitted: 09-07-2012 , Accepted: 17-10-2012

Abstract

Non Hodgkin Lymphomas (NHL) are nodal or extra nodal monoclonal infiltrations by malignant lymphoid cells (B Lymphocytes in 80% of cases), which are distinguished as indolent or aggressive forms.

According to the heterogeneity of lymphoid cells and their ubiquitous anatomical distribution, these disorders can develop in any organ and have very heterogeneous clinical expressions, but they are usually expressed by tumor development in the lymphoid tissue (lymph nodes, Waldeyer ring, spleen, bone marrow and sometimes blood).

We report a patient referred to the department of hematology and bone marrow transplantation with an unusual localization for this type of pathology: eye localized phenotype B lymphoma in its aggressive form, occurring in a 88 years old man.

Clinical remission was obtained by using rituximab, cyclophosphamide, hydroxydaunorubicin, oncovin, prednisone protocol combined with radiotherapy.

Keywords: Non Hodgkin lymphoma, aggressive, eye, remission.

Introduction

Non-Hodgkin Lymphomas (NHL) are a heterogeneous malignancies group developed from B or T lymphoid cells. Their etiology remains unknown.

In France, 10.224 cases were reported for the year 2005 alone, representing a standardized incidence of 12.1/100.00 in men and 8.2/100.00 in women, and the 6th most common cancer ¹. The disease is usually expressed by tumor development in the lymphoid tissue including lymph nodes, Waldeyer ring, spleen and bone marrow. Eye localization is a rare form comprising only 1-2% of all NHLs and 8% of extra nodal NHLs ². We report a case of eye NHL occurring in a 88 year old man.

Report of the case

An 88 year old male patient, farmer by profession, was referred to our service on March 2010 by the maxillofacial surgery service for treatment of Diffuse Large B -Cell Lymphoma (DLBCL) localized at the right orbito-ocular corner.

The patient was well until four months earlier when a small tumor appeared in his right eye with a 1cm diameter which rapidly became voluminous. Many medical consultations were made, and

treatments were prescribed but without result. The patient was then referred to the department of maxillofacial surgery where a biopsy was performed, showing a diffuse large B cell lymphoma (DLBCL) (Figure 1). The pathological examination was completed by an immunohistochemical study showing tumor cells strongly expressing CD20 (Figure 2).

When we received the patient, he had no particular medical or surgical history, apart from cataract surgery 5 years earlier.

Clinical examination findings

Patient reported a weight loss of 10 kg during 8 months. In physical examination a very-large orbito-ocular tumor with disappearance of the right eye, measuring 10x9 cm (Figures 3) was observed. There was absence of localization on the Waldeyer ring. All other clinical examinations were unremarkable. Fever and night sweats were absent.

Paraclinical findings and staging of the disease

The orbital and brain-scans showed a large tumor located in the internal angle of the right orbit measuring 56x76x51mm (Figure 4). Scanning of the

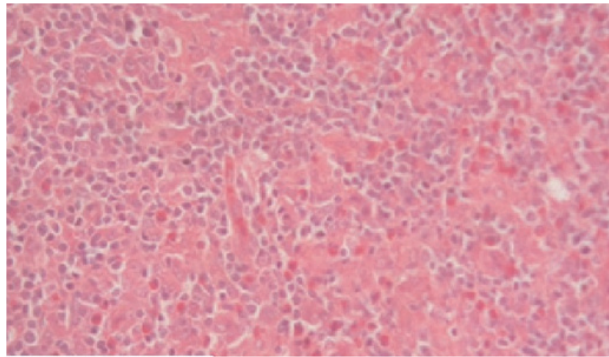


Figure 1: biopsy specimen showing a diffuse large B cell lymphoma.

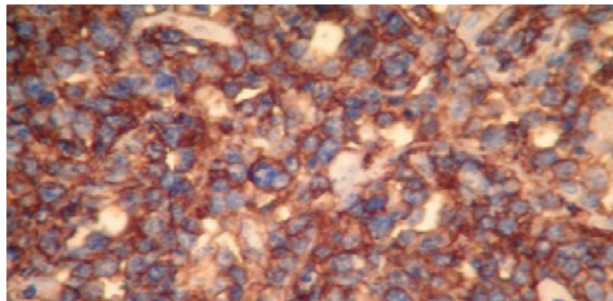


Figure 2: Immunohistochemical study showing tumor cells strongly expressing CD20.

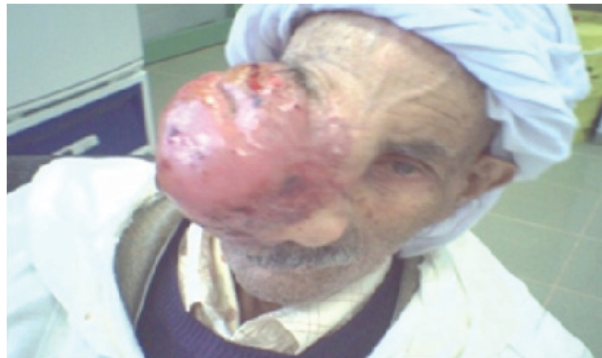

Figure 3: Very-large orbito-ocular tumor with disappearance of the right eye, measuring 10x9 cm.

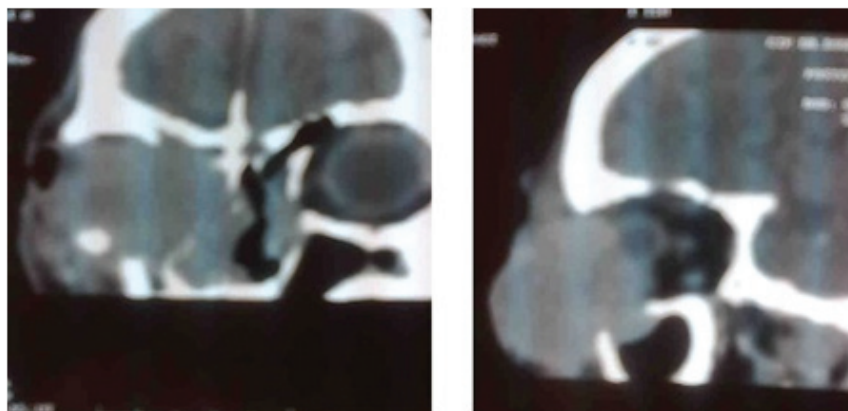


Figure 4: The orbital and brain-scans shows a large tumor located in the internal angle of the right orbit measuring 56x76x51mm.

Table 1: Treatment protocol used to treat the patient (R-CHOP Protocol).

Rituximab: 375mg/m2	IV	d1
Cyclophosphamide: 750mg/m2	IV	d1
Hydroxydaunorubicin: 0mg/m2	IV	d1
Oncovin: 1,4mg/m2	IV	d1
Prednisone: 40mg/m2	PO	d1-5

thorax, abdomen and the pelvis showed absence of lymphadenopathy; and presence of a parahilar infectious sequel in the left lung.

Alkaline-phosphatase was measured as 180 IU / L (demonstrating the absence of hepatic infiltration). The bone marrow biopsy was non-infiltrated. Sedimentation rate was 30mm in the first hour and there was no Leukocytosis (WBC: 4.8 x10⁹ / L). Serum protein electrophoresis showed no inflammation. Other blood tests results before treatment were reported as: Hemoglobin: 12g/dl , Glucose: 0.82 g / L, blood urea: 0.30 g / L, creatinine: 11.3 mg / L, serum calcium: 78mg/ L, phosphate: 28mg / L, serum protein: 67g / L, ASAT: 37 IU / L, ALAT: 30 IU / L, total bilirubin: 11.7 mg / L, serology test for hepatitis B and C: negative, serology HIV test: negative, direct Coombs test: negative, blood group: O Rh+, prothrombin time: 99%, activated partial thromboplastin time: 25sec (control: 22sec), fibrinogen: 3g /L, LDH level (287 IU / L).

In echocardiography there was absence of pulmonary arterial hypertension and the ejection fraction (EF) was 72%.

Following these assessments the patient was classified as stage IEB (Ann Arbor classification) with an intermediate risk (2 factors of poor prognosis according to the IPI).

Treatment method

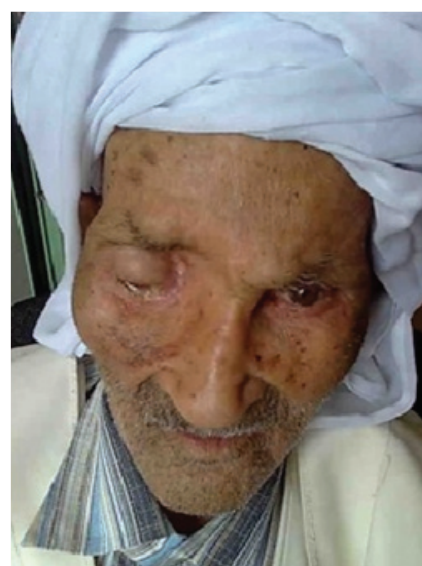According to our protocol, the patient received rituximab, cyclophosphamide, hydroxydaunorubicin, oncovin, and prednisone (R-CHOP) protocol (Table 1). A total of six cycles were administered. Cycle number 1 was administered on 24/3/2010, and cycle number six on 7/7/2010. This Chemotherapy was followed by radiotherapy of 36 Gy, and he was in clinical complete remission

(Figure 5). Control scan (Figure 6) showed a persistent osteolysis involving the maxillary sinus, the orbital part, the massive anterior ethmoid, the naso-lachrymal canal and deformed nasal bone deflected to the left; there is also a heterogeneous tissue thickening including lachrymal infiltration.

Discussion

DLBCL represents 25-35% of all NHLs and 80% of the aggressive lymphomas ³. It is essentially an adults' disease. The cell responsible for DLBCL is a centroblast which varies depending on the type of lymphoma pathology: it may be immunoblast, anaplastic large B cell, large clear B-cell, or intravascular large B-cell ⁴.

The transformation of normal centroblasts to tumoral centroblasts is associated with cytogenetic abnormalities involving the q32 region and the


Figure 5: Clinical remission after treatment.

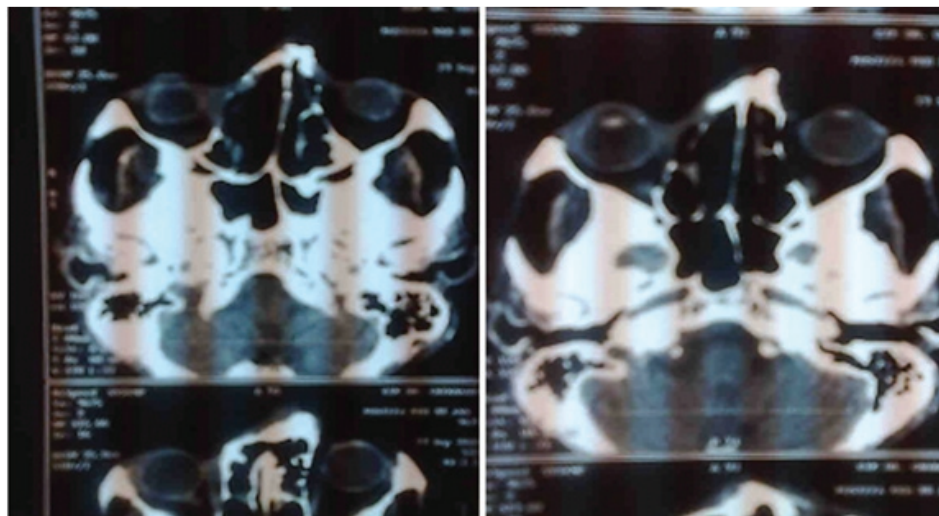


Figure 5: Control scan showing a persistent osteolysis involving the maxillary sinus, the orbital part, the massive anterior ethmoid, the naso-lachrymal canal and deformed nasal bone deflected to the left; there is also a heterogeneous tissue thickening including lachrymal infiltration.

oncogene bcl-6.

The incidence of eye localization is important with an annual increase of 6.3%⁵. Lymphomas are the most common cancers of the eye and account for 55% of all cases in the Florida cancer registry⁶. The eye localizations are most frequently indolent forms (like MALT lymphoma) of the periorbital soft tissue⁷; the evolution is progressive, disappearing completely after simple radiotherapy⁸. In only 8% of cases, it is the aggressive form like diffuse large cell lymphomas⁹ and bone lesions are frequent in this situation¹⁰.

Recently, a direct relationship between infection with *Chlamydia psittaci* (Cp) and the occurrence of ocular NHL has been demonstrated among Italian patients¹¹. Among Italian patients anti lipopolysaccharide Cp were found in 80% of cases¹¹, but this relationship has not been demonstrated in southern Florida¹².

There is no optimal treatment for this type of NHL. Some authors suggest antibiotic treatment against *Chlamydia*² with has shown varying results. In our patient, the lymphoma was aggressive; and we opted to treat the patient with R-CHOP, knowing that at his age, it was risky to give a protocol containing anthracyclines.

Apart from the fact that this is an unusual location, this case report demonstrates that lymphomas are becoming increasingly a disease of interest to many medical and surgical specialists

including hematologists, gastroenterologists, oto-rhino-laryngologists, pediatricians, surgeons, radiotherapists, ophthalmologists, and pathologists.

Conclusion

With the aging of increasingly large populations lymphomas are becoming more common, so it is necessary to be familiar with rare presentations of the disease. Therapeutic methods should be evaluated regularly to cure the patients more successfully at the lowest cost and with the minimum possible harm.

References

- Alexander DD, Mink PJ, Adami HO, Chang ET, Cole P, Mandel JS, Trichopoulos D. The non-Hodgkin lymphomas: a review of the epidemiologic literature. *Int J Cancer*. 2007;120 Suppl 12:1-39.
- Stefanovic A, Lossos IS. Extranodal marginal zone lymphoma of the ocular adnexa. *Blood*. 2009;114(3):501-10.
- Alizadeh AA, Eisen MB, Davis RE, Ma C, Lossos IS, Rosenwald A, et al. Distinct types of diffuse large B-cell lymphoma identified by gene expression profiling. *Nature*. 2000;403(6769):503-11.
- Jaffe ES, Harris NL, Stein H, Vardiman JW. Pathology and Genetics of Tumours of Haematopoietic and Lymphoid Tissues (World Health Organization Classification of Tumours), International Agency for

- Research on Cancer, Lyon, 2001.
5. Moslehi R, Devesa SS, Schairer C, Fraumeni JF Jr. Rapidly increasing incidence of ocular non-hodgkin lymphoma. *J Natl Cancer Inst.* 2006;98(13):936-9.
6. Margo CE, Mulla ZD. Malignant tumors of the orbit. Analysis of the Florida Cancer Registry. *Ophthalmology.* 1998;105(1):185-90.
7. Connors JM. Problems in lymphoma management: special sites of presentation. *Oncology (Williston Park).* 1998;12(2):185-91.
8. Esik O, Ikeda H, Mukai K, Kaneko A. A retrospective analysis of different modalities for treatment of primary orbital non-Hodgkin's lymphomas. *Radiother Oncol.* 1996;38(1):13-8.
9. Fung CY, Tarbell NJ, Lucarelli MJ, Goldberg SI, Linggood RM, Harris NL, et al. Ocular adnexal lymphoma: clinical behavior of distinct World Health Organization classification subtypes. *Int J Radiat Oncol Biol Phys.* 2003;57(5):1382-91.
10. Clayton F, Butler JJ, Ayala AG, Ro JY, Zornoza J. Non-Hodgkin's lymphoma in bone. Pathologic and radiologic features with clinical correlates. *Cancer.* 1987;60(10):2494-501.
11. Ferreri AJ, Guidoboni M, Ponzoni M, De Conciliis C, Dell'Oro S, et al. Evidence for an association between *Chlamydia psittaci* and ocular adnexal lymphomas. *J Natl Cancer Inst.* 2004;96(8):586-94.
12. Rosado MF, Byrne GE Jr, Ding F, Fields KA, Ruiz P, Dubovy SR, et al. Ocular adnexal lymphoma: a clinicopathologic study of a large cohort of patients with no evidence for an association with *Chlamydia psittaci*. *Blood.* 2006;107(2):467-72.