



## LETTER TO EDITOR

### A case of CML-like Disease with t(8;22)(q24;q11)

Marjan Yaghmaie<sup>1</sup>, Nasim Valizadeh<sup>1,2\*</sup>

<sup>1</sup>Hematology-Oncology and Stem Cell Transplantation Research Center, Tehran University of Medical Sciences, Tehran, Iran

<sup>2</sup>Iran University of Medical Sciences, Tehran, Iran

#### ARTICLE INFO

##### Article History:

Received: 12.06.2017

Accepted: 01.08.2017

##### \*Corresponding author:

Nasim Valizadeh

Hematology-Oncology and Stem Cell Transplantation Research Center, Tehran University of Medical Sciences, Tehran, Iran

Tel: +98 9125474755

Email: [nsedaha0@gmail.com](mailto:nsedaha0@gmail.com)

Please cite this article as: Yaghmaie M, Valizadeh N. A case of CML-like Disease with t(8;22)(q24;q11). IJBC 2017; 9(3): 97-98.

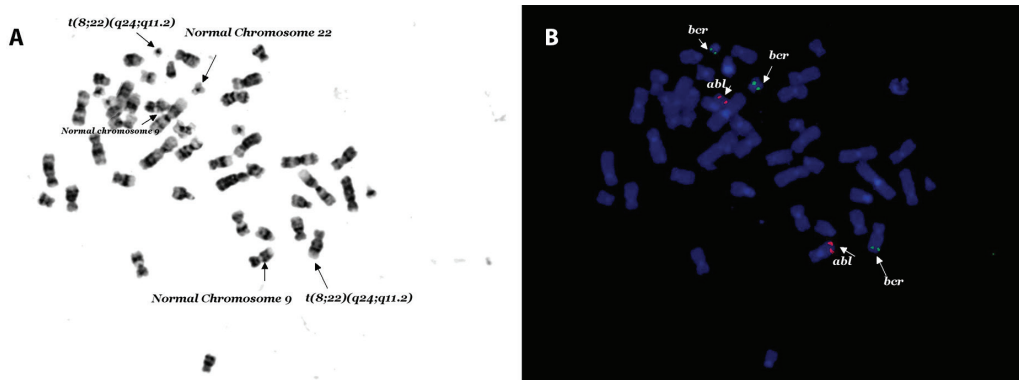
#### Dear Editor

Chronic myelogenous leukemia (CML) is characterized in 85-90% of cases by the presence of the Philadelphia (Ph) chromosome and *BCR-ABL* fusion gene.<sup>1</sup> A further 5-10% of cases have other translocations, most commonly complex variants that involve one or more chromosomal regions in addition to bands 9q34 and 22q11, but also simple variants that typically involve 22q11 and a chromosome other than 9. There are a few reports regarding observation of t(8;22) in patients with CML-like disease.<sup>2-6</sup>

We report a case of CML-like disease with t(8;22) who achieved hematological remission with hydroxyurea and Imatinib. A 27-year-old Iranian male presented with fatigue and malaise. Physical examination revealed bilateral axillary lymphadenopathy and

huge splenomegaly. Peripheral blood smear showed hyperleukocytosis with shift to the left, basophilia, and eosinophilia. Bone marrow aspiration and biopsy was in accordance with CML in chronic phase. Cytogenetic study revealed t(8; 22)(q24; q11) in all 20 metaphases analyzed. The *BCR-ABL* fusion was positive which was proved to be falsely positive due to *BCR* gene disruption. (Figure 1A).

Bone marrow FISH study using D-FISH probes were negative for the *BCR-ABL* fusion in 200 interphase cells analyzed for this patient (Figure 1B). By D-FISH, the metaphases showed red (*ABL*) signals on both copies of chromosome 9; one large green (*BCR*) signal on the normal chromosome 22 with smaller green signals on the der (22) and on the der (8). These findings were consistent with the known karyotype and suggested



**Figure 1:** A) 46XY, t(8;22)(q24;q11.2)[20], B) nuclear Fish(ABL×2),(BCR×3)

that the chromosome 22 breakpoint must be close to, or within, the BCR. He initially received Imatinib mesylate and hydroxyurea which was followed by imatinib alone. He achieved complete hematological remission.

Although t(9;22) is diagnostic for CML, t(8;22) is another known cytogenetic abnormality in patients with CML-like disease. t(8;22) might have been classified cytogenetically as merely a simple variant of the t(9;22). A translocation between the long arms of chromosomes 8 and 22 described both in B-cell acute lymphoblastic leukemia (ALL) and non-Hodgkin lymphomas (NHL), especially in Burkitt lymphoma has been also reported with BCR breakpoint in 22q11.2 in CML-like disease. CML-like disease with t(8;22) can benefit from TKI therapy.

**Conflict of Interest:** None declared.

### References

1. Wong S, Witte ON. The BCR-ABL story: bench to bedside and back. *Annu Rev Immunol.* 2004; 22:247-306. doi: 10.1146/annurev.immunol.22.012703.104753. PubMed PMID: 15032571.
2. Demiroglu A, Steer EJ, Heath C, Taylor K, Bentley M, Allen SL, et al. The t(8;22) in chronic myeloid leukemia fuses BCR to FGFR1: transforming activity and specific inhibition of FGFR1 fusion proteins. *Blood.* 2001; 98(13):3778-83. PubMed PMID: 11739186.
3. Pini M, Gottardi E, Scaravaglio P, Giugliano E, Libener R, Baraldi A, et al. A fourth case of BCR-FGFR1 positive CML-like disease with t(8;22) translocation showing an extensive deletion on the derivative chromosome 8p. *Hematol J.* 2002; 3(6):315-6. doi: 10.1038/sj.thj.6200201. PubMed PMID: 12522455.
4. Fioretos T, Panagopoulos I, Lassen C, Swedin A, Billström R, Isaksson M, et al. Fusion of the BCR and the fibroblast growth factor receptor-1 (FGFR1) genes as a result of t(8;22)(p11;q11) in a myeloproliferative disorder: The first fusion gene involving BCR but not ABL. *Genes Chromosomes Cancer.* 2001; 32(4):302-10. PubMed PMID:11746971.
5. Qin YW, Yang YN, Bai P, Wang C. Chronic myelogenous leukemia-like hematological malignancy with t(8;22) in a 26-year-old pregnant woman: A case report. *Oncol Lett.* 2016; 11(6):4131-3. doi: 10.3892/ol.2016.4505. PubMed PMID: 27313753. PubMed Central PMCID: PMC4888210.
6. Richebourg S, Theisen O, Plantier I, Parry A, Soenen-Cornu V, Lepelley P, et al. Chronic myeloproliferative disorder with t(8;22)(p11;q11) can mime clonal cytogenetic evolution of authentic chronic myelogenous leukemia. *Genes Chromosomes Cancer.* 2008; 47(10): 915-8. doi: 10.1002/gcc.20588.